

Topographico-anatomic peculiarities of the external carotid artery in the perinatal period

*¹Oleksandr Slobodian, MD, PhD, Professor; ²Lalita Gerasym, MD, Assistant Professor

¹Department of Anatomy, Topographic Anatomy and Operative Surgery

²Department of Surgical Dentistry and Maxillofacial Surgery
Bukovinian State Medical University, Chernivtsi, Ukraine

*Corresponding author: slobodjanaleksandr@ukr.net

Manuscript received April 01, 2019; revised manuscript June 03, 2019

Abstract

Background: the importance of the given issue is in clarification of ontogenetic transformations of the external carotid artery during the perinatal and early neonatal periods, which is essential from the view of surgical treatment of congenital pathology of the cervical vessels in fetuses, neonates and infants. **Material and methods:** the study was performed on 50 specimens of dead fetuses (from 4 to 10 months) and 9 neonates (5 isolated complexes of organs in particular) without external signs of anatomical defects or deviations, and without visible macroscopic anomalies from the normal structure of the cardio-vascular system. Adequate anatomical methods of investigation were applied during examination: macropreparation, injection of the blood vessels, making topographic-anatomical sections, morphometry, and statistical analysis.

Results: the cervical part of the external carotid artery during the perinatal period is a distance from its origin to the point of crossing with the stylohyoid muscle. The major branches of the cervical part of the external carotid artery are: the superior thyroid one, hyoid, facial, occipital and posterior auricular arteries. The two types are peculiar for the branching of the external carotid artery: main (77%) and scattered (23%). Variability of emerging branches from the external carotid artery is found in 3.5% of cases.

Conclusions: determination of typical and variant topography of the external carotid artery and its branches will promote implementation of new methods to perform radical and reconstructive-restorative surgery on the cervical vessels.

Key words: external carotid artery, topography, fetus, neonate, human subject.

Introduction

Numerous defects found in clinical practice in most cases can be explained on the basis of finding the origin and relations of the organs and structures which in the course of time acquire the shapes peculiar for them, investigating their unusual topography and understanding appropriate embryonic phenomena comprehensively [1, 2, 3]. Development of new directions in operative surgery, elaboration of new surgical methods, always require their anatomical substantiation [4, 5, 6, 7]. Congenital vascular defects are third among other diseases including hypoxic lesions and birth injuries. In 83% of cases ischemic strokes in children occur due to vascular defects. Approximately 70% of infants develop convolution of the carotid arteries associated with coarctation of the aorta (CoA), developmental variants of Willis' circle, aortic aneurism, underdevelopment of the anterior cerebral artery, high degree of bifurcation of the common carotid artery [8, 9, 10, 11]. A general frequency of defects of the carotid arteries depending on the results of angiographic and pathologic anatomical examinations ranges within 10 to 40% [12, 13, 14]. Nowadays pathologic convolution of the carotid arteries is considered to be congenital pathology occurring due to embryogenesis disorders of the carotid arteries. According to the data of autopathies this pathology is found in 14% of cases, and according to the findings of Doppler scanning C-like convolution of the carotid arteries is found in 33.6%, and S-like – in 66.4% of cases [15, 16, 17].

Priority of the study consists of finding ontogenetic transformations of the external carotid artery during the perinatal period of human ontogenesis which is an important issue from the view

of surgical treatment of congenital pathology of the cervical vessels in fetuses, neonates and infants.

The objective is to determine topographic-anatomical peculiarities of the external carotid artery and its branches during the fetal and early neonatal periods of human ontogenesis.

Material and methods

The study was performed on 50 specimens of dead fetuses (from 4 to 10 months) and 9 neonates (5 isolated complexes of organs in particular) without external signs of anatomical defects or deviations, and without visible macroscopic anomalies from the normal structure of the cardio-vascular system. Adequate anatomical methods of investigation were applied during examination: macropreparation, injection of the blood vessels, making topographic-anatomical sections, morphometry, and statistical analysis. Injection of the blood vessels, and the cervical arteries in particular, was performed after catheterization of the descending part of the aorta. The catheter was directed to the cranium, the mixture of red-lead paint for injection was introduced. After fixation of the specimens of dead fetuses and neonates macropreparation of the external carotid artery and its branches was performed by means of forceps and scissors.

The study was conducted according to the major requirements of the Declaration of Helsinki on ethical principles to provide scientific-medical research involving human subjects elaborated by the World Medical Association (1964-2000) and the Order of the Ministry of Health of Ukraine № 690 dated 23.09.2009. It is a fragment of a complex planned initiative scientific-research work

of M. G. Turkevych Department of Human Anatomy and Department of Anatomy, Topographic Anatomy and Operative Surgery of Bukovinian State Medical University: "Peculiarities of Morphogenesis and Topography of the Organs and Systems During Prenatal and Postnatal Periods of Ontogenesis" (State Registration № 0115U002769).

Results and discussion

Within the borders of the carotid triangle the common carotid artery is found to be dichotomically divided into the internal and external carotid arteries. The external carotid artery extends in the cranial direction joining the muscles of the supra- and subhyoid groups of the neck. In our opinion, the cervical part of the external carotid artery is determined from the point of its origin (division of the common carotid artery into the final branches) to the point of the artery joining the stylohyoid muscle. During the perinatal period the major branches emerge from the external carotid artery upwards in the cranial direction: the superior thyroid, hyoid, facial, occipital and posterior auricular ones.

Usually the superior thyroid artery branches from the median surface of the external carotid artery 0.3-0.5 cm higher from the point of bifurcation of the common carotid artery. The superior thyroid artery passes upwards close to the lateral border of the omohyoid muscle, forms an arch, and then changes its direction downwards (fig. 1). It joins the posterior surface of the omohyoid muscle. The superior thyroid artery branches the superior laryngeal artery; it divides dichotomically into the final branches near the superior border of the thyroid gland. These branches participate in blood supply of an appropriate lobe of the thyroid gland.

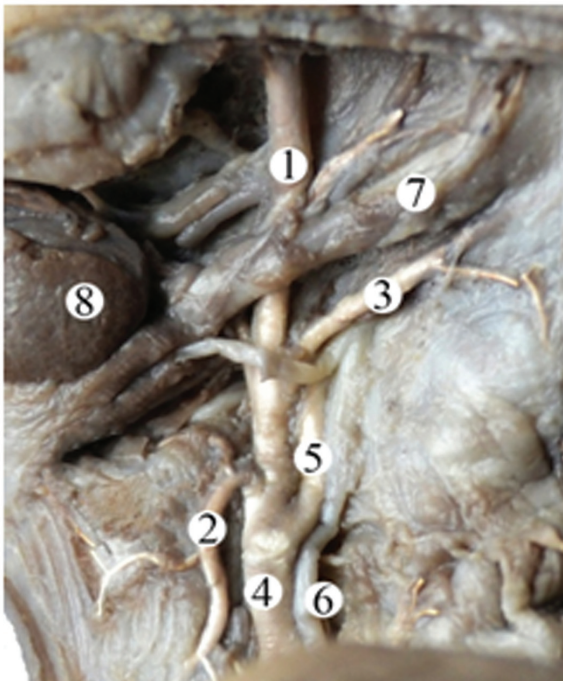


Fig. 1. The anterior part of the neck (from the left) of the fetus, 300.0 mm of the parietal-calcaneal length (the superficial layer of cervical muscles is removed).
 Macrospecimen, magnification 2.1^x: 1 – external carotid artery, 2 – superior thyroid artery, 3 – occipital artery, 4 – common carotid artery, 5 – internal carotid artery, 6 – internal jugular vein, 7 – digastric muscle, 8 – submandibular gland.

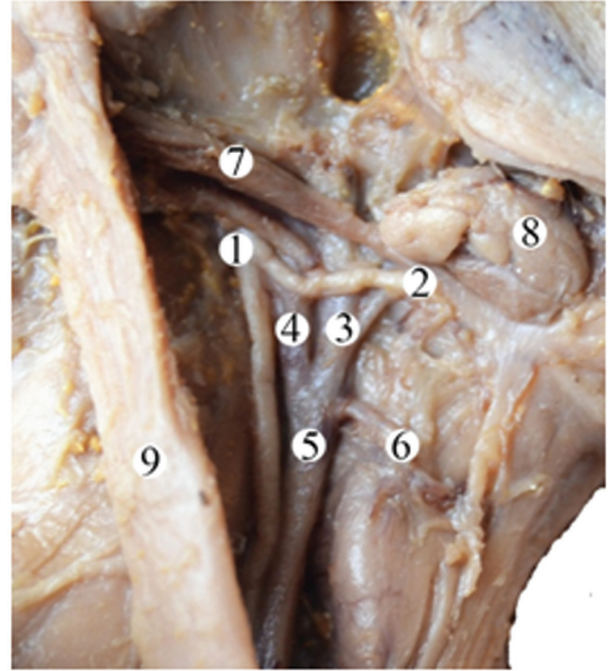


Fig. 2. The anterior part of the neck (from the right) of the fetus, 380.0 mm of the parietal-calcaneal length. Macrospecimen, magnification 1.6^x: 1 – vagus, 2 – superior laryngeal nerve, 3 – external carotid artery, 4 – internal carotid artery, 5 – common carotid artery, 6 – superior thyroid artery, 7 – digastric muscle, 8 – submandibular gland, 9 – sternocleidomastoid muscle.

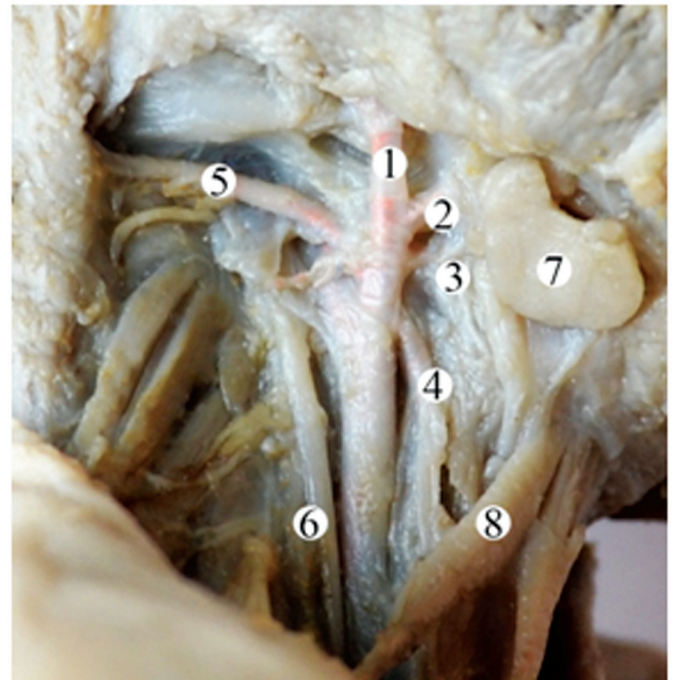


Fig 3. The anterior part of the neck (from the right) of the fetus, 210.0 mm of the parietal-calcaneal length (subcutaneous and sternocleidomastoid muscles are removed).
 Macrospecimen, magnification 1.3^x: 1 – external carotid artery, 2 – facial artery, 3 – hyoid artery, 4 – superior thyroid artery, 5 – occipital artery, 6 – internal jugular vein, 7 – submandibular gland, 8 – omohyoid muscle.

Only in two cases (3.5%) during the perinatal period the superior thyroid artery emerges from the median surface of the common carotid artery lower from the point of its bifurcation (fig. 2). In these cases the superior thyroid artery extends downwards forming branches in the same direction and dichotomically divides into the final branches.

The hyoid artery emerges from the median surface of the external carotid artery. Usually in 75% of cases its direction is upward, in the rest of observations (25%) it extends horizontally. The hyoid artery is located posteriorly from the posterior ventricle of the digastric muscle approaching the inferior border of the submandibular gland. Further topography of the hyoid artery depends on the syntopic effect of the submandibular gland, and its sizes in the perinatal period in particular.

Higher from the hyoid artery the occipital artery emerges from the lateral surface of the external carotid artery. The direction of the occipital artery is dorsoascending. It extends along the inferior border of the posterior ventricle of the digastric muscle (fig. 1).

The facial artery emerges from the external carotid artery practically on the same level of the occipital artery, but from the opposite surface, that is from the median one. The facial artery usually extends in the ventrodorsal direction, and close to the superior border of the posterior ventricle of the digastric muscle it joins the superior border of the submandibular gland. The facial artery crosses the inferior border of the mandible near the anterior masticatory muscle and passes to the mandibular-facial area.

Cranially from the point where the occipital artery emerges from the external carotid artery the posterior auricular artery originates. It has dorsocranial direction and extends between the posterior ventricle of the digastric muscle and stylohyoid muscle practically parallel to the occipital artery.

Beginning from the third trimester of the perinatal development the median group of branches of the external carotid artery is found in 12% of cases, namely the branches of the ascending pharyngeal artery penetrating the muscles and participating in blood supply of the pharynx.

The presented topography of the branching of the external carotid artery is found in 77% of cases. This type of branching of the external carotid artery is the main one. Only in 23% of observations a scattered type of branching of the external carotid artery is found. The hyoid, facial, occipital and posterior auricular arteries emerge from the external carotid artery practically on the same level, that is in a fan-shaped manner (fig. 3). At the same time, the superior thyroid artery possesses a typical feature of emerging from the external carotid artery. A scattered type of branching of the external carotid artery in the majority of observations (70%) is peculiar for the early fetuses (4-5-months). It is usually found in the right side.

Conclusions

1. The cervical part of the external carotid artery during the perinatal period is a distance from its origin to the point of crossing with the stylohyoid muscle.
2. The major branches of the cervical part of the external carotid artery are: the superior thyroid one, hyoid, facial, occipital and posterior auricular arteries.
3. The two types are peculiar for the branching of the external carotid artery: main (77%) and scattered (23%).

4. Variability of emerging branches from the external carotid artery is found in 3.5% of cases.

References

1. Akhtemiichuk IuT, Slobodian OM, Hmara TV, et al. Narisi perinatalnoi anatomii [Essays on perinatal anatomy]. Chernivtsi; 2011. 300 p. Ukrainian.
2. Akhtemiichuk IuT. Aktual'nist' naukovikh doslidzhen' u galuzi perinatal'noi anatomii [Actuality of scientific research in the field of perinatal anatomy]. Neonatologiya, Khirurgia ta Perinatal'na Meditsina [Neonatal Surg Perinatal Med]. 2012;2(1):15-21. Ukrainian.
3. Menshawi K, Mohr JP, Gutierrez J. A functional perspective on the embryology and anatomy of the cerebral blood supply. J Stroke. 2015;17(2):144-58. doi: 10.5853/jos.2015.17.2.144.
4. Benouaich V, Porterie J, Bouali O, et al. Anatomical basis of the risk of injury to the right laryngeal recurrent nerve during thoracic surgery. Surg Radiol Anat. 2012;34(6):509-12.
5. Fluss J, Garcia-Tarodo S, Granier M, Villega F, Ferey S, Husson B, et al. Perinatal arterial ischemic stroke related to carotid artery occlusion. Eur J Paediatr Neurol. 2016;20(4):639-48. doi: 10.1016/j.ejpn.2016.03.003.
6. Popović R, Radovinović-Tasić S, Rusović S, Lepić T, Ilić R, Raičević R, et al. Urgent carotid stenting before cardiac surgery in a young male patient with acute ischemic stroke caused by aortic and carotid dissection. Vojnosanit Pregl. 2016;73(7):674-8.
7. Katory Y, Kawase T, Ho Cho K, et al. Suprahyoid neck fascial configuration, especially in the posterior compartment of the parapharyngeal space: a histological study using late-stage human fetuses. Clin Anat. 2013;26(2):204-12.
8. Agrawal R, Agrawal SK. Dangerous anatomic variation of internal carotid artery – a rare case report. Int J Anat Var (IJAV). 2011;4:174-6.
9. Beigelman R, Izaguirre A, Robles M, Grana D, Ambrosio G, Milei J. Kinking of carotid arteries is not a mechanism of cerebral ischemia: a functional evaluation by Doppler echography. Int Angiol. 2011;30:342-8.
10. Dadashov SA, Lavrent'ev AV, Frolov KB, Vinogradov OA, Dziundzia AN, Ul'ianov ND. Khirurgicheskoe lechenie patologicheskoi izvitosti vnutrennei sonnoi arterii [Surgical treatment of the pathological tortuosity of internal carotid artery]. Angiologiya i Sosudistaia Khirurgiya [Angiol Vasc Surg]. 2012;18(3):116-21. Russian.
11. Pfeiffer J, Ridder GJ. A clinical classification system for aberrant internal carotid arteries. Laryngoscope. 2008;118(11):1931-36.
12. Avazashvili ID, Skorokhoda II, Tysh II. Otsenka effektivnosti karotidnogo stentirovaniia pri stenoziruuiushchikh porazheniakh sonnykh arterii [Assessment of the efficiency of carotid stenting during penying damages of the carotid arteries]. Zhurnal Natsional'noi Akademii Medichnikh Nauk Ukraini [J Natl Acad Med Sci Ukr]. 2013;19(Suppl):15. Russian.
13. Gavrilenko AV, Abramian AV, Kuklin AV, Ofosu D. Patologicheskaiia izvitost' vnutrennei sonnoi arterii: klinika, diagnostika i khirurgicheskoe lechenie [Internal carotid artery kinking: the clinic, diagnosis and surgical treatment]. Kardiologiya i Serdechno-sosudistaia khirurgiya [Cardiol Cardiovasc Surg]. 2016;9(1):29-33. doi: 10.17116/kardio20169129-33. Russian.
14. Gavrilenko AV, Abramyan AV, Kuklin AV. Sravnitel'nyi analiz rezul'tatov khirurgicheskogo i konservativnogo lecheniia bol'nykh s patologicheskoi izvitost'iu sonnykh arterii [Comparative analysis of the results of the surgical and conservative treatment of patients with pathological tortuosity of carotid arteries]. Angiologiya i Sosudistaia Khirurgiya [Angiol Vasc Surg]. 2012;18(4):93-9. Russian.
15. Abramova MF, Shurupuva NS. Ul'trazvukovoe dupleksnoe skanirovanie i klinicheskie osobenosti ekstrakranial'nykh anomalii vnutrennykh sonnykh arterii u detei [Ultrasonic duplex scanning and clinical peculiarities of the extracranial abnormalities of the internal carotid arteries in children]. Pediatr Farmakol. 2009;6(3):80-3. Russian.
16. Kaplan ML, Bontsevich DN. Techenie sosudistoi mozgovoi nedostatochnosti pri patologicheskoi izvitosti sonnykh arterii, ee rol' pri opredelenii pokazanii k operativnomu lecheniiu [The course of cerebral vascular insufficiency in pathological tortuosity of carotid arteries, its role in indications for surgical treatment]. Problemy zdorov'ia i ekologii [Probl Health Ecol] (Gomel). 2014;3:95-100. Russian.
17. Kathuria S, Gregg L, Chen J, Gandhi D. Normal cerebral arterial development and variations. Semin Ultrasound CT MR. 2011;32:242-51. doi: 10.1053/j.sult.2011.02.002.