

TWO-PHASE TREATMENT OF CLASS II MALOCCLUSION

Author(s), affiliation Untila Cătălina , Calfa Sabina, Ciumeico Lucia, Orthodontic Department, Nicolae Testemitanu State University of Medicine and Pharmacy of the Republic of Moldova

Introduction: Mixed dentition treatment goals often focus on skeletal rather than dental correction.

Recognized as a difficult anomaly to treat, class II Angle malocclusions require early diagnosis and treatment, the latter often being staged. A goal of “early” orthodontic treatment is to correct existing or developing skeletal, dentoalveolar, and muscular imbalances to improve the orofacial environment before the permanent teeth eruption is complete.

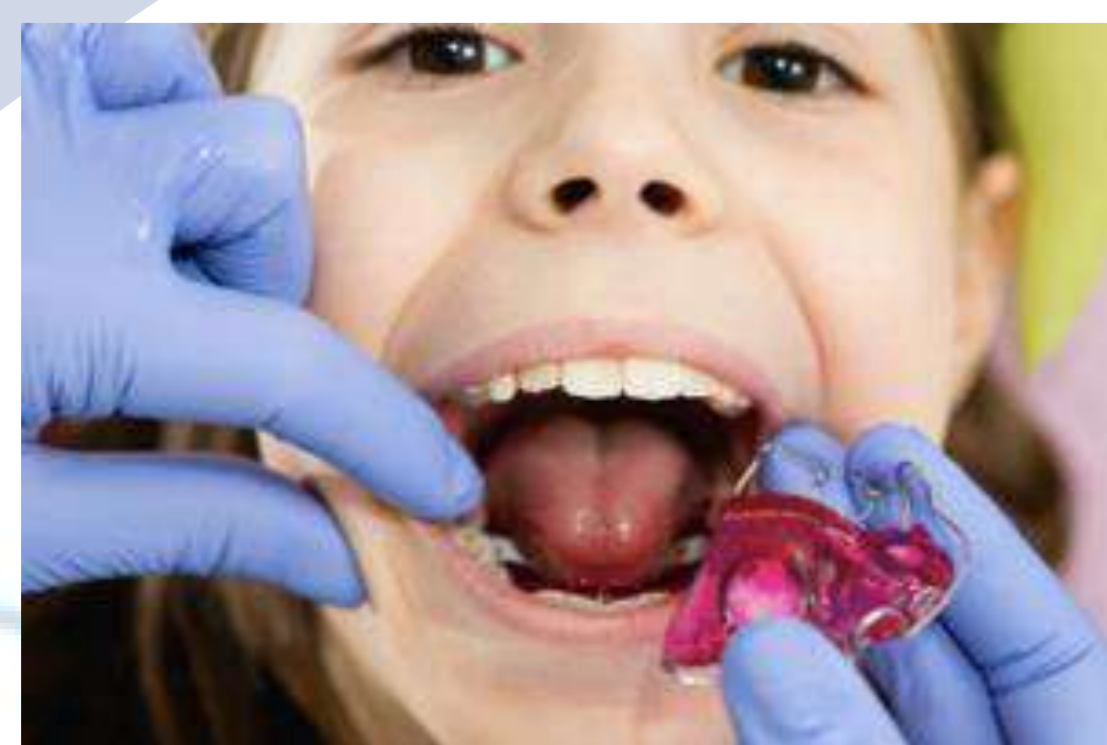Early intervention may reduce the overall need for complex orthodontic treatment like permanent tooth extraction or orthognathic surgery.

Keywords: Class II malocclusion, mobile orthodontic appliance, adezive orthodontic appliance, early treatment.

Purpose: Evaluation of two-stage treatment of patients with Cass II Angle abnormalities

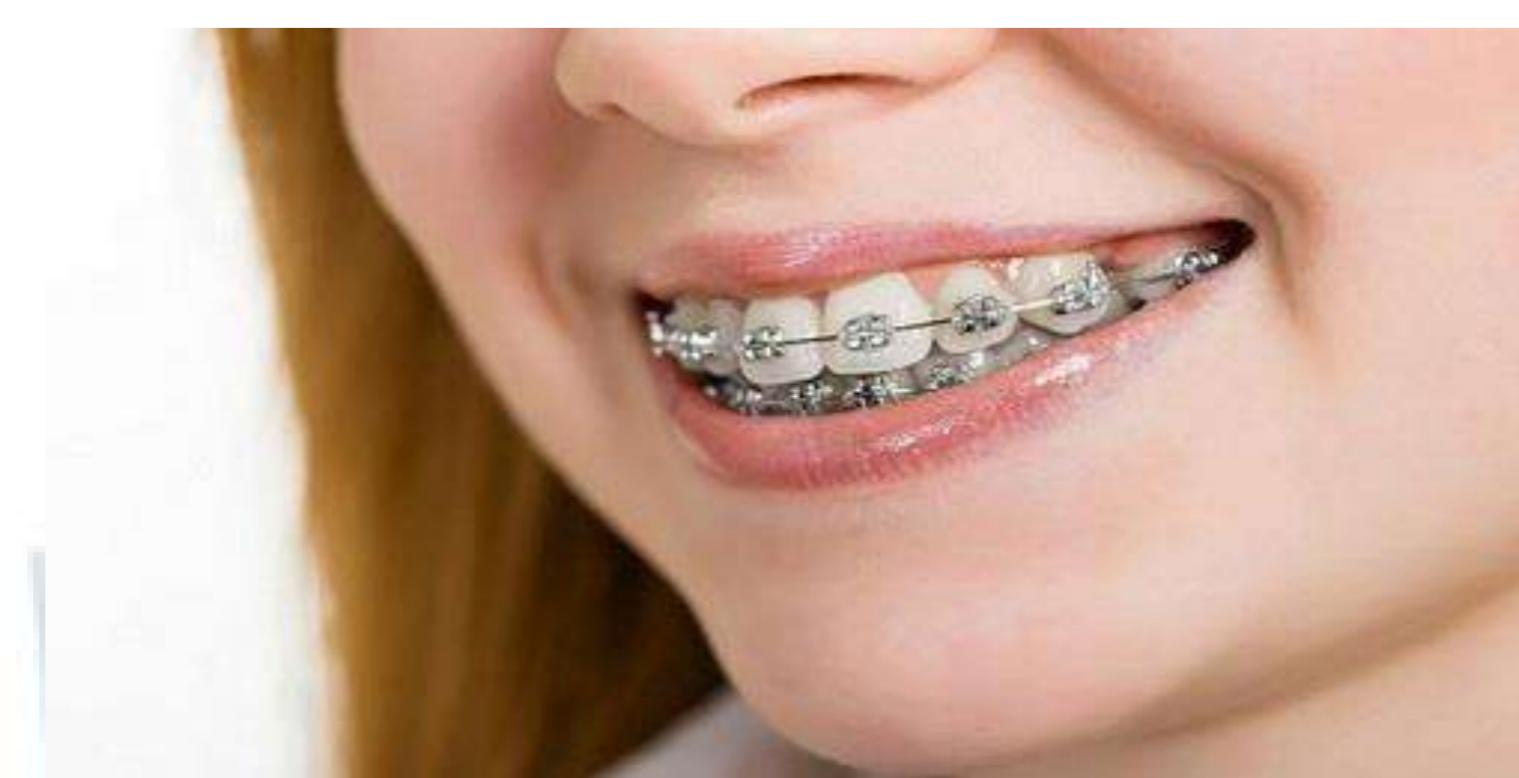Phase 1 treatment.

- Mixed dentition.
- Permanent and baby teeth.
- 6-15 months.
- Correction of crowding, disfunctional habits, airway, narrow jaws and skeletal problems



Pase 2 treatment.

- Full Permanent dentition.
- 6-18 months.
- Final correction of tooth position, functional and skeletal problems



Material and methods: The study is based on data collected from a group of 50 patients with a diagnosis of malocclusion class II / 1 Angle and class II / 2 Angle, aged 7-18 years. They underwent clinical and paraclinical examinations pretreatment and after each stage, the changes and the effectiveness of the applied treatment were evaluated. The applied methods were mobile / mobilizable devices and fixed technique.

Results: Following the analysis of the preliminary and final results of the treatment in two stages from the group of 50 patients, the change of the dento-facial parameters was observed. In the case of patients with maxillary compression, the use of mobilizable devices had an efficiency of about 30% (fig.1), and fixed expansion devices an efficiency of 80%(fig.2). In patients with medium and advanced severity overbite, the use of mobile devices showed an efficiency of 40% of the desired result. The second stage of treatment resulted in achieving the best results against the background of those obtained in the first stage.

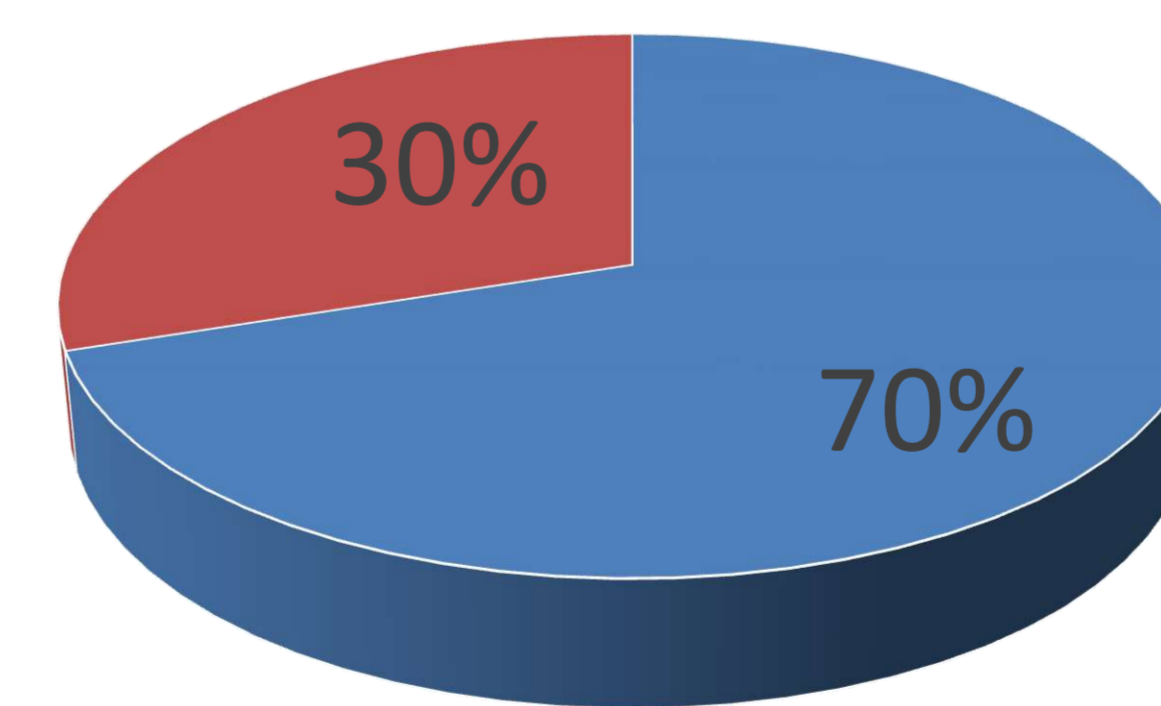


Fig.1. Comparative results of expansion treatment with mobilizable orthodontic devices

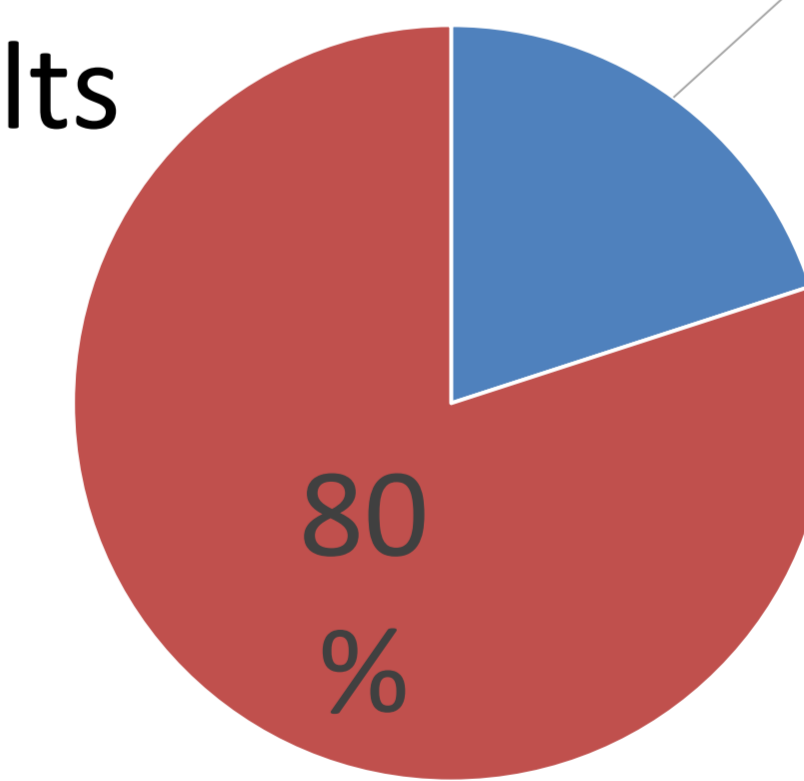


Fig. 2. Comparative results of expansion treatment with fixed appliances.

Conclusions: Evaluation of two-stage treatment of patients with Angle class II abnormalities demonstrated efficacy at each stage. 2. The application of early orthodontic treatment of mobile or mobilizable appliances reflects an increased success rate and a minor risk of recurrence. Proper diagnosis and treatment planning can produce the most satisfying results during the mixed dentition stage.