

## The orthodontic miniscrew implants in tooth migration

<sup>1</sup>Elinor Paz, MD; <sup>1</sup>Angela Babuci, MD, Assistant Professor; <sup>2</sup>Elena Stepco, MD, PhD, Associate Professor

<sup>1</sup>Department of Human Anatomy, <sup>2</sup>Department of Pediatric Oral and Maxillofacial Surgery  
Nicolae Testemitsanu State University of Medicine and Pharmacy, Chisinau, the Republic of Moldova

\*Corresponding author: angela.babuci@usmf.md

Manuscript received May 18, 2019; revised manuscript August 29, 2019

### Abstract

**Background:** The bone loss, tooth loss and gingival inflammation are the most common harmful factors that might cause pathologic tooth migration. Taking into consideration that miniscrews implants are used in orthodontic treatment of both pathologic and physiologic tooth migration, we were interested to mark out the advantages and disadvantages of miniscrew usage.

**Conclusions:** Development of implants industry and particularly miniscrew anchorage has been rapidly increased in the recent years, but nevertheless there still are some risk factors of miniscrews use and success of treatment depends a lot on techniques of miniscrew insertion and stability elements. The anchorage control during tooth movement is one of the main factors for ensuring successful orthodontic treatment and the most important keys for achievement of success in clinical orthodontics. The advantages of miniscrews, in comparison with other methods of orthodontic treatment might be resumed to: lower costs, easy placement, no need for patient cooperation, high quality and efficiency of treatment. Among the most undesirable side effects of miniscrews use can be marked out the screw fracture, screw-root proximity, damages of soft and hard tissues, displacement under orthodontic loading, etc.

**Key words:** miniscrew, pathologic tooth migration, anchorage devices, tooth movement.

### Introduction

The etiology of tooth migration includes a wide range of harmful factors such as: periodontal and gingival inflammation diseases, dystrophy of the attaching and supporting structures of the teeth, bone loss and loss of the approximating, or opposing teeth, lingual interposition, parafunctions, age and oral habits [1], as well it might be caused by movement of teeth during eruption, or out of their normal position in the dental arch.

According to Martinez-Canut et al. [2], among the most common etiological factors that may cause pathologic tooth migration, were bone loss, tooth loss and gingival inflammation that resulted in PTM prevalence in 55.8% of patients.

Two types of tooth migration are distinguished:

- **Physiologic tooth movement** due to tooth eruption, migration or drifting, changes of tooth position during mastication.

Usually the posterior teeth migrate to the mesial direction and anterior teeth migrate to the distal direction.

- **Pathologic tooth movement** occurs in periodontium and gingival diseases, bones loss, tooth loss and loss of periodontal ligament that may result in loss of supporting structures of the tooth.

As a common complication of moderate to severe periodontitis may occur teeth migration and those patients usually, apply for periodontal therapy.

Pursuant to Khorshidi et al. [3] the “pathologic migration was not observed in patients with mild chronic periodontitis”. The same author pointed out that in patients with moderate chronic periodontitis, PTM was marked out in 5.2% of cases, but in patients with severe chronic periodon-

titis the rate of patients with PTM was 51% and in cases of aggressive localized, or generalized periodontitis the PTM was marked out in 50% of patients.

According to Brunsvold [4] “prevalence of PTM among periodontal patients has been reported to range from 30.03 to 55.8%”, with an average of 42.9%.

For example Towfighi et al. [1] in their paper concluded that PTM was one of the most common complaint of patients that addressed do dental clinics.

The rate of pathologic tooth migration according to different authors, periods of time and countries is given in the diagram (fig. 1).

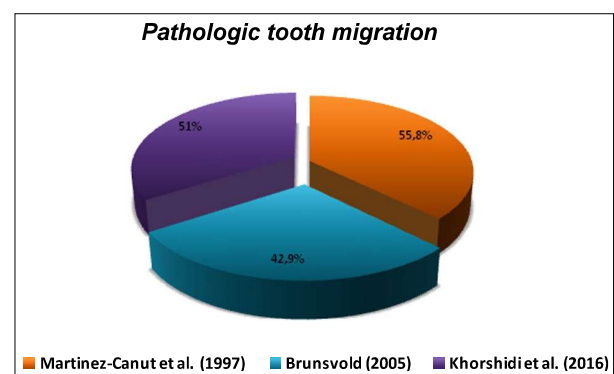


Fig. 1. The rate of pathologic tooth migration according to [2, 3, 4].

### Results and discussion

First publications on osseointegration appeared in 1940 when Bothe, Beaton and Davenport did their researches on

titanium implant in an animal. As a result it was discovered that "titanium has a property to fuse in bone", and they proposed to use it as prosthetic material [5].

Later Leventhal [6] in published papers pointed out that "no reaction to the metal was found" and "in no animal there was any infection, no induration, or discoloration about the site of the screw in the soft tissue".

The history of usage of temporary anchorage devices started its development after significant discovery done by Professor Per-Ingvar Branemark when in the 1950s he proved that bone can integrate with titanium components. After his discovery, Professor Branemark introduced the term «osseointegration», which principles served as foundation for clinical applications of implants.

Per-Ingvar Branemark is considered the «father of modern implantology» and his discovery was really significant for medicine and dentistry. Due to Branemark's discovery an increasing interest in osseointegration of implants in bone was mentioned, and got started the era of using implants for orthodontic anchorage.

Jokstad et al. [7] emphasized in his paper that «the uniqueness of Professor Per-Ingvar Branemark research» was «the discovery of osseointegration phenomenon».

Nowadays, due to the development of implants technology, this method of treatment is widely used. In dentistry, the temporary anchorage devices are used with the aim to produce an orthodontic tooth movement that occurs as a result of a force being placed on a tooth application forces, producing change of a tooth position.

In case of tooth migration, or malocclusion the orthodontic miniscrew implants may serve as an optimal variant of treatment. The "anchorage control during tooth movement is one of the main factors for ensuring successful orthodontic treatment" [8].

Temporary anchorage devices (TADs), or miniscrew implants are small titanium alloy, or stainless steel surgical bone screws, used in orthopedics in order to achieve quicker tooth movement with more efficiency and comfort. TADs are temporarily fixed to bone for the purpose "of enhancing orthodontic anchorage either by supporting the teeth of the reactive unit or by obviating the need for the reactive unit altogether" [9] as well as for controlling the tooth movement during orthodontic treatment, and they are removed when the treatment is completed. TADs are used in addition to braces, or as an alternative to headgear.

Labanauskaite et al. [10] proposed to classify the implants for orthodontic anchorage into three groups.

#### **I. According to shape and size:**

1. Conical (cylindrical) implants
  - a) Miniscrew implants
  - b) Palatal implants
  - c) Prosthodontic implants
2. Mini plate implants
3. Disc implants (onplants)

#### **II. According to implant bone contact:**

1. Osteointegrated
2. Non-osteointegrated

#### **III. According to application:**

1. Used only for orthodontic purposes (orthodontic implants)

2. Used for prosthodontic and orthodontic purposes (prosthodontic implants).

The TADs, according to Singh et al. [9] can be "located transosteally, subperiosteally, or endosteally; and they can be fixed to bone either mechanically (cortically stabilized) or biochemically (osseointegrated)". An important fact mentioned by Singh et al. [9] was that "incorporation of dental implants and TADs into orthodontic treatment made possible *infinite anchorage*, which has been defined in terms of implants as showing no movement (zero anchorage loss) as a consequence of reaction forces».

Creation of space in case of tooth migration by using orthodontics miniscrew implants, known as temporary anchorage devices may be used in patients with PTM.

Due to high biocompatibility of nickel-free wires the «development of new b-titanium alloys and other titanium alloys has rapidly increased» [11].

TADs provide stable anchorage for tooth movements, and excellent treatment results were obtained by using miniscrews for orthodontic anchorage in different types of malocclusion, when it is necessary to perform the midline coordination and changes in the occlusal plane, as well as for intrusion, extrusion, distalization and protraction.

For a successful treatment, first of all there should be done an exhaustive orthodontic diagnosis to select the miniscrews implants of a correct length and diameter, and to take into consideration the distribution of orthodontic forces.

However, there is no common, or single opinion about the length and diameter of miniscrew used in orthodontic therapy. For example, Cheng et al. [12] emphasized that in their study «the length of miniscrews had no effect on implant survival», because «the short screws used for the fixation of miniplate implants did not jeopardize their performance» and «longer implants did not necessarily result in greater bone support».

For modern man the physical appearance, sometimes plays a decisive role in carrier and even life quality, that is why people of 21<sup>st</sup> century are very much concerned about their physiognomy. The malocclusion and other problems of the dental apparatus may cause discomfort in psychically liable people.

The temporary anchorage devices successfully are used in orthodontics therapy, and according to Song et al. [13] "in comparison with the traditional orthodontics, miniscrew implant anchorage can increase the success rate and efficacy of oral orthodontics, with shorter complete closing time of extraction space, lower incidence rate of the postoperative adverse reactions and promising stability and safety".

The miniscrews "have relatively lower costs and are simple to insert and remove; therefore, they can be easily placed by an orthodontist with minimal tissue invasion", and "obtain their stability mainly from mechanical retention in the bone, so they can be loaded immediately after placement" [8].

**The temporary anchorage devices are used in orthodontics for the following purposes:**

- A. Closure of extraction space by using miniscrew implants;
- B. Retraction of incisors and canines;
- C. For symmetric incisor intrusion, deep bite-intrusion;
- D. Molar intrusion, open bite;
- E. Molar mezialization;
- F. Molar distalization;
- G. Dental midline corrections;
- H. Extrusion of impacted canines;
- I. Canted of occlusion, or occlusal cant

The occlusion pathology is too various, but nevertheless for a better understanding of miniscrew implants usage in orthodontics, below is given a more detailed description of TADs clinical appliance.

**A. Closure of extraction space by using miniscrew implants** is done with the aim to close a space that was created after extraction of a tooth and in order to pull the adjusted tooth. Due to such orthodontic treatment a patient does not need a prosthodontics implant.

According to Lee et al. [14] «the combination of two midpalatal miniscrews and a modified transpalatal arch serve as a skeletal anchorage» and the «miniscrew anchorage system allows the maxillary anterior teeth to be retracted effectively without undesirable side-effects such as anchorage loss. There is no need to wear Class II elastics to retract the maxillary incisors and to maintain the molar relationship».

**B. Retraction of incisors and canines** means to move the teeth back. Sometimes the canines and incisors have a tendency to stand out. To retract the incisors and canines and to correct the position of those teeth the miniscrew implants might be applied.

According to Koteswara et al. [15] the «conventional methods of canine retraction are generally grouped into frictional and frictionless mechanics».

Huffman et al. [16] pointed out that the highest mean rate of movement in canine retraction «was 1.37 mm per month», and thus for complete canines retraction about 4-6 months are needed, but Koteswara et al. [15], applying the distraction of the periodontal ligament, achieved a rate of maxillary canines retraction about 2.53 mm per week.

**C. For symmetric incisor intrusion, deep bite** it is necessary to move a tooth into the supporting structures. In case of a deep bite the upper front teeth almost completely overlap the lower front teeth and for correction of such a malocclusion type, there should be applied a force on the upper anterior teeth to move them deeper into the alveolar bone, and towards the mandibular anterior teeth a force for protrusion movement must be applied.

According to Upadhyay et al. [17] «correction of deep bite by extrusion of posterior teeth is difficult to accomplish in non-growing individuals, also the results might not be stable» and «conventional appliances frequently use posterior teeth for facilitating anterior teeth intrusion».

Due to their simple design and small size, the patient

does not feel discomfort and extrusion of adjacent teeth as side effect is minimized. The «mini-implants can solve some problems associated with conventional intrusion devices» [17].

The possibility to be inserted in the oral cavity, even on the alveolar bone between the dental roots, as well as relatively simple implantation technique, that ensures controlling of the direction and amount of force characterize the mini-implants as the most reliable for orthodontic treatment [17]. However, an extreme caution is necessary while placing the implants on some specific dangerous sites in order to avoid inflicting injury on delicate anatomic structures such as vessels, nerves or dental roots [18].

According to Upadhyay et al. [17] a combination «of factors can provide excellent results in the treatment of malocclusions, by increasing anchorage, moving and controlling the teeth and dentoalveolar process in all three planes of space» sagittal, vertical, and transverse one.

**D. Two types of molar intrusion, open bite** are distinguished:

- *Anterior open bite* – when the front teeth fail to touch antagonists there is no overlap between upper incisors and lower incisors teeth.
- *Posterior open bite* – when posterior teeth such as molars or premolars fail to touch their antagonists teeth.

According to Park et al. [19] «anterior open bite is considered to be one of the most difficult problems to treat in orthodontics». Among various methods of treatment the «miniscrews have many advantages over other various temporary anchorage devices», due to the fact that «miniscrews are relatively simple and easy to insert, less traumatic, stable for the optimal force, and make it possible to apply a force immediately after insertion». Park et al. [19] agree with many authors on the point of «fewer limitations of the implantation site and lower costs».

Cambiano et al. [20] opinion was that «molar intrusion might be effectively achieved by using miniscrews as anchorage in patients with an anterior open-bite» as alternative to surgical treatment.

**E. Molar distalization** is moving a tooth along the occlusal plane away from the midline. In that case the molar is moving its position from distal inclination to vertical position due to temporary anchorage device by applying force on the tooth.

The miniscrew can be used as stationary anchorage for maxillary molar distalization, especially for «class II malocclusions, without extractions», that «usually requires distalization of maxillary molars» and «with the use of dental implants, mini-plates, and mini-screw implants as anchorage, the distal movement of anterior teeth or posterior teeth (or both) without anchorage loss has become possible» [21].

According to Celebi [21], the miniscrew treatment is an advantage over implants because treatment with miniscrew does not require that long period of healing and osseointegration.

Another advantage of the miniscrews in comparison

with other methods of orthodontic treatment, according to Singh et al. [22] is that a «miniscrew implant can be immediately loaded and used for group movement of teeth».

**F. Molar mezialization** is the movement of a tooth along the occlusal plane towards the midline. In those cases, a molar is moving its position from mesial inclination to a vertical one, due to temporary anchorage device with the function to apply a force on the tooth.

Wilmes et al. [23] considers that «anchorage control is crucial in treatment of patients», «when protraction of the molars is required without retraction of the anterior teeth and premolars».

Due to cost efficiency and more convenient use in comparison with endosseous implants the «titanium mini-implants are commonly used as a source of absolute anchorage during various types of tooth movement» and the «direct-anchorage mechanics» can be used for «successful closure of a maxillary first permanent molar space with the use of an implant supported appliance (Mesialslider)» [23].

**G. Dental midline corrections** is a midline deviation, and one of the most difficult problems that orthodontists encounter. This problem might be seen in all types of malocclusions, but more commonly, it is found in Class II cases. For correction of the midline deviation, it is necessary to make a differential diagnosis in order to determine the etiology and to evaluate the effects on the occlusion. General causes of midline deviation are:

- Asymmetry of the upper and/or lower arch;
- Lateral mandibular deviation that might be related with posterior cross-bite or not;
- Tipping and/or drifting on the upper and/or lower incisors;
- Any combination of the named above factors.

Unilateral or bilateral placement of miniscrews on one or both arches might help to correct a severely deviated midline without the use of intermaxillary elastics that requires the patient's cooperation, and in this respect the usage of miniscrew is a great advantage.

**H. Extrusion of impacted canines**, or moving of a tooth out of the supporting structures. In case of impacted canines, there can be used miniscrew implants to push out the impacted canine to the dental arch.

According to Kocsis et al. [24] results the «mini-screw anchorage should be taken into consideration when extrusion of an impacted canine is planned».

Philip et al. [25] consider that «application of optimal traction forces will lead to a stress distribution all around the periodontal ligament» that as a consequence will result in «marginal apposition of bone at the alveolar crest».

**I. Canted of occlusion or occlusal cant** might be with, or without facial asymmetry and it appears, due to asymmetric development of the mandible, unilateral extruded molars, or asymmetric dentoalveolar development of the facial skeleton, and/or dentoalveolar development. Occlusal plane canting in the vertical plane is one of the parameters affecting smile esthetics. The canted occlusal plane originates from facial asymmetry and/or vertical position asym-

metry of the right and/or left quadrants of the dental arches without facial asymmetry.

According to Hashimoto et al. [26] «conventionally, the combination of mandibular and maxillary osteotomy is used to correct both mandibular deviation and maxillary canted occlusal plane». As an alternative treatment instead of maxillary osteotomy in correction of mandibular deviation and canted occlusal plane, can be applied treatment with miniscrew anchorage.

By a combined treatment of miniscrew anchorage for correction of the maxillary canted occlusal plane by intrusion of the maxillary molars, and osteotomy for correction of the mandibular deviation can be achieved a good therapeutic result.

Preparation of the placement site is a meticulous and very important process for success of miniscrew implants application.

According to Martinez-Canut et al. [2] «no single factor by itself is clearly associated with PTM; the factor mainly related to PTM is bone loss, followed by tooth loss and gingival inflammation, as bone loss increases, the association of additional factors with PTM, such as tooth loss and gingival inflammation, increases».

The stability in using miniscrew implants depends on the quality and quantity of the bone and on thickness, type and health of the soft tissue. Wilmes et al. [27] pointed out that «insertion torques of orthodontic mini-implants and therefore primary stability varied greatly, depending on bone quality», and «compacta thickness, implant design and implant site preparation have a strong impact on the primary stability of mini-implants for orthodontic anchorage».

According to Motoyoshi et al. [28] the cortical bone with a thickness of less than 0.5 mm is not suitable for miniscrew placement. For successful treatment «the prepared site should have a cortical bone thickness of at least 1.0 mm, and the placement torque should be controlled up to 10 Ncm».

In order to attain a good stability effect, «it is better to place the miniscrews in the attached gingiva (keratinized) gingiva, which is more resistant to inflammation and less likely to develop soft-tissue hypertrophy» [8]. However, «if the miniscrew has to be placed in non-keratinized mucosa, a 3 mm vertical stab incision should be used to prevent the soft tissue from surrounding the miniscrew, as this small incision requires no sutures» [8].

According to Cheng et al. [12] «the absence of keratinized mucosa around mini implants significantly increased the risk of infection and failure», also they mentioned the «bacterial role in the failure of orthodontic mini-implants, since peri-implant infection was associated with a high rate of implant failure (71%)».

Branemark et al. [29], in their experiment on dogs, pointed out that for a «long term stability of intra-osseous titanium implants to restore masticatory function» and for maintenance of a «good anchorage of the implant» are required to be respected following important conditions: «1) Non-traumatic surgical preparation of soft and hard tissues and a mechanically and chemically clean implant. 2) Prima-

ry closure of the mucoperiosteal flap, to isolate the implant site from the oral cavity until a biological barrier has been reestablished. 3) Oral hygiene to prevent gingival inflammation».

The mid palatal suture region is the most favorable placement site for miniscrews in terms of both bone and soft-tissue characteristics. The high density of cortical bone and thin keratinized soft tissue in the palatal region ensures the biomechanical stability of the miniscrew at a higher success rate in comparison with the para palatal suture region that is considered the most suitable area for miniscrew placement in adolescents.

On the mandible, the most adequate bone thickness and safety region for miniscrew insertion is either between the second premolar and first molar, or between the first and second molars. Taking into consideration that the thinnest bone was found between the first premolar and the canine, the miniscrew implantation should be done 11 mm below the alveolar crest, as well the miniscrews might be placed in the alveolar mucosa and attached gingiva.

For success of treatment with miniscrews implants, the placement site plays an important role. The miniscrews can be placed in the inter-radicular space between tooth roots, either buccally or lingually; in the hard palate, below the anterior nasal spine; and in the infra zygomatic crest, maxillary tuberosity, edentulous areas, chin and retro molar areas.

In cases when there is not enough space for implant, then «additional space can be created by intentional separation of the dental roots during the initial stages of orthodontic treatment» [17].

For example, Cheng et al. [12] for retraction of the protruded anterior teeth; protraction of retruded posterior teeth; molar intrusion and molar uprighting had used several types of extradental anchors such as:

- Conventional osseointegrated implant,
- Onplant,
- Mini-implants with “a cumulative success rate of 89%” [12].

As advantages of the of the miniscrew treatment Cheng et al. [12] pointed out the “low cost, simple surgical placement, and high versatility”. Similar opinions have Upadhyay et al. [17] who marked out that the “miniscrews are now accepted as a simple and effective tool in daily orthodontic practice and orthodontists commonly use them in a variety of clinical situations”.

Considering all mentioned above, the success rate in miniscrew implants does not depend only on bone quality, but it depends as well on the soft-tissue thickness, oral hygiene, root proximity and other anatomic-physiological peculiarities such as dangerous areas, the maxillary tuberosity in case of the third molar eruption, etc.

Anchorage preparation is an important factor in the success of orthodontic treatment. Reducing the need for patient cooperation, there is an increase in the quality and efficiency of treatment, ease placement and lower costs are the main advantages of mini-screws in comparison with conventional and other skeletal anchorage preparation methods.

Analyzing the «long-term stability of micro-screws under different loading protocols» on animal experiments, Zhang et al. [30] specified that, the «orthodontic micro-screws tend to suffer a failure rate of about 10% to 30%, which is much higher than conventional implants», and as a risk factor «for reducing the long-term stability of micro-screws» they pointed out the counterclockwise loading.

According to Arantes et al. [31] «the larger number of threads and their greater angle of inclination resulted in less resistance to deformation and induced a higher level of tension in the mini-implant and cortical bone when subjected to forces, especially when inserted at an angle of 45° to the cortical bone».

Goyal et al. [32] consider that «the popularity of titanium has been attributed to its chemical purity and its ability to form an adherent, passivating oxide film which forms at the rate of 100 Å per minute» that has a significant role in development of manufacturing implants industry «with micro and submicro (nano) topography».

According to Kuroda et al. [33] the «miniscrews can provide stationary anchorages for various tooth movements and even make it possible to move the tooth in directions which have been impossible with traditional orthodontic mechanics».

Development of implants industry and particularly «miniscrew anchorage has greatly expanded the limit of clinical orthodontics» [33] but nevertheless, there still are some risk factors in miniscrews use and success of treatments depends a lot on techniques of miniscrew insertion and stability elements.

Liou et al. [34] sustain that «miniscrews are a stable anchorage but do not remain absolutely stationary throughout orthodontic loading», in some patients was mentioned their movement. In order «to prevent miniscrews hitting any vital organs because of displacement, it is recommended that they be placed in a non-tooth-bearing area that has no foramen, major nerves, or blood vessel pathways, or in a tooth-bearing area allowing 2 mm of safety clearance between the miniscrew and dental root» [34].

Regarding the risk of miniscrews treatment Mohammed et al. [35] in published paper emphasized that «miniscrews inserted in interradicular locations between the first molars and second premolars suffer from a failure rate of 9.2% for those inserted in the maxilla and 13.5% for those inserted in the mandible».

Thus, the primary stability is a major element of success in miniscrews using. The stability might be affected by many factors among which are:

- Thickness and quality of bone;
- Design of the miniscrew, including its diameter and length, tapering, thread length and pitch;
- Placement conditions (pre-drilling, penetration depth and number of involved cortical plates, insertion angle, etc.).

#### **Possible risks of miniscrew treatment:**

- The screw may touch a tooth root during placement.
- The screw becomes loose.

- Sometimes a plastic device is used as a guide to help place the screw in exactly the right position.

Nowadays, due to their advantages the miniscrew anchorage devices are widely used in orthodontic treatment, but for patient benefit an orthodontist should be aware of risk factors, as well as to take into consideration the disadvantages of miniscrew treatment.

### Conclusions

1. Development of implants industry and particularly miniscrew anchorage has been rapidly increased in the recent years, but nevertheless, there still are some risk factors of miniscrews use and success of treatment depends a lot on techniques of miniscrew insertion and stability elements.

2. The “anchorage control during tooth movement is one of the main factors for ensuring successful orthodontic treatment” [8] and “the most important keys for achievement of success in clinical orthodontics” [33].

3. The advantages of miniscrews, in comparison with other methods of orthodontic treatment might be resumed to: lower costs, easy placement, no need for patient cooperation, high quality and efficiency of treatment.

4. Among the most undesirable side effects of miniscrews use can be marked out the screw fracture, screw-root proximity, damages of soft and hard tissues, displacement under orthodontic loading, etc.

### References

- Towfighi PP, Brunsvold MA, Storey AT, Arnold RM, Willman DE, McMahan CA. Pathologic migration of anterior teeth in patients with moderate to severe periodontitis. *J Periodontol.* 1997;68:967-72.
- Martinez-Canut P, Carrasquer A, Magan R, Lorca A. A study on factors associated with pathologic tooth migration. *J Clin Periodontol.* 1997;24(7):492-7.
- Khorshidi H, Moaddeli MR, Golkari A, Heidari H, Raoofi S. The prevalence of pathologic tooth migration with respect to the severity of periodontitis. *J Int Soc Res Community Dent.* 2016;6(Suppl 2):S122-S125. doi:10.4103/2231-0762.189738.
- Brunsvold MA. Pathologic tooth migration. *J Periodontol.* 2005;76(6):859-66.
- Veeraiyan DN. Textbook in prosthodontics. 2nd ed. New Delhi: JaypeeBrothers Medical Publishers; 2018.
- Leventhal GS. Titanium, a metal for surgery. *J Bone Joint Surg Am.* 1951;33:473-474.
- Jokstad A. Why did Professor Per-Ingvar Branemark never receive the Nobel Prize in Medicine? *Clin Exp Dent Res.* 2017;3(3):79-80.
- Uzuner FD, Aslan BI. Miniscrew applications in orthodontics. In: Turkyilmaz I, editor. Current concepts in dental implantology (e-book). London: InTech; 2015 [cited 2019 May 18]. Available from: <https://www.intechopen.com/books/current-concepts-in-dental-implantology/miniscrew-applications-in-orthodontics>
- Singh K, Kumar D, Jaiswal RK, Bansal A. Temporary anchorage devices – Mini-implants. *Natl J Maxillofac Surg.* 2010;1(1):30-34.
- Labanauskaitė B, Jankauskas G, Vasiliauskas A, Haffar N. Implants for orthodontic anchorage. Meta-analysis. *Stomatologija.* 2005;7:128-32.
- Chang HP, Tseng YC. A novel  $\beta$ -titanium alloy orthodontic wire. *Kaohsiung J Med Sci.* 2018;34:202-206.
- Cheng SJ, Tseng IY, Lee JJ, Kok SH. A prospective study of the risk factors associated with failure of mini-implants used for orthodontic anchorage. *Int J Oral Maxillofac Implants.* 2004;19(1):100-6.
- Song L, Wu J. Stability and safety of mini-screw implant anchorage in the oral orthodontics. *Int J Clin Exp Med.* 2019;12(4):4028-4035. ISSN:1940-5901/IJCEM0089130.
- Lee J, Miyazawa K, Tabuchi M, Sato T, Kawaguchi M, Goto S. Effectiveness of en-masse retraction using midpalatal miniscrews and a modified transpalatal arch: Treatment duration and dento-skeletal changes. *Korean J Orthod.* 2014;44(2):88-95.
- Koteswara Prasad NK, Chitharanjan A, Kailasam V. Rapid maxillary canine retraction by dental distraction: a clinical study. *Natl J Maxillofac Surg.* 2014;5(1):6-13. doi:10.4103/0975-5950.140148.
- Huffman DJ, Way DC. A clinical evaluation of tooth movement along arch wires of two different sizes. *Am J Orthod.* 1983;83:453-9.
- Upadhyay M, Nagaraj K, Yadav S, Saxena R. Mini-implants for en masse intrusion of maxillary anterior teeth in a severe Class II division 2 malocclusion. *J Orthod.* 2008;35(2):79-89.
- Baker EW, editor. Anatomy for dental medicine. 2nd ed. New York: Thieme; 2015. 554 p.
- Park YC, Lee HA, Choi NC, Kim DH. Open bite correction by intrusion of posterior teeth with miniscrews. *Angle Orthod.* 2008;78(4):699-710.
- Cambiano AO, Janson G, Lorenzoni DC, Garib DG, Dávalos DT. Non-surgical treatment and stability of an adult with a severe anterior open-bite malocclusion. *J Orthod Sci.* 2018;7:2. doi:10.4103/jos.JOS\_69\_17.
- Celebi AA. Mini-screw supported molar distalization: a new method. *J Orthod Res.* 2015;3(3):199-203.
- Singh S, Mogra S, Shetty VS, Shetty S, Philip P. Three-dimensional finite element analysis of strength, stability, and stress distribution in orthodontic anchorage: a conical, self-drilling miniscrew implant system. *Am J Orthod Dentofacial Orthop.* 2012;141(3):327-36. doi: 10.1016/j.ajodo.2011.07.022.
- Wilmes B, Vasudavan S, Dreschera D. Maxillary molar mesialization with the use of palatal mini-implants for direct anchorage in an adolescent patient. *Am J Orthod Dentofacial Orthop.* 2019;155(5):725-732.
- Kocsis A, Seres L. Orthodontic screws to extrude impacted maxillary canines. *J Orofac Orthop.* 2012;73(1):19-27. <https://doi.org/10.1007/s00056-011-0057-9>.
- Philip P, Rao A. Orthodontic extrusion of an impacted tooth with a removable appliance and a bonded attachment: a case report with relevant biomechanics. *J Interdiscip Dentistry.* 2014;4:46-9.
- Hashimoto T, Fukanaga T, Kuroga S, Sakai Y, Yamashiro T, Takano-Yamamoto T. Mandibular deviation and canted maxillary occlusal plane treated with miniscrews and intraoral vertical ramus osteotomy: functional and morphologic changes. *Am J Orthod Dentofacial Orthop.* 2009;136(6):868-877.
- Wilmes B, Rademacher C, Olthoff G, Drescher D. Parameters affecting primary of orthodontic mini-implants. *J Orofac Orthop.* 2006;67(3):162-74.
- Motoyoshi M, Youshida T, Ono A, Shimizu N. Effect of cortical bone thickness and implant placement torque on stability of orthodontic mini-implants. *Int J Oral Maxillofac Implants.* 2007;22(5):779-84.
- Branemark PI, Breine U, Adell R, Hansson B. O. Lindstrom J, Ohlsson A. Intra-osseous anchorage of dental prostheses: I. Experimental Studies. *Scand J Plast Reconstr Surg.* 1969;3(2):81-100.
- Zhang JN, Lu HP, Bao XC, Shi Y, Zhang MH. Evaluation of the long-term stability of micro-screws under different loading protocols: a systematic review. *Braz Oral Res.* 2019;33:e046.
- Arantes VD, Corrêa CB, Lunardi N, BoeckNeto RJ, Spin-Neto R, Boeck EM. Insertion angle of orthodontic mini-implants and their biomechanical performance: finite element analysis. *Rev Odontol UNESP.* 2015;44(5):273-9. doi.org/10.1590/1807-2577.0081.
- Goyal E, Kapoor D, Soni N, Jain R, Sagar G. Osseointegration - A review. *Arch Dent Med Res.* 2016;2(1):9-14.
- Kuroda S, Tanaka E. Risks and complications of miniscrew anchorage in clinical orthodontics. *Jpn Dent Sci Rev.* 2014;(50):79-85.
- Liou EJW, Pai BCJ, Lin JCY. Do miniscrews remain stationary under orthodontic forces? *Am J Orthod Dentofacial Orthop.* 2004;126(1):42-47.
- Mohammed H, Wafaie K, Rizk MZ, Almuzian M, Sosly R, Bearn DR. Role of anatomical sites and correlated risk factors on the survival of orthodontic miniscrew implants: a systematic review and meta-analysis. *Prog Orthod.* 2018;19(1):36. doi:10.1186/s40510-018-0225-1.