



ATYPICAL PRESENTATION OF A HIGH-GRADE ASTROCYTOMA IN A PEDIATRIC RHEUMATOLOGY PRACTICE

Ninel REVENCO^{1,2}, Anatol LITOVCEANU³, Svetlana HADJIU¹, Cornelia CALCII^{1,4}, Rodica EREMCIUC^{1,2}, Olga GAIDARJI¹

¹Pediatric Department, Nicolae Testemițanu State University of Medicine and Pharmacy, Republic of Moldova

²Rheumatology unit, Mother and Child Health care Hospital, Chisinau, Republic of Moldova

³Neurosurgery unit, Mother and Child Health care Hospital, Chisinau, Republic of Moldova

⁴Neurology unit, Mother and Child Health care Hospital, Chisinau, Republic of Moldova

Corresponding author: Ninel Revenco, e-mail: ninel.revenco@usmf.md

DOI: 10.38045/ohrm.2021.1.04

CZU: 616-006.484.03-053.2

Key words: astrocytoma, brain tumor, musculoskeletal mask, children.

Introduction. Hip pain is common in childhood. The main dilemma is to differentiate between benign conditions and those causing significant morbidity and mortality.

Material and methods. A clinical case report of a toddler presenting with Musculoskeletal (MSK) mask due to a brain tumor.

Results. A 2-year-old boy presented to the ER complaining of hip pain, muscle weakness, and limping. The neurologic exam showed no abnormalities. At the 3rd day of admission, patient condition worsened, and papillary edema was revealed. MRI revealed a tumor in the suprasellar cistern/prepons region.

Conclusions. In case of atypical MSK symptoms, a careful evaluation of children should be carried out to prevent any delay in diagnosis.

Cuvinte cheie: astrocitom, tumoare cerebrală, mască musculoscheletală, copii.

PREZENTAREA ATIPICĂ A UNUI CAZ DE ASTROCITOM ÎN PRACTICA CLINICII DE REUMATOLOGIE PEDIATRICĂ

Introducere. Durerea coxofemurală este frecventă în copilărie, însă esențial este de a diferenția afecțiunile benigne de cele care cauzează morbiditate și mortalitate semnificative.

Material și metode. Vom raporta cazul unui copil de doi ani cu tumoare cerebrală, care a prezentat inițial diverse acuze din partea sistemului musculoscheletal.

Rezultate. Un copil s-a adresat la Departamentul de urgență cu dureri în articulația coxofemurală, mers șchiopătat, slăbiciuni. Examenul neurologic nu a depistat anumite anomalii. În a 3-a zi starea copilului s-a agravat și a fost efectuat RMN cerebral, la care s-a identificat o formațiune a cisternei supraselare/prepontine.

Concluzii. În cazul simptomelor musculoscheletice atipice, o evaluare minuțioasă a copiilor este esențială, pentru a asigura stabilirea cât mai timpurie a diagnosticului.

INTRODUCTION

Hip pain is quite common in childhood. An important dilemma is to differentiate between benign and self-limiting disorders and those that cause significant morbidity and mortality such as malignant processes (1). This present case report highlights the importance of considering malignancy in the differential diagnosis of childhood hip pain, despite its rare occurrence.

In childhood, brain tumors often involve the musculoskeletal system and mimics and a variety of orthopedic problems at presentation. An accurate anamnesis and physical examination can still be misleading. Moreover, laboratory tests and other investigations are usually inconclusive (2,3).

Thus, additional information is needed to better understand the variety of clinical presentations, inclusively mimickers, diagnostic options, management strategies, postoperative course, and longterm outcomes of patients with malignancies, particularly of those with atypical presentations (4).

MATERIAL AND METHODS

A clinical case of a 2-years-old male patient with musculoskeletal mask due to a brain tumor was reported. The patient was admitted to the Rheumatology clinic from a tertiary level hospital providing pediatric services. We will highlight its peculiarities in correlation with available literature data from PubMed/NCBI, Medline, Hinari with an emphasis on clinical and imaging features that may aid in diagnosis. The literature review was based on the analysis of the published case presentations, synthesis and reviews on the following key words: astrocytoma, brain tumor, musculoskeletal mask, children.

RESULTS

A 2-year-old boy presented to the emergency department by self-addressing. He felt sick for the last 2 days, presenting an acute upper respiratory infection with catarrhal signs at the onset of clinical symptoms and no fever episodes. At the 3rd day of the disease, he started to complain of painful left hip and difficulties on walking. Parents were worried and referred to the hospital. There was no previous relevant medical history, any chronic disease or similar past episodes. The

child's physical development corresponded to his age: weight at the 71 percentiles (+0.56 SDS according to WHO2000 standards), height at the 86 percentiles (+1.09 SDS), head circumference at the 80 percentiles (+0.84 SDS). Moreover, none neurological milestones abnormalities were revealed from his history taking, neither in the medical outpatient documentation. On physical examination, he walked with a limp, but due to pain exacerbation he refused to walk by himself. Movements of the left hip were painful (mainly external rotation), but not restricted. He complained of muscle weakness and, consequently, difficulty to sit up alone, as well as to maintain after getting help. Also, he complaint of mild dysuric symptoms, mainly during micturition. During the exam he was very moody, irritable and excessively cried.

The emergency department organized a multidisciplinary approach, involving a large team from different units like pediatric neurology, orthopedics, pediatric surgeon, pediatric urologist and pediatric rheumatologist. The neurology exam didn't show any abnormalities at that time – no data for neuropathy or focal signs.

Further laboratory tests did not reveal any abnormalities: no anemic syndrome, all acute phase reactants (ESR, CRP, fibrinogen) were within normal range. Biochemical serum tests also didn't show any possible underlying causes – normal values for muscle enzymes, liver and renal tests. An initial X-ray to the pelvis revealed no changes. An ultrasound of the left hip was performed, revealing small infusion.

During the follow-up, at the 3rd day of admission, our patient presented repeated matinal vomiting and worsening of previous signs – muscle weakness, missing gross motor milestones, which were previously present, ataxia, an excessive crying when being in orthostatic position, superficial sleeping time. On repeated neurological and ophthalmological examination, an abnormal optic disc appearance with papillary edema and a marked venous congestion was reported. Thus, the following step of the diagnostic approach was the brain MRI 1.5 T with contrast. MRI revealed a volume mass tumor of 58*47*47mm within the suprasellar cistern/prepons region, with a solid non-homogenous component and cystic appearance, compressing the 3rd ventricle and, respectively, with acute obstructive biventricular hydrocephaly (fig.1).

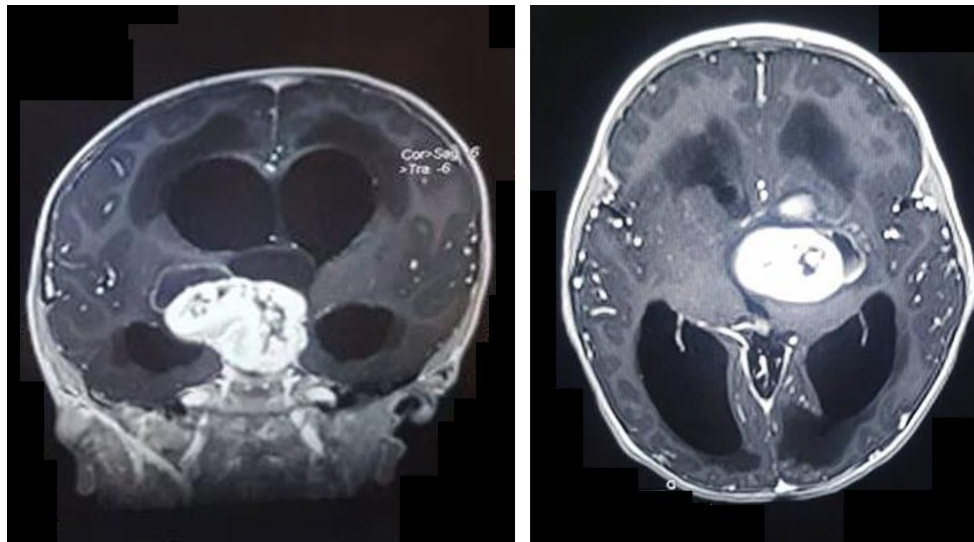


Figure 1. Preoperative coronal and axial postcontrast T1 - Weighted MRI images.

The patient was transferred to pediatric neurosurgery department where he underwent several surgical interventions. Figure 2 shows the 2nd MRI image following the first intervention, which carried out decompression via a shunt through the right ventricle. However, the tumor increased in volume at a 7-day interval. It increased to 64*98*55 mm with invasion of the 3rd ventricle and left lateral ventricle.

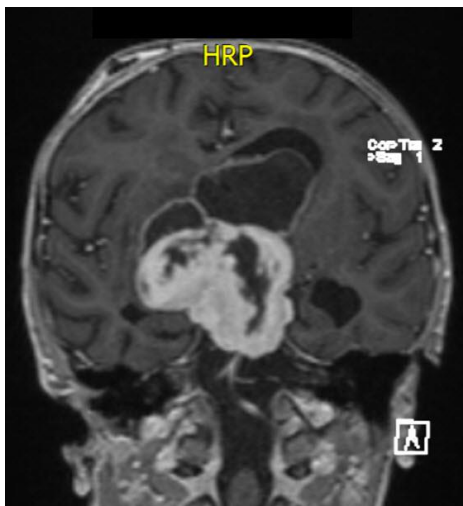


Figure 2. Postoperative (1st step), coronal post-contrast MRI.

Another surgical intervention was performed in order to get the tumor biopsy. The histological exam established a high-grade astrocytoma, IV WHO degree of malignancy.

At 6 months after the onset of the disease, our patient continued chemotherapy and radiotherapy in the oncology pediatric department. Additionally, the patient's follow-up was carried out within the neurosurgery clinic.

DISCUSSIONS

Nowadays, primary brain tumors are the leading cause of cancer-related mortality in children and adolescents aged below 20 years, now surpassing leukemia (5). Figure 3 shows the structure and incidence of CNS tumors among children (3).

Astrocytoma is the foremost neuroglial tumor occurring throughout infancy and childhood and is derived from and composed of astrocytes showing varying degrees of differentiation (6). These tumors usually present within the first 2 years of life, most often by 4-6 months of age. Males are more commonly affected than females (1.5-1.7:1), and patients commonly present with rapidly enlarging head circumference and, some-times, vomiting and seizures (4).

Brain tumors in children can present with many different signs and symptoms, largely dependent on the location of the tumor (7). Headache, nausea, vomiting, and vision loss can be caused by increased intracranial pressure due to obstruction of cerebrospinal fluid flow by tumor growth. Visual field deficits and hormone deficiencies can be presenting signs of suprasellar masses (3). Ataxia and clumsiness can be caused by posterior fossa tumors, and seizures or personality changes can result from tumors involving cortical areas, particularly in frontal brain regions (3).

According to current classification, there are low- and high-grade astrocytoma. Those ones differ significantly in terms of their histological grading, site of origin, treatment, and prognosis (6). Figure 4 represent a brief presentation of astrocytomas distribution among pediatric population (5).

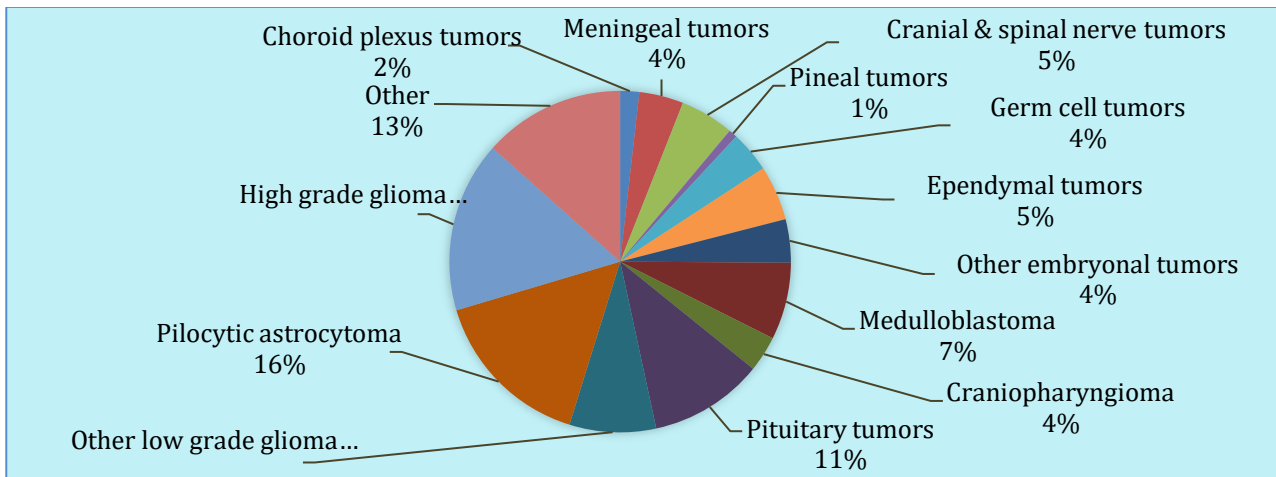


Figure 3. Primary CNS tumors in children, 0-18 y.o. (Segal D., 2016) (3).

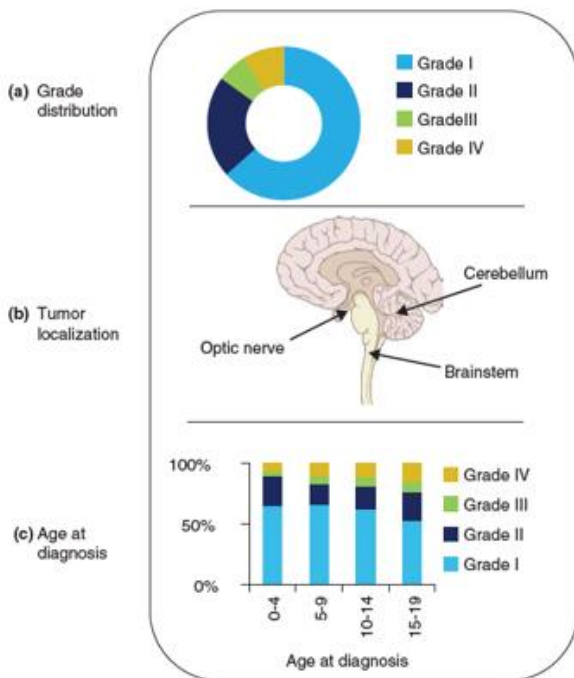


Figure 4. Overview of the pediatric astrocytomas: grade distribution, tumor localization, age at diagnosis (Gerges N., 2013) (5).

The WHO’s grading system is based on histologic criteria and is used to determine prognosis, select treatment, and stratify patients for research studies.

The present case study represent a 4th degree of astrocytoma, which highlights the specific features as (5):

- **Histology** – Infiltrative, nuclear atypia, high mitotic activity, pseudo-palisading necroses, florid microvascular proliferation.
- **Location** – Cerebrum, cerebellum and spine, but brainstem glioblastoma multiforme (DIPGs) are more frequent in children.

- **Prevalent age group** – Adults, except a *diffuse intrinsic pontine glioma*, which is prevalent in children below 10 years of age.
- **Therapy** – Surgical resection when possible, followed by adjuvant radiation and chemotherapy.
- **Prognosis** – Very poor (1.2% 5-year survival).

In general, for CNS tumors, the 5-year survival rates vary widely with tumor type and have improved greatly with improved surgical and oncologic care. At present, the overall 5-year survival rate for children aged 0–19 years after diagnosis with a CNS tumor is estimated to be 73.6% (3). Many studies have indicated that, as a group, malignant gliomas in children and young adults carry a more favorable prognosis than do comparable lesions in older patients (8).

Due to the infiltrative nature of these tumors, however, even extensive surgical resection will leave malignant cells in the region. Many high-grade gliomas occur in highly sensitive brain areas, such as the thalamus or pons, where even a limited resection may be impossible (3).

Ongoing studies aim to illuminate new avenues to address drug resistance and to identify novel molecularly targeted agents that may work synergistically, finally providing improved therapeutic options in *diffuse intrinsic pontine glioma* and other diffuse midline gliomas with genetic mutations (9). Researchers are discovering that the genetic and epigenetic characteristics of a tumor are far more instructive in helping to predict its behavior and choose optimal therapies (3). The molecular revolution for pediatric brain tumors has begun, and one can envision an era of highly specialized therapeutics will follow (10).

CONCLUSION

1. Our findings highlighted the therapeutic dilemmas that arise with musculoskeletal mimics, as well as the importance of thorough investigation to distinguish mimickers from true neoplasms. This case emphasizes not only the need for a careful assessment of children with persistent or atypical hip pain but also encourages the enriched knowledge and practical experience sharing.
2. Any medical diagnosis should take a multimodal approach, as entities that mimic neoplasms have overlapping features and may present detrimental outcomes if they are underdiagnosed.
3. Despite being a rare presentation of brain tumor, the delay in the diagnosis may have devastating consequences.

CONFLICT OF INTERESTS

All authors declare no competing interests.

REFERENCES

1. McCarville B. The child with bone pain: malignancies and mimickers. *Cancer Imaging*. 2009; 9:S115-S121. doi: 10.1102/1470-7330.2009.9043
2. Alves da Silva S, Mendes J, Carvalho J, et al. Irritable Hip as the inaugural symptom for neuroblastoma. *Case Reports in Orthopedics*. 2018; 4. <https://doi.org/10.1155/2018/7428350>
3. Segal D, Karajannis MA. Pediatric brain tumors: An update. *Curr Probl Pediatr Adolesc Health Care*. 2016; 1-9. <http://dx.doi.org/10.1016/j.cppeds.2016.04.004>.
4. Naylor RM, Wohl A, Raghunathan A, et al. Novel suprasellar location of desmoplastic infantile astrocytoma and ganglioglioma: a single institution's experience. *J Neurosurg Pediatr*. 2018; 22(4): 397-403. doi:10.3171/2018.4.PEDS17638
5. Gerges N, Fontebasso AM, Albrecht S, et al. Pediatric high-grade astrocytomas: a distinct neuro-oncological paradigm. *Genome Medicine*. 2013; 5:66. <http://genomemedicine.com/content/5/7/66>
6. Hart IJr. Perinatal (fetal and neonatal) astrocytoma: a review. *Childs Nerv Syst*. 2016; 32:2085-2096. doi 10.1007/s00381-016-3215-y
7. Samsudin EZ, Kamarul T, Mansor A. Avoiding diagnostic pitfalls in mimics of neoplasia: the importance of a comprehensive diagnostic approach. *Singapore Med J*. 2015; 56(5): e92-e95. doi:10.11622/smedj.2015082
8. Nakamura M, Shimada K, Ishida E, et al. Molecular pathogenesis of pediatric astrocytic tumors. *Neuro-Oncology*. 2007; 9:113-123. doi:10.1215/15228517-2006-036
9. Vitanza NA, Cho Y-J, Advances in the biology and treatment of pediatric central nervous system tumors. *Curr Opin Pediatr*. 2016; 28:34-39. doi:10.1097/MOP.0000000000000309
10. Robinson GW, Hendrik W, Resnick A. *Exploiting laboratory insights to improve outcomes of pediatric central nervous system tumors*. ASCO Educational book; 2016. Available from: <http://www.ascopubs.org> by 5.189.207.136 [Accessed 7th April 2019]

Date of receipt of the manuscript: 26/06/2020

Date of acceptance for publication: 30/11/2020

Ninel REVENCO, ORCID ID: 0000-0002-5229-7841
Svetlana HADJIU, ORCID ID: 0000-0001-5281-3626
Cornelia CALCII, ORCID ID: 0000-0002-2608-2417
Rodica EREMCIUC, ORCID ID: 0000-0002-7610-1508
Olga GAIDARJI, ORCID ID: 0000-0003-4558-6343