

340.6  
§24

**STATE UNIVERSITY OF MEDICINE AND PHARMACY  
„NICOLAE TESTEMITANU”**

Department of Forensic Medicine

**Vasile Șarpe**

**Medico-legal examination of the cadaver  
(methodic and didactic guideline)**

**Chișinău 2013**

242.6  
324

### CONTENT:

Forensic or anatomopathological autopsy:  
 Instead of overview .....4  
 Glossary.....6

**Chapter 1.** Examination of the cadaver at the death scene.....8  
 The main purposes and matters.....8  
 Didactic material.....8  
 Methodicaids.....8  
 Theoretical and didactic support.....8

**Chapter 2.** Cadaverous changes.....13  
 The main purposes and matters.....13  
 Didactic material.....13  
 Methodic aids.....13  
 The classification of cadaverous changes.....13  
 Early cadaverous changes.....14  
 Belated cadaverous changes.....16

**Chapter 3.** Establishment of the fact of death and time since death.....20  
 The main purposes and matters.....20  
 Didactic material.....20  
 Methodic aids.....20  
 Diagnosis of death.....20  
 Assessment the time of death.....21

**Chapter 4.** Postmortem records.....26  
 The main purposes and matters.....26  
 Didactic material.....26  
 Methodic aids.....26  
 Death certificate.....27  
 Autopsy report.....28  
 Scheme of forensic autopsy report.....29  
 Bibliography.....39

713793

Universitatea de Stat de  
 Medicină și Farmacie  
 «Nicolae Testemițanu»  
 Bibliotecă

SL2

## **FORENSIC OR ANATOMOPATHOLOGIC AUTOPSY: INSTEAD OF OVERVIEW**

The medico-legal examination of the corpse is a kind of research, which has its own specific features and requires special training. In the Republic of Moldova there are two types of autopsies: medico-legal (forensic) and anatomopathological (hospital).

The forensic examination of the cadaver, as well as other subjects of medico-legal studies is executed on a written order or request from the police officer or other law officials, while the anatomopathological one is performed only on a base of verbal indication from hospital administration staff.

The reasons of medico-legal examination of a cadaver are:

- a) violent death (homicide, suicide, accident);
- b) sudden death (suspicious death, without a doctor's supervision, etc.);
- c) corpses of unknown persons, including the corpse of a newborn baby;
- d) death occurred in hospital within 24 hour after hospitalization (without a clinical diagnosis);
- e) death in hospital due to a malady and which followed more than 24 hours after hospitalization, if there are complaints from relatives;
- f) malpractice (medical errors, mistakes, iatrogenic diseases, etc.)

According to art. 143 of the Penal Procedure Code of the Republic of Moldova (P.P.C.) the forensic autopsy is compulsory for establishment the cause of death, identification the body, and assessment the degree of injury severity.

Hospital autopsies are performed on inpatients of hospitals and their purposes are to confirm the clinical diagnosis and to study the peculiarities of the disease.

Forensic pathologists, beside the question mentioned above, also have to establish and to describe the signs of violence, manner of death, time of death (cadaverous changes). Also, forensic investigation includes examination of the clothes, footwear, etc.

The anatomopathological autopsy is directed to affected organs, but during forensic necropsy it is obligatory to examine three main cavities of the body: cranial, thoracic, and abdominal. Sometimes (trauma) it is necessary to supplementary open other cavities or parts of the corpse (spinal column, joints, limbs).

Belated cadaverous changes (e.g. putrefaction) can't be a consideration to refuse the forensic autopsy.

The majority of cadavers subjected to forensic autopsy are examined first at the death scene.

## GLOSSARY

*Algor mortis (cooling)* – the reduction of body temperature following death;  
*Associated disease* – diseases or traumas which can be the cause of the death only in the case of their combination;

*Attitude of the cadaver* – the position of different anatomical parts of the body (at the death scene);

*Autolysis (self-digestion)* – the destruction of biological objects by their own enzymes;

*Autopsy (necropsy, postmortem examination)* – the dissection and examination of a dead body to determine the cause of death or other questions;

*Autopsy report* – a written record of a necropsy;

*Belated cadaverous changes* – any of cadaverous change that occurs starting with the next day after death;

*Biological samples (specimens)* – an amount from human body (blood, hair, sperm, etc.) which is used in forensic expertise (identification, proofing);

*Cadaverous changes* – specific physical and biochemical processes which occur after death;

*Cause of death* – the trauma or disease that produces the death;

*Circumstances of the crime (fact, event, crime)* – the accessory information or detail of an event or a condition;

*Coexisting disease* – a disease existing simultaneously with the principal one that has no impact to it;

*Complication* – a disease or disorder arising as a consequence – of another (main) disease;

*Conclusion (forensic conclusion)* – the result of an expertise and, as a rule, it consists of answers to requested question;

*Concurrent disease* – each of diseases or traumas that can be separately the cause of death (if more);

*Congelation* – the process of congealing the cadaver or a frozen cadaver;

*Death certificate (medical death certificate)* – a standard form which includes the personal and medical data of the deceased;

*Death scene (crime scene)* – the place where an extraordinary event has occurred or a person has died;

*Dehydration* – the process of losing water of the body;

*Diagnosis (forensic diagnosis)* – the identification of diseases found during an autopsy (main, complication, preexisting, coexisting) which are recorded as nosologies (according ICD) joined with a summary of changes (lesions);

*Early cadaverous changes* – any of cadaverous change that occurs within the first day after death;

*Evidence* – a matter produced before a court of law in an attempt to prove or disprove a point in issue, such as biological samples;

*Expertise* – a scientific and practical research with the purpose to bring a conclusion towards a problem;

*Lignification* – the process of tanning of the cadaver as a result of being a long time in acid medium (tannic and humic acids);

*Livor mortis (postmortem hypostasis, lividity)* - a settling of the blood in the lower portions of the cadaver;

*Location of the cadaver* – the place where the cadaver was found;

*Lodge of the cadaver*– the place underlying the cadaver;

*Manner of death* – the fashion or circumstances that result in death;

*Mummification* – the complete dehydration of the corpse;

*Negative circumstances* – the lack of those marks, signs, objects that should necessarily be present on the death scene;

*Ordinance* – an authoritative provision to perform an expertise;

*Pallor mortis* – the post mortem paleness of the skin;

*Petrification (mineralization)* – the converting of the organic matter of the cadaver into a mineral one;

*Position of the cadaver* – the relation of the cadaver to the immovable objects at the scene of death;

*Preexisting (background) disease* – the disease or trauma that pathogenically influences the principal one, but not etiologically;

*Principal (main disease)* – the disease or trauma that is the cause of death;

*Protocol of death scene investigation* – a record of data and observations at the death scene;

*Putrefaction (decomposition)* – the disintegration of proteins and tissues by microorganisms;

*Request of the forensic examination* – the application to perform a forensic examination;

*Rigor mortis (rigidity)* – the postmortem stiffness of muscles;

*Saponification* – the process in which the cadaver fat is converted into soap;

*Sudden death* – the unexpected or quick death, as a rule of apparent healthy persons;

*Supravital reactions (intermediary life)* – the phenomena manifested after death by some cells, tissues, organs or parts of the body, during their vitality;

*Time of death (postmortem interval)* – the time elapsed from the death installation till examination of the corpse;

*Violent death* – the death that was caused by external factors (mechanical, physical, chemical, etc.); it can be unintentional (accident) or intentional (suicide, homicide).

### EXAMINATION OF THE CADAVER AT THE DEATH SCENE

#### The main purposes and matters

To know:

- ✓ the methodology of examination of the cadaver at the scene of death
- ✓ the kinds of crime scene investigation
- ✓ the main objectives of the death scene investigation
- ✓ the doctor's tasks at the scene of death
- ✓ the scheme and sequence of examination of the cadaver at the death scene
- ✓ the scheme of describing the injuries

To be able to:

- ✓ examine the cadaver at the scene of death
- ✓ establish the real death
- ✓ assess the time of death
- ✓ correctly describe the injuries

#### Didactic material

- ✓ this guideline
- ✓ lectures
- ✓ other didactic material (tests, situational problems, copies of protocols of death scene investigation)
- ✓ cadavers (thanatological department)

#### Methodic aids

1. Organizational issues
2. Quiz
3. Individual work
4. Solving problems
5. Checking the final level of knowledge
6. Summary and home tasks

#### Theoretical and didactic support

Death scene (crime scene) is an area or a room where a crime or other extraordinary event (homicide, robbery, suicide, rape, accident, etc.) has occurred. Finding a human corpse is an extraordinary event and the place of its discovering is considered death scene, even if the crime was committed in another place. Such cases require a process of investigation.

In the Republic of Moldova, according to art.118 of P.P.C, the police officer investigates the crime scene. Also art.120 of P.P.C explains that external examination of the corpse at the place of discovering is executed by the police officer, with the participation of the forensic doctor (specialist in forensic medicine) or another physician in case of absence of the forensics. Other specialists may be attracted to corpse examination, as well. After examination the body is sent to the forensic institution.

The police officer records a protocol of death scene investigation (art. 124 P.P.C.) where he notes all actions and facts found during research, lists and describes evidences discovered at the scene of death, and exposes all the circumstances, the course and the results of procedural action, as well as the technical equipment used. To the protocol of death scene investigation are attached sketches, projects and materials that reflect the usage of technical equipment.

The crime scene investigation is usually done in two stages - **static** and **dynamic**.

In the static stage of investigation the cadaver and all things around are described without changing their initial position, but also sketches and photos are made.

The death scene examination continues with the dynamic stage in which the found objects can be taken, moved, flipped, etc., and it is possible to do a more detailed examination.

During the examination of separate sectors of the death scene it is allowed to alternate the mentioned above stages.

There are three kinds of crime scene investigation: **primary**, **supplementary** and **repeated**.

The primary examination is the first research of the death scene and, as a rule, the single one. In some cases there is a need for supplementary or repeated research.

Supplementary research is performed in cases when during the subsequent investigation (e.g. autopsy) is found new information, also when at the primary examination not all objects have been studied or have been incompletely investigated. Usually, the supplementary studies are performed only on some sectors or some special items.

Repeated investigation of the crime scene occurs in cases when primary research was conducted on bad weather (rain, snow, poor lighting, etc.) or when the primary examination was performed poorly and so it is executed once again.



The examination on the death scene has the following main objectives:

- to look for evidences: discover, research, collect, pack, preserve and send them to next examination;
- to identify the aggressor and the traumatic agent by the meticulous research of each element;
- to assess the circumstances of the crime (event), the aggressor's and victim's movements;

The doctor's (medico-legal or another) tasks at the scene of death are the following:

- positive diagnosis of death;
- assessment of the postmortem interval (time of death);
- assistance (consultation) to the police officer in correct cadaver examination;
- consultation in discovering, collection, packing, and sending the biological samples (blood, hair, sperm, etc.) to laboratory for further examination;
- relating the preliminary thought about the nature, mechanism, oldness of injuries, about traumatic objects, and other medico-biological tasks;
- consulting the police officer on fulfilling the ordinance or request of the forensic examination of the cadaver, evidences, biological samples and on correct formulation the questions for forensic investigation.

The first and main responsibility of the doctor at the scene of death is to establish the real death (chapter 3). If the person is alive the medical care must provide and should be transported to a medical institution.

As a rule, the death is established before the arrival of the examination group.

While examining the cadaver and the objects around it the doctor must keep to a scheme and sequence of describing:

- location, position and attitude of the corpse;
- objects on the body and around it;
- clothes and footwear on the cadaver;
- general data about corpse;
- cadaverous changes;
- supravital reactions;

- anatomical peculiarities and corporal lesions;
- lodge of the cadaver;
- negative circumstances.

**Location** means the place where the cadaver was found (in a forest, on the left or right bank of a river, in a park or a house, on a street or bridge, etc.). It must be noted the name of the city, street, house, area, etc.

**Position** is the relation of the cadaver to the immovable objects (inside – door, window or outside – street, tree, building). It is noted the corpse position in relation to the surrounding objects, and the distance between them. For example: „The body is lying on the floor of the living room. The head is facing the window, 50 cm of it, and the feet are directed to the entrance.”

**Attitude** shows the position of different anatomical parts of the body. For example (continuation): „The body is face up, with the head tilted to the right. The upper limbs are stretched and distanced from the trunk. The lower members are straddled out and the knee joints are bent.” Some attitudes are characteristic for certain kinds of death: the „embryonic” attitude - death due to hypothermia, „boxer on guard” – death caused by high temperature action.

Next examine and describe all the **objects** on the body and its immediate vicinity. First inspect the objects that could be used to produce injuries (a gun, an ax or a hammer, a ligature around the neck, etc.). Some of them can be found even stuck in the body (a knife) and its extraction is strictly prohibited. Also, do not remove the ligature from the neck.

Furthermore inspect the stains of blood, urine, vomitus near the body, indicating their location in relation to the anatomical parts of the body, their color, shape, size and other specific features.

All important objects discovered near or on the cadaver are collected and packed after investigation and send to the laboratories by police officer.

**Clothing and footwear** are described from the first layers (kind, color, fabric quality, degree of wear, damages, content of pockets (objects, medicines, medical prescriptions). Examine all the specific traces on clothes, which can be removed away or may disappear from them during transportation to the morgue. It is not recommended to undress the body at the death scene.

**General information** about corpses includes the anatomical and constitutional appearances: sex, age (in appearance), height, constitution,

nutrition, skin color and other signs. The unidentified bodies are described in more detailed.

**Cadaverous changes** (chapter 2) help us to establish: the fact and time of death, the first position of the cadaver and if it was changed, the possible cause of death, the environment conditions, etc. – a necessary information immediately after discovering the cadaver.

At the death scene it is necessary to indicate the time of checking the cadaverous changes (date, time), otherwise it will make it difficult to further estimate the time of death. If it is possible, research early cadaverous changes in dynamics (hour by hour). This process can help in determining the time of death.

**Supravital reactions** and early cadaverous changes serve as a main source of information for estimating the time of death in a short time after decease. (chapter 3).

All **anatomical and lesional features** are described in craniocaudal order. List the constitutional and anatomical peculiarities of the head, hair, eye, nose, neck, trunk, limbs etc.

While describing the corporal injuries keep the following scheme:

- localization
- kind of injury (abrasion, bruise, laceration, cut wound)
- shape (in comparison with geometrical figures or others)
- dimensions
- morphological appearance (margins, ends, walls, surface)
- adjacent tissue

At the scene of death injuries are described in an accessible style. A more detailed examination will take place in the morgue. Also, it is not recommended to wash the blood from injuries, to remove the hair or others.

Note that it's forbidden to change the initial appearance of lesions, to introduce objects into wounds, or to extract them from the penetrating injury, etc. It is permitted only to collect objects which are separated from the body, in order not to lose them during the corpse's transportation to the morgue.

**Lodge of the corpse** is the place where the cadaver was lying and is examined after removing it. Specify the nature of the lodge (bed, soil, snow, etc.), corpse imprint, specific impurities, stains of blood, etc., which can elucidate some aspects of circumstances, of causing the injury, of occurring the death, etc. For example: if the cadaver is lying on the

grass or other vegetation, the time of being on the ground can be established on base of changing the grass color, the presence of insects or larva, etc.

**Negative circumstances** mean the lack of those marks, stains, signs, objects that should necessarily be present on the death scene or there are traces of inadequate circumstances, based on concrete conditions of the event. For example: absence of blood near the corpse with large and deep wounds; no cloths damages on cadaver with multiple wounds on the trunk; false designed places.

All information from the death scene is recorded in the protocol of death scene investigation.

## CADAVEROUS CHANGES

### The main purposes and matters

To know:

- ✓ the classification of the cadaverous changes
- ✓ the generalities and forensic importance of the early cadaverous changes
- ✓ the generalities and forensic importance of the belated cadaverous changes
- ✓ the conditions that influence the development of cadaverous changes

To be able to:

- ✓ examine the early cadaverous changes
- ✓ examine the belated cadaverous changes

### Didactic material

- ✓ this guideline
- ✓ lectures
- ✓ other didactic material (tests, situational problems, copies of autopsy reports and protocols of death scene investigation)
- ✓ cadavers (thanatological department)

### Methodic aids

1. Organizational issues
2. Quiz
3. Individual work
4. Solving problems
5. Checking the final level of knowledge
6. Summary and home tasks

### The classification of cadaverous changes

The postmortem changes are divided according to their time of occurrence in three main groups:

1. Early cadaverous changes (cooling, dehydration, livor and rigor mortis, autolysis).
2. Belated cadaverous changes:
  - a) destructive (putrefaction);
  - b) conservative or preserving (mummification, lignification, saponification, congelation, petrification).

3. Destruction of the corpse by animals (insects, fish, birds, mammals).

### **Early cadaverous changes**

**Algor mortis** (cooling) is the reduction of the body temperature after death. During life, our metabolism holds the core body temperature constant at about 36.6°C. In the dead body all metabolism processes stop, including energy production. Uncompensated release of heat to environment medium leads to the cooling of the body. The body progressively loses temperature until it equilibrates with its environment.

Cooling depends on several factors that can be divided into:

1. External
  - ambient temperature
  - humidity
  - movement of air
  - clothing and their character
  - medium of the corpse finding (immersion in water, at air)
2. Internal or individual
  - thickness of fat tissue (body mass)
  - age
  - cause of death (in alcohol or arsenic intoxication, abundant bleeding – the temperature decrease faster, while in diseases with high fever – slower)

**Dehydration** develops due to evaporation of water from tissues, which is a physiological process in life, and is always compensated. After death the balance goes awry.

Dehydration takes place mainly through evaporation, but can be caused by contact, as well. The fine and permanently wet structures of the skin and body (lips, sclera, and genitals) lose water faster. The signs of dehydration are brown-parchment spots on the skin (scrotum, lips), and triangular yellow or brown spots over the sclera of open eyes (L'Arche spots).

The dehydration depends on environmental conditions: temperature, ventilation, as well as individual features: nutrition, degree of dehydration, clothes.

**Livor mortis** (postmortem hypostasis, lividity) is the gravitational settling of blood into lowest parts of the body due to cardiac arrest and passive expansion of blood vessels. Its morphological appearance is changing the skin color of underlying parts into violaceous (red-blue, lavender). The teguments of highest areas become pale and this

phenomenon is called **pallor mortis**. The lividity is not present on compression regions. For example: if the cadaver is lying face up, the pallor mortis is localized on anterior parts of the body and the livor mortis are placed on posterior ones, and the compression zones (if the cadaver is lying on flat surfaces) are: scapular, buttocks, and gastrocnemii regions.

The degree of manifestation of cadaverous lividity depends on blood condition (fluid or coagulated) and volume. The abundant and extended postmortem hypostasis occurs in the mechanical asphyxia or other rapid death, when blood is liquid. In long agony (slow death) blood forms clots (red or red and white) and the lividity is less expressed. If the death was preceded by an abundant bleeding, the cadaverous hypostasis also is weak.

The color of livor mortis depends on the color of blood and this fact can be used to determine the probable cause of death in intoxication with carboxi- and methemoglobin substances.

After death increases the vascular permeability, the blood changes its rheological and osmotic properties, the blood autolysis starts, and the blood viscosity gradually increases, which permits us to differentiate three stages in lividity development: **hypostasis**, **stasis**, and **imbibition**.

*Hypostasis* is the initial stage of the livor mortis when the dilation of capillaries occurs and filling them with blood.

In this period of time the blood is less changed, it doesn't pass the vessels walls, and when pressed on the area of lividity (by finger or dynamometer) the livor color disappears (the blood is forced out of vessels).

If in hypostasis the position of the corpse is changed, the livor mortis will completely move to new areas (lower parts).

In *stasis* filling the vessels with blood is ended and autolysis of erythrocytes starts. The red colored plasma partly diffuses and impregnates the surrounding soft tissues.

The lividity color doesn't disappear from the compressed regions, but becomes pale. If you change the position of the corpse, the livor mortis will occur in the new lower parts of the body, but will not completely disappear from its first position.

The third stage of livor mortis - *imbibition* is the last one, when the liquid compound of lymph, interstitial fluid and leaked from blood vessels plasma and products of hemolysis, imbues the soft tissue and the skin. Lividity doesn't change the color on pressure in this period. If the position of the corpse is changed, the lividity doesn't move.

During the examination of livor mortis the postmortem and intravital compression zones should not be confused. For example, the tie constricts the neck as a band and it looks like a ligature mark.

Also, it is necessary to differentiate a bruise from the livor mortis. A bruise surface rises a little bit above the general surface of the skin. In comparison with livor mortis the bruise color does not change on pressure. A cross-section of soft tissue is most informative and if it is a bruise the hemorrhages and blood clots will be clearly visible.

**Rigor mortis** is a postmortem stiffness of muscles caused by chemical changes in them after death. Immediately after death the muscles relax and become flaccid, but after some hours they contract and passive movements of the joints are limited.

The maximal rigidity of the muscles is established at the end of the first day. As a result of autolysis the muscle contraction gradually disappears.

The development of muscle rigidity is influenced by external and internal factors. The high temperature accelerates the development and resolution of rigidity while the low one decreases these processes. If the death is preceded by convulsion (mechanical asphyxia, intoxication with convulsive substances), the rigidity will occur faster.

Rigor mortis may be weak or even absent in poisoning with hemolytic substances, some mushrooms, narcotics, on malnutrition, in sepsis, etc.

**Autolysis** (self-digestion) is the destruction of biological objects by their own enzymes. Its intensity depends on the saturation of tissues by enzymes, environment temperature, tissue acidosis, etc. Thus, the autolysis is faster in pancreas, adrenal glands, spleen, stomach, and liver. The high temperature and tissue acidosis also speed up the development of autolysis.

Due to autolysis the organs soften, their structure is altered; they lose shine and turgor, become lusterless, flaccid.

The medico-legal importance of early cadaverous changes is to determine:

- fact of death (chapter 3)
- time of death (ibid.)
- probable cause of death judging by its color and intensity (e.g. intoxication)
- tempo of death installation

713793

Universitatea de Stat de  
Medicină și Farmacie  
«Nicolae Testemițanu»

Biblioteca Științifică Medicală



- initial position of the body (e.g. hanging, face up or down)
- if the initial position of the body was changed
- relief of corpse lodge

### **Belated cadaverous changes**

**Putrefaction** (decomposition) is a complex process that consists in disintegration of proteins and tissues by aerobic and anaerobic microorganisms.

The conditions of putrefaction are: temperature, aeration and humidity.

The optimal *temperature* of decomposition is 30-40<sup>0</sup>C. If the temperature is over 60 degrees it stops the microbial activity and the autolysis became more intense. The low temperature, especially below zero, also inhibits the microbial activity. In such conditions (subzero) the corpse can be preserved a long time (e.g. detecting mammoth 44,000 years old).

*Humidity* also must be optimal. If the humidity is too high (e.g. water) the putrefaction slowly evolves and the saponification can develop. The low humidity leads to dehydration and mummification of corpses.

*Aeration*. The lack of oxygen slows down the putrefaction. For example, the decomposition develops rapidly in the air, slowly in the water and even slower in the soil. In the absence of oxygen the anaerobic microbial action, with gas formation occurs frequently.

Depending on the conditions of putrefaction it may be of three types:

- a) dry, when there is less liquid and low humidity (massive bleeding, cachexia);
- b) moist: the presence of excessive water (e.g. edema);
- c) gaseous: infectious (bacterial) disease, anaerobic putrefaction (e.g. sepsis, drowning (water and microbes pass through the skin in the soft tissue)).

Signs of putrefaction:

1. *green-grey discoloration of the skin*. The green discoloration typically begins on the abdomen (iliac regions, initially right) and then spreads to the rest of the body. The green-grey color is conditioned by the iron sulfide and sulfhemoglobin due to diffusion of the hydrogen sulfide from the intestines to the abdominal wall and its combination with the decomposed blood.
2. *venous net* is a green-gray discoloration of superficial veins because the putrefying blood inside forms iron sulfide and sulfhemoglobin. By the end it looks like a green-grey net (venous).

3. *vesicles of putrefaction* filled with liquid or gas. Collections of liquid or gas are formed into the putrefied skin (between epidermis and derma). The liquid is dirty-reddish, with less proteins.
4. *cadaveric emphysema* due to postmortem gas formation by microbes (methane, hydrogen sulfide, phosphorus and so on). The face, lips, breasts, abdomen, and scrotum are especially swollen. The body becomes larger in size. Gases can develop pressures up to 2 atmospheres. The emphysema leads to such phenomena as: flotation of the cadaver being in water, postmortem vomiting, defecation, urination, birth, etc.
5. *fetid smell*. The liberated gases such as hydrogen sulfide, methyl mercaptan and ethyl mercaptan possess characteristic foul odors.

The pathogen agents in the body are subject to the general laws of decomposition, and in connection with that cadavers are not contagious.

**Mummification** is a complete dehydration of the tissues due to dry air, high temperature and good ventilation. When all the water is lost, the body becomes near 10 times easier. Mummification may take place in the air, ventilated rooms, in the dry, sandy soils, etc.

The cadaver's skin becomes thick, like parchment, and dark-brown color. Internal organs also are completely desiccated, dry, shapeless, and smaller. Mummified corpses are conserved for a long time, but under different conditions, such as high humidity, influence of insects or animals, may be destroyed.

The mummification keeps macro- and microscopic traumatic and non-traumatic changes for a long time.

**Saponification** (adipocere) develops in humid conditions with minimum access or lack of oxygen. The process is a result of the fat tissue decomposition, with subsequent formation of glycerol and fatty acids: oleic, palmitic and stearic. The glycerin is washed from tissue, because it is hydrosoluble, but fatty acids form salts with alkaline minerals – a process of soap-making.

As result a greyish or grey-yellowish waxy substance is formed (less soluble salts). High-fat tissues become hard and keep injuries on them for a long time.

**Lignification** (tanning) occurs in acid medium rich in tannic and humic acids (e.g. swamps). These substances prevent putrefaction, turn the skin and the soft tissue into hard, less elastic, brown-blackish matters,

but the bones became flexible and can easily be cut with a knife, because the minerals are eliminated from them.

**Petrification** (mineralization) is the converting of organic matter into a mineral one due to preservation of the corpse for a long time in high-salted liquid, and at last may be transformed in a „statue“. This phenomenon is found among aquatic animals and has never been described among human.

**Congelation** (freezing) occurs when the cadaver is at a very low temperature – below the freezing point of water or subzero. Bodies can be kept frozen for months in winter, and polar conservation is almost unlimited.

**Destruction of the corpse by animals** can be produced by mammals, birds, reptiles, fishes, crustaceans, insects etc. Fungi, molds, and algae are also involved in the destruction of the cadaver.

As a rule, the wild animals deteriorate the cadaver, but there are cases of domestic animals (cats, dogs or stray dogs) implication in devastation the corpses, as well.

When the body is in the water, its destruction is produced by predatory fishes, crustaceans, leeches and other aquatic fauna representatives.

Most frequent cadavers are destroyed by insects, especially by flies. In some hours after death flies lay eggs around the natural orifices (mouth, nose, eyes) or around the wounds. Short after the larvae appear which gradually destroy the tissues with their enzymes. The information on the life cycle of flies or other insects is indicative for establishing the time of death (chapter 3), known as forensic entomology.

The medico-legal importance of belated cadaverous changes is:

- to determine the time of death (chapter 3)
- preserving the injuries and other anatomical peculiarities of the body (conservative changes)
- to establish the conditions of keeping the body

However, for forensics medicine, destructive cadaverous changes have a negative effect, because they make it difficult to solve some problems of thanatology.

## ESTABLISHMENT OF THE FACT OF DEATH AND TIME SINCE DEATH

### The main purposes and matters

To know:

- ✓ the negative signs of life
- ✓ the positive signs of death
- ✓ the tests of real death ascertainment
- ✓ the signs of post mortem interval assessment

To be able to:

- ✓ establish the positive diagnosis of death
- ✓ do the diagnostic tests of death determination
- ✓ assess the time of death

### Didactic material

- ✓ this guideline
- ✓ lectures
- ✓ other didactic material (tests, situational problems, copies of autopsy reports and protocols of death scene investigation)
- ✓ cadavers (thanatological department)

### Methodic aids

1. Organizational issues
2. Quiz
3. Individual work
4. Solving problems
5. Checking the final level of knowledge
6. Summary and home tasks

### Diagnosis of death

The positive diagnosis of death is an important point for forensic practice and not less important for physicians. It is not difficult to establish the fact of death after 3-4 hours after death and it is problematic to determine it within the first 1-2 hours. Also, in hospitals or in other conditions in which apparatuses are used it is not difficult to conclude the death.

There are two groups of signs of ascertaining the death: *negative signs of life* (orientational) and *positive signs of death* (certain).

Negative signs of life are following:

- lack of consciousness
- passive position of the body
- pale skin
- absence of respiratory movements
- absence of heart contractions and pulse
- lack of response to painful, thermic and odorous stimuli
- absence of reflexes

Negative signs of life have a suggestive value in the diagnosis of death, because these signs may be found in other unconscious states.

Positive signs of death are cadaverous changes – due to nonspecific physical and biochemical processes of the living organism (chapter 2).

Beside the above described signs, you can use some diagnostic methods such as Magnus and Beloglazov.

The Magnus test consists in checking the cessation of peripheral circulation. An unpowerful ligature is applied at the basis of a finger and look for changing the color. If the finger color becomes bluish, it means the peripheral circulation is present and the person is alive.

The Beloglazov test is performed by bilateral compression of the eyeballs. If the person is alive, the pupils will shrink as result of mechanical excitation and contraction of smooth muscles of iris. In the case of dead persons the pupils, due to the loss of innervation, change their shape from round into oval, like cat eyes. This is also called the „cat’s eye test”.

### **Assessment the time of death**

The time of death is determined on the basis of the supravital reactions estimation, early and belated cadaverous changes and biochemical markers research. It is also necessary to perform a dynamic study – at last 2-times study of all phenomena at the scene of death and in the morgue with an interval of 1-2 hours. All the changes, the environmental conditions, the time of examination of the cadaveric phenomena, and other data are described in the smallest details.

It is recommended to use the following signs while setting the time of death:

**Supravital reactions** (intermediary life assessment) represents phenomena manifested by some cells, tissues, organs or parts of the body, after the end of life, during their vitality (intermediary or residual life), and are valuable for establishing the time of death only during the first hours of the postmortem period (till about 12 hours):

1. Beloglazov test is positive in 10-15 minutes.
2. Mechanical excitability of the muscles can be examined by forcefully hitting the tendons or muscles by reflex hammer, back of the knife handle or other object, also by outer part of the palm.
  - a) Tendon reaction (Zsako's phenomenon) is the contraction of the whole muscle due to propagated excitation following a mechanical stimulation of tendons on the special points (fig.1) and can be seen up to 1.5-2.5 hours postmortem.

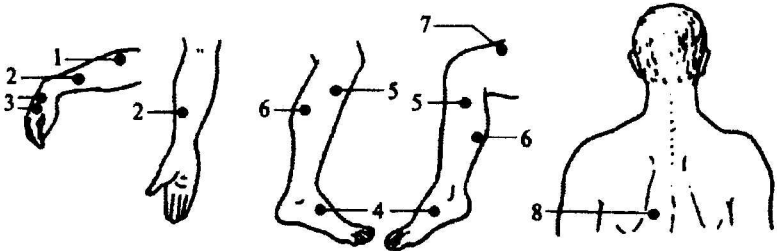


Figure 1. Points of tendon reactions (Zsako, 1916)

- b) Idi muscular contraction is a localized muscular contraction at the point of stimulation. The excitation of biceps muscle has been better examined, therefore the information about it is exposed. The biceps muscle of the arm is struck and a bulge (idiomuscular tumor) or a dent (depression) occurs in the place of attack. The obtained information can be interpreted using *table 1*.

*Table 1*

**Manifestation of the biceps muscle bulge, by V.V. Bilkun, 1986**

Feature of the muscle bulge	Time of death (hours)
Quickly appears, firm, size of 2 - 1.5 cm	1 - 3
Size of 1.5 - 1 cm	3 - 6
Size of 0.5 cm or determined by palpation	6 - 9
A dent in the place of impact	more than 10

3. Electrical excitability of the skeletal muscle is generally investigated on the muscles of the face. This method is less used because it is subjective and requires special apparatus.
4. Pharmacological excitability of the iris muscle. The iris muscle is reactive to electrical, thermal and pharmacological stimulation during

intermediary life. There are a lot of methods, and one of them can be performed by injection of 0.1 ml 1% solution of pilocarpine hydrochloride in the anterior chamber of the eye. The time of constriction of the pupil is recorded (*tab.2*).

*Table 2*

**Estimation of the time of death by papillary behavior at pilocarpine hydrochloride stimulation, by K.I. Khizhnyakova**

<b>Time of death (hours)</b>	<b>Time of pupillary constriction (seconds)</b>
up to 5	3-5
10-14	6-15
till 24	20-30
more than 24	60-120

- Biochemical markers gradually change their concentration and potential after death, which is useful while estimating the time of death. The biochemical methods require laboratory investigation of blood markers (electrolytes such as sodium, potassium, calcium, magnesium, phosphorus, chloride; glucose; lactic acid; urea; etc.), vitreous markers (electrolytes such as sodium, calcium, magnesium, chloride; urea; pH), cerebrospinal fluid markers (electrolytes such as potassium, magnesium, sodium, calcium, phosphorus, chloride), pericardial fluid markers (electrolytes, cholesterol, glucose, lactic acid, enzymes, etc.), muscle markers (creatinine, enzymes), lung markers (surfactant, phospholipids), etc.

**Early cadaverous changes:**

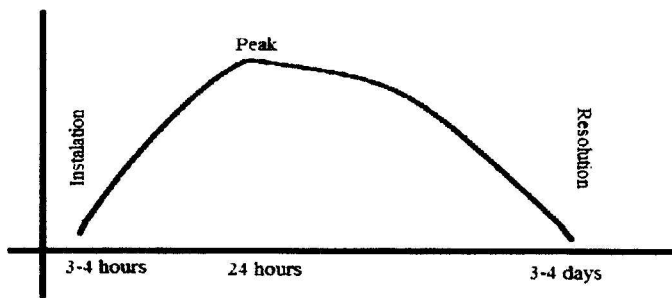
- Dehydration. L'Arche spots occur after 5-6 hours.
- Cooling. If the corpse of an adult person is at 16-18<sup>0</sup>C of environment, the cooling will be near 1<sup>0</sup>C per hour, but this depends on many factors (chapter 2). The uncovered parts of the body (e.g. face, hands) become cold already after 1-2 hours. The body temperature is equaled to the environment by the end of the first daytime.
- Livor mortis installs in 1.5-2 hours after death. Hypostasis lasts 1.5-2 hours till 8-12, stasis – 8-12 – 24-36 hours and imbibition – after 24-36 hours. Lividity is more informative when we check its behavior by the pressure on it (by finger or dynamometer) and its restoration time (*tab.3*).

Table 3

**Estimation of cadaver lividity behavior at finger-pressure  
(Yu.S.Sapozhnikov, A. Hamburg, O.A. Grishchenko)**

Lividity stage	Color after pressure	Color restoration time	Time of death
Hypostasis	disappear	30 sec. - 2 min.	6-8 hours
		2-5 minutes	8-16 hours
Stasis	become pale	5-10 minutes	16-24 hours
		till 20-30 min.	24-36 hours
Imbibition	doesn't hange	---	more than 1.5-2 days

9. Rigor mortis appears in 3-4 hours (*fig.2*). Within 8-14 hours the rigidity is installed in all muscles and after 24 hours it reaches its peak. The complete and independent resolution is found by 3-4 days. The force-destroyed rigor mortis after 10-12 hours does not restore.



**Figure 2.** Graphical representation of rigidity development

**Belated cadaverous changes:**

10. Putrefaction. The first sign of decomposition (green-grey discoloration of the skin in the right iliac region) appears in 2-3 days in ordinary ambient conditions (16-18°C). The venous net is found on the 3<sup>rd</sup> - 4<sup>th</sup> day. All the skin becomes green-grey in 8 - 12 days (*tab.4*). The vesicles of putrefaction and the cadaveric emphysema are present on the second week after death.
11. The first signs of mummification and saponification can be seen from 2 weeks till 2 months. The total mummification or saponification occurs from 6 months to one year.



12. In case of destruction of the corpse by animals it is necessary to use the regularity and principles of insects' (flies, ants, beetles) development. For example, flies start to destroy the cadaver immediately after death, and, in favorable conditions, they can completely overcome the soft tissues of a newborn body in 1.5 - 2 weeks, and the corpse of an adult in 1 - 1.5 months. It is also known that in the ground the soft tissue and fat are eaten in the first 1 - 3 months by sarcophagi, from 2 to 4 months - beetles, up to 8 months - sylphs, and the cartilage and ligaments are destroyed by mites.

*Table 4*

**Estimation of the time of death by means of belated cadaverous changes**

<b>Cadaverous change</b>	<b>Time of death</b>
Green-grey discoloration of the skin	
in the right iliac region	
summer in the open air	around 1 day
at ambient temperature 16 -18°C	2-3 days
in the left iliac region	12 h later than in the right region
of the whole abdomen	3-5 days
of all the skin (no flies)	8-12 days
Venous net of putrefaction	3-4 days
Green-grey discoloration of livor mortis	3-5 days
Evident abdominal distension by putrid gases	4-5 days
Marked cadaveric emphysema	2 <sup>nd</sup> week
The appearance of putrefaction vesicles	2 <sup>nd</sup> week
Destruction of organs and tissues (no flies)	3 months
Skeletonization (preserving ligaments)	
on the ground in the summer	≈ 2 months
on the ground in winter	≈1 year
Fragmented skeletonization (on the ground)	≈1-3 years
Flies:	
presence of oviposition (eggs)	1-3 days
presence of oviposition and larvae	2-3 days
predominance of larvae	3 days - 2.5 weeks
emergence of pupae	more than 2 weeks
emergence of flies	
at 15-20 <sup>0</sup> C	20-30 days.
at 20-25 <sup>0</sup> C	15-20 days.
at 25-30 <sup>0</sup> C	9-15 days.
Start of mummification & saponification	2 weeks till 2 month
Complete mummification & saponification	6 month to 1 year

## POSTMORTEM RECORDS

### The main purposes and matters

To know:

- ✓ the made out documents after autopsy
- ✓ the aim of the forensic autopsy
- ✓ the methodology of the cadaver examination
- ✓ the structure of the „Medical death certificate”
- ✓ the structure of the „Autopsy report”
- ✓ the scheme of „Autopsy report”
- ✓ the principles of making out the forensic diagnosis and conclusions

To be able to:

- ✓ conduct the death certificate
- ✓ perform an autopsy together with the professor
- ✓ take samples during the autopsy for supplemental laboratory studies
- ✓ analyze and construe the data obtained during autopsy
- ✓ write an „Autopsy report”
- ✓ draw a medico-legal diagnosis and conclusion

### Didactic material

- ✓ this guideline
- ✓ lectures
- ✓ other didactic material (tests, situational problems, copies of autopsy reports, death certificates)
- ✓ cadavers (thanatological department)

### Methodic aids

1. Organizational issues
2. Quiz
3. Individual work
4. Solving problems
5. Checking the final level of knowledge
6. Summary and home tasks

After autopsy the forensic pathologist composes two main documents: the „death certificate” or „medical death certificate” and the „autopsy report”.

## **Death certificate**

The death certificate is a standard form (blank) which includes personal data of the dead, time, cause and manner of death.

The most important purpose of the death certificate is to establish the fact of death of a specific person. The largest part of the death certificate is therefore devoted to identification of the decedent by his/her full name, date of birth, place of birth, and address. The identifying data are provided by the forensic pathologist based on legal documents.

The findings at autopsy help us to complete the medical part of the certificate: time and cause of death. There are some other data required in this certificate like manner of death, and circumstances of accidental deaths.

The collected information serves to the needs of public health officers and medical statistics.

The most important of these data is the medical cause of death.

The cause of death is recorded in some sections as follows:

### *Part I*

- section „a” – the direct cause of death
- section „b” – antecedent causes (intermediate morbid states), which preceded the direct cause (from point „a”), and led appearance and progression to death;

- section „c” – the initial disease, trauma or violence, which resulted in mandatory sequence states inscribed under „b” and „a”, and determined the cause of death

*Part II* includes other existing morbid conditions (diseases) which have influenced negatively the outcome of the disease or trauma and have contributed to the installation of death, but without direct causal relationship to them.

The main disease or trauma which led to the next phenomena (points „a” and „b”) must be noted in section „c”, and when it is sufficient to explain the cause of death the points „a” and „b” are not mandatory to be filled in.

If any medical files (the person was before death in hospital), the cause of death and medico-legal diagnosis are noted in them.

## Autopsy report

The autopsy report is a written record with the observations made during the examinations conducted by the pathologist, and interpretation of the findings at necropsy. This record is often supported by file notes, sketches, and photographs.

According to art.151 of P.P.C. after performing the necessary investigations, the expert prepares a written report, signs and stamps it.

Also in this article it is specified that the expert must indicate in his report: when, where and who performed the expertise (name, surname, education, specialty, title, scientific degree, and function), that the expert was informed about the criminal liability for the knowingly presenting false conclusions, the act ordering the expertise, people who attended the expertise, the materials used by the expert investigations, conducting expertise operations, methods, software and hardware used; questions to the expert, and the conclusions.

Based on the requirements of P.P.C. the report is structured in three parts: *introductory*, *descriptive* and *final*.

*The introductory part* includes: when, where and who (name and surname of the expert, function, scientific degree and title, work experience) performed the expertise, on what basis the expertise was executed, showing the department or organization that has ordered the expertise, attended people, used material, and the questions that have been addressed. The introductory part closes up with the statement that the expert's obligations and rights stipulated by art. 88 P.P.C. R.M. have been explained and that the expert had been warned about the criminal responsibility in accordance with the art. 312 of P.C. R.M.

*The descriptive part* includes all the data found during autopsy (external and internal examination). This part starts at first with circumstances of the case which are collected from request or order papers, death scene, etc.

Next extract necessary information from medical files, if any, and after then the detailed description of the medico-legal examination (external and internal) follows. The end of the descriptive content bears the performed during autopsy the preventive tests, supplemental laboratory studies, methods etc.

Forensic diagnosis concludes the descriptive part.

*The final part* consists of answers to questions of the expertise and is also called “conclusions”. Each response to questions must be apparent from the elucidated data in the descriptive part.

The expert's conclusions must be prepared based on the following requirements:

- a) objective reasons – to be confirmed by objective data found during the investigations
- b) the scientific argumentation – to be developed under the most modern theories and methods of medical and biological researches
- c) exhaustive arguments – the foundation of the conclusions must be comprehensive and profound and their interpretation does not admit ambiguity
- d) complete conclusions – to be full, consecutive and clear
- e) within the limits – should not exceed the limits of the expert’s competence
- f) accessible – to be understandable to people who lack medical education.

### **Scheme of Forensic Autopsy Report**

As described in the first part of the report there is a lot of personal information which is used by justice organs for checking the expert’s professionalism.

Because this guide is predestined to students you have to keep the following scheme of autopsy report:

The first page should look like a letterhead (*fig. 3*)

STATE UNIVERSITY OF MEDICINE AND PHARMACY  
„NICOLAE TESTEMITANU” OF THE REPUBLIC OF MOLDOVA

DEPARTMENT OF FORENSIC MEDICINE

Chair of the department  
PhD Andrei Pădure

Lecturer:  
(name, surname of the lecturer)

## **Forensic Autopsy Report**

Name of deceased:  
(name, surname, age)

Executed by:  
(name, surname of the student)  
(group)

Chişinău 2012

**Figure 3.** The letterhead (sample) of the Forensic Autopsy Report

The aim of each expertise is to solve the question asked by the police officer or other juridical organs. Therefore next page starts with questions from the writing request:

### THE QUESTIONS PRESENTED FOR SOLVING

1. What is the cause of death?
2. What is the time of death?
3. If there are any injuries on the body, which are their localization, mechanisms of formation, time of producing, causal relationship with the death, and the injury severity degree?
4. What was the degree of drunkenness before death?

### CIRCUMSTANCES OF THE CASE

Important events and information about the case is exposed shortly.

### DATA FROM MEDICAL FILES

In this section you have to extract the necessary data from the medical records (if any) as follows:

From the clinical medical record nr. \_\_\_\_\_ of the hospital \_\_\_\_\_ it is found that the citizen \_\_\_\_\_ on \_\_\_\_\_ was hospitalized with the diagnosis „\_\_\_\_\_”. Then write history of the case, blames, anamnesis, life and medical history, and objective data at hospitalization. The clinical course of the disease or trauma, the treatment, and additional investigations are noted depending on the case. At the end of the medical data must be inscribed the state before death, the time of death, and final clinical diagnosis.

### EXTERNAL EXAMINATION:

1. Description of the clothing starting with the first layers (kind, color, fabric quality, degree of wear, damages, contents of pockets, traces of heterogeneous substances (dust, mud, etc.), stains (e.g.: blood-like), location, shape and dimensions.
2. Sex, age according to appearance, height (cm), constitution, nutrition (good, excessive, reduced, emaciated).
3. Skin: general color (pale, pale-gray, pale-pink, etc.), elasticity, wrinkles, maceration, „goose-flesh”, impurities - stains of blood, vomitus, lubricants (in road trauma), sand, ground, etc..
4. Algor mortis (cadaverous cooling) – on palpation (warm, cold) of the uncovered and covered with clothes areas, etc. in the armpits. Corpse temperature (rectal, intrahepatic, etc.).
5. Livor mortis (cadaverous lividity): location, expansion (diffuse, insular), color and its intensity. The presence of petechiae on livor

background. Modification of livor color by pressure (disappears, becomes pale) and time needed to restore full color. Cadaverous lividity should be differentiated from hemorrhages (bruise) by section of the skin.

6. Rigor mortis (cadaverous rigidity). Stiffness of muscles: try to do extension and flexion movements of the upper and lower limbs. Try to close or open the mouth.
7. Belated cadaverous changes (if any): green-grey putrefaction spots, putrefaction vesicles, cadaverous emphysema, vascular net, etc..
8. Head (form), hair (length, color, shape). The presence of skin injuries (abrasions, bruises, lacerations).
9. Face - skin color, presence of edema and ecchymoses.
10. Eyes - open, closed, the color of palpebral conjunctiva, the presence of bruises, the cornea - luster; pupils - shape, size; sclera - the color, the presence of L'Arche' spots.
11. Nose - the integrity of cartilages and bones on palpation, nose content, elimination.
12. Mouth - open, closed, presence of trickles, foam at the mouth, the presence of foreign objects (e.g. gag) in the mouth.
13. Teeth - examination and evaluation of dental evidence, full dental formula (natural, dentures). Tongue position in relation to teeth. Appearance and color of the lips and gingival mucosa. Damages to teeth, gums, alveolar apophysis, the presence or absence of hemorrhages.
14. Ears - auricula (form, color, lesions), the external acoustic meatus (eliminations, impurities, etc.).
15. Neck - long or short, form, mobility, the presence or absence of injuries (bruises, excoriation, ligature mark, etc.).
16. Thorax - the shape (cylindrical, conical, flat, etc.), symmetric or asymmetric conformation, ribs integrity on palpation.
17. Mammary glands - size, shape, consistence, color and appearance of mammary areola, nipple shape (conical, cylindrical, inversion), the presence and character of nipple discharges (eliminations).
18. Abdomen - shape (distended, flat), color, elasticity of the anterior abdominal wall, the presence of hernias (of the linea alba, umbilical, inguinal), dimensions, features, the presence of stretch marks (color, size, location).
19. External genital organs - the hairs of the pubic region (degree, type - male, female), correctness of genitalia development, the presence of



- injuries. The male corpses - elimination of the urethra (semen, urine, pus), location of the testes: into the scrotum, inguinal canal, at the inguinal ring), the presence of parchment-like spots on scrotum. The female bodies – development of genital labia, color of vaginal vestibule mucosa, hymen features, vaginal content, the character and color of eliminations from the genital tract.
20. Anus - open, closed, hemorrhoids, skin around the anus - color, clean or dirty (blood, fecal, etc.).
  21. Back – vertebral column: deformation, integrity on palpation, hemorrhages of the soft tissue (at section).
  22. Gluteal and sacral region - eschars, injuries, sacral spina bifida etc.
  23. Upper and lower limbs - correct development, bone integrity, fingers shape, nails (integrity, length), skin changes on the hands and feet: maceration, electrical mark, pigmentation, trophic ulcers, edema, varicose veins.
  24. Hemorrhages into buttocks, posterior muscles of legs (in case of mechanical trauma – road trauma, precipitation, etc.).
  25. At the end of external examination must be noted that other injuries, in addition to those described above, have not been identified.

#### INTERNAL EXAMINATION

26. Head – color of the soft tissue, its moisture; the presence, size and color of hemorrhages. Temporal muscles, integrity, the presence of hemorrhages.
27. Bones of the skull vault and base - integrity, their thickness on sawing line (frontal and occipital bone) and on fracture line (in case of fracture). Skull fractures and cracks (if any) - anatomical location, shape, dimensions and other features.
28. Dura mater - integrity, color, tension, prolapse, the fullness of the blood vessels, the content of longitudinal and other sinuses, blood condition in their lumen (fluid, clots). Epi- or subdural hemorrhage, if any.
29. Arachnoid and pia mater - transparency, moisture, sleek, thickness, fullness of blood vessels, opacity along the vessels, their appearance at the base of brain, glandulae Pacchioni; (arachnoid villi), the presence and location of hemorrhages.
30. Brain - weight, appearance of convolutions, the depth of sulci, the consistency of brain tissue. Vessels of brain base - thickness and elasticity of their walls, the presence of atheromatous plates, location,

color and size. The content of cerebral ventricles, CSF color, its quantity, vascular plexuses - color, plethora. White and gray matter at section (architectural design - clear limits between the white and gray matter, sleek, wetness), the degree of blood filling. Symmetry of subcortical nuclei, brain ventricles, cerebellar tissue features, the pons Varoli and spinal bulb. Focal changes of brain tissue - crushed, tumors, softening, hemorrhages (location, size, appearance, color), and the state of adjacent tissues.

31. Hypophysis - shape, size, color, consistency.
32. Paranasal sinuses (maxillary, frontal, ethmoid, sphenoid), the content of the middle ear cavity.
33. Soft tissues of the neck, thorax and abdomen: color, moisture, the presence or absence of hemorrhages, the fullness of neck blood vessels, carotid intima appearance (transverse rupture, etc.).
34. Thickness of subcutaneous fat tissue on the anterior abdominal wall at the umbilicus.
35. Muscles, development level, color, sleek.
36. The level of diaphragm vault compared to ribs ridges, (in the lower and lateral regions).
37. Abdominal cavity, peritoneum - the humidity, color, sleek, transparency, the presence of traumatic or pathological changes, abdominal content - quantity, color, the condition of intestines (bloated, collapsed), serous membrane, its color, status of vermiform appendix, mesenteric vessels. Status of lymph nodes on palpation and section.
38. Pleural cavities, their content (character and quantity of liquid), adhesions (fibrinous, fibrous), parietal pleura integrity, color and its transparency.
39. Topographic location of internal organs (correct, incorrect). The absence of organs (congenital or postoperative).
40. Tongue, color of mucosa, deposits, the character of lingual papillae, dental marks, muscles and hemorrhages in them.
41. Palatine tonsils, size, external surface, consistency at palpation, structural aspect at section, the presence of pus.
42. Entrance of the larynx and esophagus (free or not), mucosal appearance.
43. Hyoid bone and laryngeal cartilages, integrity, hemorrhage into surrounding tissues, especially around the fractures, if any.

44. Thyroid gland - size, consistency, architectural design, tissue color at section, the presence of tumors, follicular hypertrophy.
45. Thymus - size, shape, mass, consistency, tissue color at section.
46. Esophagus, its content, mucosa color, the condition of longitudinal folds, ulcers on the mucosa.
47. Airways - permeability, content and appearance, color of laryngeal, tracheal, and bronchial mucosa, signs of inflammation, the presence of heterogeneous objects and other features.
48. Pulmonary lymph nodes, size, consistency, structural aspect.
49. Lungs - consistency (crepitation, induration), visceral pleura status (color, petechial bleeding, transparency), volume (decreased, increased), structure of the sectioned tissue (color, presence of pus, cavities, tumors), eliminations of the sectioned bronchial lumen (bloody, foamy fluid, pus, mucus, gastric content).
50. Pericardium, tensioned or not, content (pericardial fluid, blood, their quantity and feature), the presence of adhesions.
51. Heart - size, weight, fat deposits on the external surface (their thickness), petechial bleeding under epicardium, consistency of heart. The content of cardiac cavities (fluid blood, clots, parietal thrombus), the status of heart valves and large vessels (smooth, thick, deformed), the papillary muscles and tendinous chords, the aspect of endocardium (color, thickness, the presence of hemorrhagic petechiae, blood clots coherent to it, etc.). Muscle thickness in the left and right ventricle, the structural aspect of sectioned myocardium (color, the presence and quantity of conjunctive tissue, sclerosis). The state of the coronary arteries (reduced or dilated lumen, the presence or absence of atheromatous plates on intima).
52. Aorta - its width above the valves, color of intima, the presence and character of atheromatous plaques (petrified, with ulcers), the presence and location of diverticula, coarctation of the aorta, aneurysms.
53. Spleen - size, weight, consistency, capsule (wrinkled, smooth, thickened), the appearance of the sectioned pulp (color, degree of development of trabeculae), the nature and volume of the lien scraper.
54. Pancreas - size, consistency, appearance, the architecture of sectioned tissue, the presence of hemorrhages (diffuse, focal, clots).
55. Liver - size (length, width of the right and left lobes, height), weight, shape, surface (smooth, irregular, micronodular, tuberosus), the character

- of anterior border, capsule appearance, color and section surface, architectural design (lobular, granular, nodular etc.) scraper character.
56. Gall bladder - size, permeability of bile ducts, quantity, color and density of biliary calculi, wall thickness, the appearance and color of mucosa.
  57. Stomach - content (quantity, consistency, odor, color, character of undigested food), mucosa (color, thickness, plicas, the presence of ulcerations, scars, hemorrhages), gastric vessels.
  58. Small intestine - content, mucosa appearance (color, circular folds status, the presence of swelling, erosion, bleeding, etc.), intestinal glands (Brunner's glands, solitary lymphatic nodules, Peyer's patches).
  59. Large intestine - content, mucosa appearance (color, surface, solitary lymphatic nodules, the presence of bleeding, erosions, tumors).
  60. Adrenals - shape, size, weight, consistency, surface, cortical and medullary layers, color on section, delimitation between them.
  61. Kidneys - size (for each), weight, appearance, decapsulation (easy or not), surface after decapsulation (smooth, wrinkled, color), consistency, color and appearance of sectioned tissue, demarcation of cortical and medullary layers, their thickness. The content of calyces and pelvises (stones, sand, crystals), mucosa color.
  62. Ureters - permeability (presence of stones), lumen size, mucosa status.
  63. Urinary bladder - the volume of urine (in ml.), its color and transparency, the appearance of mucosa.
  64. Prostate - shape, size, consistency, appearance at section.
  65. Testes - size, consistency, structural features of the parenchyma and epididymis.
  66. Vagina - mucosa color, accentuation of folds, the presence and appearance of existing lesions.
  67. Uterus - dimensions (length, width and thickness at the fundus), the form of uterus and the external orifice of the uterus (condition of the cervical mucus), cervical lips and cervical canal (dilated or not), the contents of the uterine cavity, the color of uterine and cervix mucosa. In the case of pregnancy the conception product is described - size, appearance, place of implantation, amniotic membranes. Fallopian tubes, their permeability, the condition of the broad ligaments. Uterus weight.
  68. Ovaries - size, shape, appearance and color at section, the corpus luteum of pregnancy and menstrual - recent and old.
  69. Integrity of ribs, pelvic bones and other trunk and limb bones.

70. Spinal column - its integrity, quantity, color and transparency of cerebrospinal fluid, the presence of pus. The status of spine membranes, the consistency and architectural design of the spinal cord section, the presence of haemorrhages, lesions, pathological changes.
71. The presence of specific odor from cavities and internal organs.
72. Remarks:
- In this item are included following:
- Accidental injuries produced at necropsy (e.g. fractures, supplemental cuts of skin).
  - Data of preliminary tests (technique and results) performed during autopsy in order to establish: air embolism of heart, fat embolism of lungs, pneumothorax, estimation of extrauterine life, etc.
  - The list of organs (part, pieces of them) sent to laboratory investigations (toxicological, histopathological, biological, bacteriological, radiological etc.) and questions that should be solved by the respective specialists (toxicologists, histopathologist, biologists, etc.).
  - The list of organs and tissues collected for transplantation, anatomical preparations, scientific investigation and to whom they were sent.
  - Description of the forensic evidences presented along with the cadaver (hanging or strangulation ligature, traumatic objects, etc.).
- (Signature and stamp of the expert (student)).

The results of laboratory investigations.

Record all the results of supplemental laboratory studies: histological, toxicological, biological, medico-criminalistic, etc., including: number of the examination report, date, where and by who was performed the research.

### **Medico-legal diagnosis**

Medico-legal diagnosis (forensic, pathological) is a summary of changes (lesions) found during autopsy and recorded in the descriptive part of the „Autopsy Report”. All macroscopic findings must be arranged by importance, using nosological and etiopathogenic principles. Initially it is indicated the main lesion or pathology (the basic morphological manifestations), and its complications, which served as the direct cause of death.

Then are noted the coexisting and preexisting injuries or/and diseases.

Therefore, the structure of a medico-legal diagnosis is:

**Principal (main) disease (trauma)** - causes the death itself or by its direct complication.

If there is more than just one, they may be: *concurrent* and *associated*, and must be ordered anatomically (from head to legs) or according to current regulations.

*Concurrent* diseases or traumas are when each of them can cause the death itself.

*Associated* are diseases or traumas which can't be the cause of the death itself but only in case of their combination.

**Complications** are effects or pathological processes which are related etiologically and pathogenically to the principal disease.

**Preexisting** (background) disease or trauma - influences pathogenically the principal disease or trauma, but not etiologically.

**Coexisting** disease or trauma - exists simultaneously with the principal one and has no impact to it.

The forensic pathologist uses medical terms in diagnosis and it is not necessary to simplify them, because the medico-legal diagnosis is not predestined to the police or other official organs.

### **Conclusions:**

The conclusions start with listing of all available data (necropsy, preliminary tests, laboratory investigations, etc.) as follows:

Based on the autopsy data, the medical files (if any), the circumstances of the case, the results of laboratory investigations and in accordance with the exposed questions the conclusion is:

1. The cause of death – trauma, disease or direct complication served as cause of death. In a short form indicate the basic signs of the principal disease (trauma) and its complications.

There are two ways to explanate the cause of death: from the principal disease to the complications or from the complications to the principal disease, as follows:

„The cause of death served the stab wound of the chest with aortic injury, complicated by a subsequent abundant bleeding and generalized anemia”, or

„The cause of death served the abundant bleeding and generalized anemia as complications of the stab wound of the chest with aortic injury”.

2. The time of death (based on objective data of rigor, livor and algor mortis, environment conditions, data from the death scene, etc.). The expert indicates only the established interval of time and doesn't record exact date and time:

„Death occurred 10-12 hours ago, which is confirmed by...”

3. The localization of injuries (if any), their mechanisms of formation, the time they were produced, causal relationship with death, and degree of injury severity.

4. The degree of drunkenness before death, based on toxicological investigation of blood.

5. Other questions of medico-legal competence.

(Signature and stamp of the expert (student)).

## BIBLIOGRAPHY

**Baciu Gh. și Ungurean S.** Examinarea medico-legală a cadavrului. - Chișinău: CEP Medicina, 1996. - 104 p.

**Dix Jay and Graham M. A.** Time of death, decomposition, and identification: an atlas. - CRC Press, 2000. - 112 p.

**Payne-James J., Busuttill A. and Smock W.** Forensic Medicine: Clinical and Pathological Aspects. - Greenwich Medical Media, 2002. - 840 p.

**Ungurean S.** Medicina Legală. - Chișinău: Știința, 2003. - 414 p.

**Громов А. П.** Практикум по судебной медицине. - Москва: Медицина, 1971. - 263.

**Крюков В. Н. [и др.]** Судебная медицина - Москва: Медицина, 2006 - 448 с.

Codul de Procedură Penală al Republicii Moldova. Nr. 122 din 14.03.2003 (<http://lex.justice.md>)

Collins dictionaries (<http://www.collinsdictionary.com>)

Oxford dictionaries (<http://oxforddictionaries.com>)