

Images in Pediatric Surgery

Complicated pulmonary hydatid cyst with endobronchial eruption

Crevceanschi E., Dogotari N.

PHI Mother and Child Institute
"Natalia Gheorghiu" National Scientific and Practical Center of Pediatric Surgery
Radiology and Imaging Department

Correspondence to: e-mail: nicolai-dogotari@mail.ru; mob. 067156999

Keywords: complicated hydatid cyst, endobronchial eruption, computed tomography

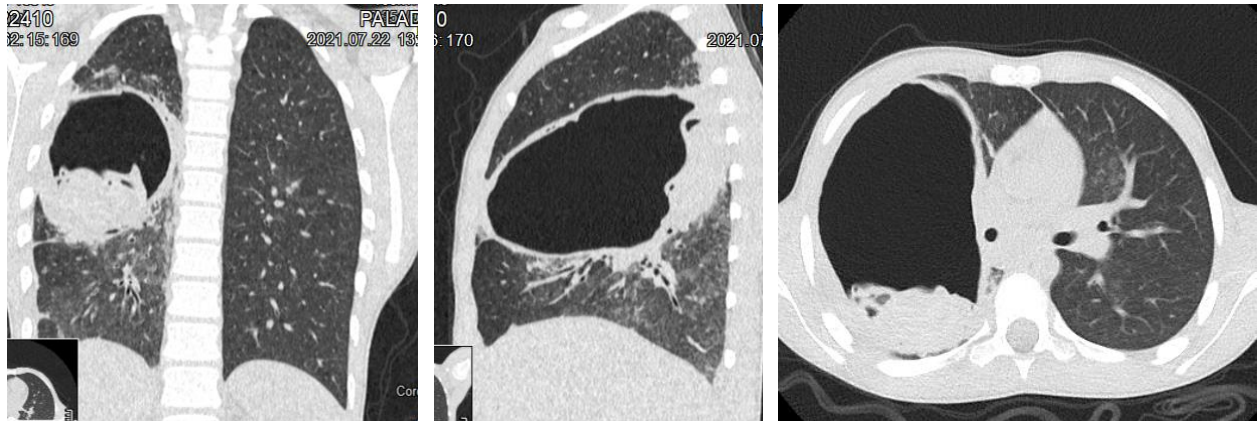


Figure 1: Patient P.A., 11 years old. Preoperative CT: hidatid pulmonary cyst with endobronchial eruption situated in middle lobe of right lung. The floating membrane sign is displayed.

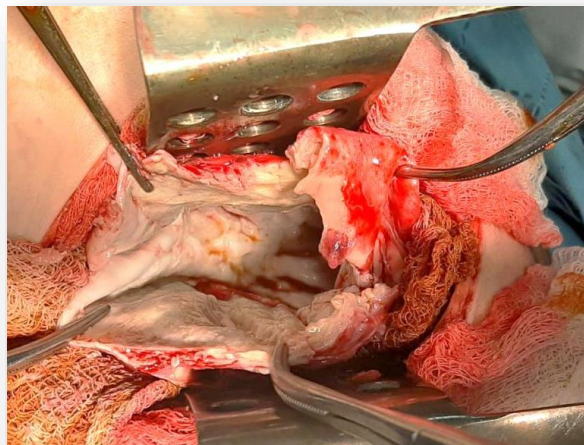


Figure 2: Patient P.A., 11 years old. Intraoperative appearance of the remaining cavity after removal of the hydatid cyst larva and excision of the walls to the lung tissue