

20. McAllister B., Haghghat K., *Bone augmentation techniques*. J Periodontol. 2007;78:377-396.
21. Menchero-Cantalejo E., Barona-Darado C., Cantero-Alvarez M. et al., *Meta-analysis on the survival of short implants*. Med Oral Patol Oral Cir Bucal. 2011; 16: 546-551.
22. Misch C. E. *Contemporary Implant Dentistry. Third Edition*. St. Louis: Mosby Year book, Inc. 2008: 1102.
23. Mostovei A., Topalo V., *Minimally-invasive surgery in two-piece dental implants placement*, 16th Congress of the Balkan Stomatology Society, 2011: 119.
24. Penarrocha-Diago M., Aloy-Prosper A., Penarrocha-Oltra D. et al., *Localized Lateral Alveolar Ridge Augmentation with Blok Bone Grafts: Simultaneous Versus Delayed Implant Placement: A Clinical and Radiographic Retrospective Study*, International Journal of Oral and Maxillofacial Implants, 2013;28:846-853.
25. Pierrisnard L., Renouard F., Renault P., Barquins M., *Influence of implant length and bicortical ancorage on implant stress distribution*. Clin. Implant Dent. Relat. Res. 2003; 5:254-262.
26. Renouard F., Nisand D., *Impact of implant length and diameter on survival rates*, Clinical Oral Implants Research, 2006; 17(Suppl 2): 35-51.
27. Salvi G., Lang N., *Diagnostic Parameters for Monitoring Peri-implant Conditions*, International Journal of Oral and Maxillofacial Implants 2004;19(suppl):116-127.
28. Schneider D., Witt L., Hammerle Ch., *Influence of the crown-to-implant length ratio on the clinical performance of implants supporting single crown restorations: a cross-sectional retrospective 5-year investigation*. Clin. Oral Impl. Res. 2012; 23:169-174.
29. Sennerby L., Roos J., *Surgical determinants of clinical success of osseointegrated oral implants: A review of the literature*. Int J Prosthodont . 1998; 11: 408-420.
30. Slotte C., Gronningsaeter A., Halmoy A. et al., *Four-millimeter implants supporting fixed partial dental prostheses in the severely resorbed posterior mandible: Two-year results*. Clin. Implant Dent. Relat. Res. 2011; 14(suppl 1):46-58.
31. Snauwaert K., Duyck J., van Steenberghe D. et al., *Time dependent failure rate and marginal bone loss of implant supported prostheses: A 15-year follow-up study*. Clin Oral Investig. 2000; 6:142-146.
32. Srinivasan M., Vazquez L., Reider Ph. et al., *Efficacy and Predictability of short dental Implants (8mm): A critical Appraisal of the Recent Literature*, International Journal of Oral and Maxillofacial Implants, 2012; 27:1429—1437.
33. Stanford C., Estafanous E., Oates T. et al., *Status Update: „Short Implants“ Outcomes*. International Journal of Oral and Maxillofacial Implants, 2010; 25:444-446.
34. Tal H. et al. *Spontaneous Early Exposure of Submerged Endosseous Implants Resulting in Crestal Bone Loss: A Clinical Evaluation Between Stage I and Stage II Surgery*. Int. J. Oral Maxillofac. Implants. 2001; 16: 514-521.
35. Telleman G., Raghoobar G., Vissink A. et al., *A systematic review of the prognosis of short (10mm) dental implants placed in the partially edentulous patient*. Journal of Clinical Periodontology, 2011; 38:667-676.
36. Topalo V., Dobrovolschi O. și al., *Metodă miniinvasivă de instalare a implantelor dentare endosoase*. Buletinul Academiei de Științe al R. Moldova, Științe medicale, Chișinău, 2008; 1(15): 153-156.
37. Tsumita M., Kokubo Y., von Steyern P., et al., *Effect of framework shape on the fracture strength of implant-supported all-ceramic fixed partial dentures in the molar region*. J. Prosthodont. 2008; 17:274-285.
38. Van Steenberghe D., Lekholm U., Bolender C. et al., *Applicability of osseointegrated oral implants in the rehabilitation of partial edentulism: A prospective multicenter study on 558 fixtures*, International Journal of Oral and Maxillofacial Implants, 1990; 5:272-281.
39. Wyatt C., Zarb G., *Treatment outcomes of patients with implant-supported fixed partial prostheses*. International Journal of Oral and Maxillofacial Implants, 1998; 13:204-211.

Data prezentării: 14.08.2013.
Recenzent: Natalia Rusu

ALTERNATIVE IMPLANTATION METHODS TO AVOID SINUS GRAFTING

Abstract

The purpose of this study was to evaluate and modify alternative methods for implant placement in the posterior maxilla using a limited amount of existing bone, thus avoiding sinus grafting. A total of 162 patients with 343 implants in the posterior maxilla divided in 5 retrospective groups were evaluated according to different treatment modalities: the short implants group, the palatal positioned implants group, the pterygomaxillary implants group, the tilted implants group and the implants cantilevered prostheses group. Optimal use of the posterior maxilla was achieved by modifying the surgical technique required. Patients were treated consecutively between 2004—2011, and were followed up 60 months after prostheses delivery. A success rate of 96.7% for short implants, 93% for palatal positioned implants, 92% for pterygomaxillary implants, 94.6% for tilted implants and 95.2% for implants with cantilevered prostheses at 5 years of follow up was obtained. No statistically significant differences were found between the groups for either of the evaluated procedures. Placing implants in pre-existing bone in the posterior maxilla enables avoidance of more complex surgical procedures such as sinus floor augmentation. These methods led to simpler, more predictable, less expensive, and less time-consuming treatment compared to more invasive maxillary sinus augmentation.

Key words: *short, palatal, titled, pterygomaxillary and cantilevered prostheses implants.*

Fahim Atamni

D.M.D, Ph.D

*Clinic for Oral-surgery
and implantology-Tel
Aviv*

Valentin Topalo

*D.M.D, Ph.D, Dr. Hab.
Med. Prof. University
Department of Oral and
Maxillofacial Surgery
and Oral Implantology
“Arsenie Gușan”,
USMF “N.
Testemitanu”*

Rezumat

METODE ALTERNATIVE DE IMPLANTARE PENTRU EVITAREA GREFĂRII SINUSULUI MAXILAR

Scopul studiului a constat în evaluarea și perfectarea metodelor alternative de instalare a implantelor în sectoarele posterioare maxilare folosind cantitatea de os existent și evitând greșirea sinusului. Au fost evaluați 162 pacienți la care au fost instalate 343 implanturi în sectoarele posterioare maxilare, care au fost divizate în 5 grupe (retrospectiv) în dependență de metoda de instalare a lor: grupul cu implanturi scurte, implanturi poziționate palatal, implantate pterigomaxilare, angulate, implantate ce suportă construcții protetice cu extenzii. Utilizarea optimă a sectorului posterior maxilar a fost obținută prin modificarea tehnicilor necesare. Pacienții au fost tratați în perioada 2004—2011 și au fost evaluați pentru o perioadă de 60 luni după încărcarea funcțională. La un interval de 5 ani de evaluare, a fost obținută o rată de succes de 96,7% pentru cele scurte, 93% pentru implantele palatale, 92% pentru cele pterigomaxilare, 94,6% în cazul celor angulate și 95,2% pentru cele cu extenzii ale construcției protetice. Nu a fost depistată diferență statistică între grupuri pentru oricare din parametrii analizați. Instalarea implantelor în osul rezidual al sectoarelor posterioare maxilare permite evitarea unor proceduri chirurgicale complexe cum este elevarea planșeului sinusului maxilar și augmentarea sa. Aceste metode conduc la un tratament mai simplu, previzibil, mai accesibil și de durată mai mică comparativ cu metodele de augmentare invazivă a sinusului maxilar.

Cuvinte cheie: *implante scurte, angulate, pterigomaxilare, palatale și cu construcții protetice cu extenzii.*

Introduction

Implant-supported fixed prostheses represents today a common treatment for the rehabilitation of totally or partially edentulous patients. It is well known that the placement of implants in the edentulous posterior maxilla may be difficult, namely the restricted quantity of subsinusal bone due to severe bone resorption as a consequence of tooth loss, pneumatization of the maxillary sinus and low bone density including the tuber region [17]. Sinus floor augmentation with autogenous bone grafts or with biomaterials has since long been the predominant, well-documented procedure in the literature [12]. In spite of the excellent outcomes of this procedure [12, 31], it is associated with several possible complications at the donor and host sites, sinusitis, fistulae, loss of the grafts or the implants, osteomyelitis, increases duration and costs, increases morbidity and functional limitations including pain

and neurosensory deficits and patients acceptance [14]. In addition, unpredictable reduction in bone graft volume as a result of resorption is common. Undoubtedly, this kind of long-lasting therapy can be physically demanding especially for elderly patients. Surgical methods have therefore been elaborated to minimize both the number and extent of operative interventions, and also the need for major bone grafting. To overcome these limitations, some have suggested using the existing anatomic features to place the implant, such as short implants [11, 32], tilted implants placed in the anterior or posterior sinus wall [9,19], Palatal positioned implants using the palatal curvature [28], pterygomaxillary implants using the pterygoid process [7,19]. Another alternative therapeutic option in case of limited available bone is represented by incorporating the distal cantilever design in implant supported prostheses [35]. The use of short implants defined as implants lesser than 10mm in length [11] as a minimally invasive surgical technique is still controversial. Many studies have shown higher failure rates for shorter implants, whereas recent investigations show that short implants can be quite predictable and have a success rate similar to that seen for longer implants [23,32]. In an extensive review of 33 studies with 16, 344 implants of 7, 8.5, or 10mm long published between the year 1980 and 2004, the total rate of success was 95.2% [11]. The authors concluded that short implants should be considered as an alternative to advanced sinus floor augmentation surgeries. In a review of the literature covering the period 1990 to 2005, data of 22 publications reporting an adapted surgical preparation and the use of textured-surfaced implants have shown survival rates of short implants comparable with those obtained with longer ones [32]. The influence of diameter and length of implant on early failure was also recently analyzed in a retrospective study of 1649 implants placed in different areas in 650 patients [27]. In other clinical studies of the performance of short implants, success rates between 92.2 and 99.0% have been reported [32, 16]. Placement of implants tilted distally or mesially (Parallel to the anterior or posterior sinus wall) as parasinusal angulation allows maximum use of existing bone avoiding sinus grafting procedures [21]. Longer implants can be placed despite the lack of available bone, because they are inserted in an angulated position; Rosen and Gynther [38] placed implants up to 18mm in length in this area, allowing engagement of as much cortical bone as possible; in fact, the tilted implants are placed between the cortical bone of the crest, the mesial wall of the maxillary sinus, and nasal floor, achieving tricortical anchorage, thus increasing primary stability. Furthermore, increasing the interimplant distance and reducing cantilever length, a better load distribution may be achieved [19]. Tilting of the implants did not affect the marginal bone resorption pattern. No significant difference in bone level change between axial and tilted implants has been found [43]. A technique has been reported for implants placed tangential to the palatal

curvature in the area of the first and second molar [28]. These implants were placed in the direction of the palatal sulcus, i.e. the bone impression of the great palatal bundle tangential to the palatal concavity in the cortical plate of the maxilla to provide acceptable support for fixed prostheses. Placement of implants in the pterygomaxillary region is more technically demanding. Because of limited accessibility it was previously thought that the pterygomaxillary area was inoperable or unsuitable for implant placement because of large fatty marrow spaces, limited trabecular bone, and biomechanical factors [45]. A lower success rate was expected for implants placed in this region. Using a larger number of implants or wider-diameter implants to obtain greater surface area for bone implant contact was considered to increase the success rate. Implants in the pterygoid region in the posterior maxilla were first suggested by Tulasne in 1992 [45] and later discussed by other authors to get anchorage in the dense bone in the pterygoid plate united to the tuberosity medio-posteriorly [6]. Engaging the cortical bone of the pterygoid plate with long implants can improve primary stability thereby providing long-term success. The technique itself is not without risk, since the drill path is close to important anatomic structures. A slight deviation of the direction of the drill may induce the risk of bleeding from the maxillary artery or from the greater palatine artery. To avoid mainly the risk of hemorrhage and to condense the bone for better primary stability Valeron et.al [47] presented cylindrical osteotomes for bone site preparation, thus minimizing the use of drills and reported of an absolute survival rate of 95.7% which was comparable with those of other studies in grafted maxillae. Ridell et.al [33] presented a technique used includes preparation of an inspection window into the maxillary sinus, which further ensure implant placement. Numerous reports attribute to these implants success rates that are similar to or higher than those of other techniques [33]. Penarrocha et.al [29] reported a success rate of 97.5% obtained in the 68 pterygoid implants placed with a combination of drills and osteotomes. The use of blunt tools instead of sharp drills minimizes the danger of injuring close anatomic structures. There are various implant treatment concepts using distal cantilever prostheses with reports of long-term success [35]. This construction design allows a more straightforward rehabilitation of edentulous areas. In implant-supported fixed dental prostheses (IFDPs) and implant-supported cantilever fixed dental prostheses (ICFDPs) the distribution of masticatory forces appeared not to be uniformly distributed. Higher strain concentration adjacent to the extension was noted, which may lead to bone loss around implants. Clinical studies reported conflicting results for medium and long-term outcomes of ICFDPs compared with IFDPs without cantilever extensions. Romeo et.al [37] reported an overall implant survival rate of 97% and a prostheses success rate of 98% during follow-up period of 1-7 years. The survival rates were similar for both treatments and,

hence, it was concluded that ICFDPs represented a predictable therapy. Nadir et.al [26] in controversy reported a higher number of complications for ICFDPs compared with IFDPs (29.4% vs. 7.9%). Different variables in study design may explain these controversies. Romanos et.al [11] reported that cantilevers provide a treatment option without a high risk of complications. A 95% implant survival may be achieved providing predictable and reliable clinical outcomes. The aims of the present retrospective study were to evaluate and modify the treatment outcome of different alternative treatment modalities of the atrophied posterior maxilla to avoid sinus augmentation, such as short, tilted, palatal positioned, pterygomaxillary implants and implants with cantilevered prostheses and to compare the outcomes for these alternative treatment modalities and sinus augmentation with regard on implant survival up to 5 years of function.

Materials and Methods

Patient selection and evaluation

The study was performed as a retrospective investigation of patients treated during 2004–2011 in the author’s private practice (Tel-Aviv Israel) with a total of 343 implants (Alpha Bio, MIS, ITI, Adin, Alpha Gate) installed in the posterior maxilla according to alternative treatment modalities to avoid sinus augmentation. A total of 162 patients (87 males, 75 females) were included. The mean age at surgery, which was performed by one surgeon, was 62 years (range 41-78 years). Ninety six patients were at the time of surgery completely edentulous in the upper jaw and 66 were partially edentulous. Patients were restored for single tooth, partially and totally edentulous sites. (Table 1, 2).

Gender	Age						Total
	21-30	31-40	41-50	51-60	61-70	> 71	
Female	10	12	14	16	17	14	83
Male	8	9	11	19	22	10	79
Total	18	21	25	35	39	24	162

Year	No. of Implants	Percentage of Total (%)
2004	11	3.2
2005	15	4.3
2006	28	8.1
2007	42	12.2
2008	44	12.8
2009	56	16.3
2010	68	19.8
2011	79	23
Total	343	

Preoperative analysis was performed in all patients before treatment to study remaining bone. The choice of treatment was based on the amount and direction of bone available for implant placement as determined by clinical and radiographic presurgical examinations. Patients were divided into 5 groups

with implants placed following one of five specified alternative treatment modality: a) Short implants with or without transcresal sinus floor elevation (TSFE). d) Tilted implants. b) Palatal positioned implants. c) pterygomaxillary implants. e) Implants with cantilevered prostheses. Table 3 shows the distribution of treatment groups to patients and implants.

Treatment Group	No. of patient	No. of Implants
Short Implants	38	122
Palatal Positioned Implants	15	28
Pterygomaxillary Implants	25	33
Tilted Implants	32	56
Implants with cantilevered prostheses	52	104
Total	162	343

A sinus augmentation group, which has been studied and published in a separate article [3] served as a reference group for comparison of the clinical survival rates and results of all included groups in this study. All patients underwent minimally invasive surgery. These patients received 343 implants. Ninety three short implants were placed in 26 patients. Twenty nine short implants were placed in 12 patients with transcresal sinus floor elevation without grafting material. Implants situated in adjacent sites were routinely splinted, regardless of implant size, to improve a more strain distribution during functional loading. The most posterior implant in these patients was placed, depending on the bone available, into the pterygoid plate and into the tuberosity (33 implants). Fifty six additional tilted implants were placed close to and parallel with the anterior and posterior sinus wall (Tilted implants). Twenty-eight additional palatal positioned implants were placed into the palatal curvature in the molar region. One hundred four implants were placed in partially or totally edentulous arches rehabilitated with cantilevered prostheses. 67 implants in 38 patients were placed in type II bone density, 131 implants in 53 patients were placed in type III bone density and 145 implants in 71 patients were placed in type IV bone density. In type III or IV bone density, implants with greater diameter, roughened surface were preferred. Narrow implants and wide implants have been used according to standard implantation protocol. Narrow-diameter implants i.e. 3.3mm in diameter were indicated for thin bone volume ≥ 4 mm and were used in specific conditions such as a reduced interradicular bone, thin alveolar crest, or replacing teeth with a small cervical diameter. Wide- diameter implants i.e. 5mm have been used to increase the ability of these implants to tolerate occlusal force. These implants were designed to address wider sites and higher occlusal forces. These implants were placed as either monocortically, bicortically or tricortically anchored. The following basic procedural concepts were used in this study: a) Placement of sufficient No. of implants to withstand the high occlusal forces. Two implants for

each missing molar were suggested for a single site to mimic the anatomy of the roots, if 14mm or more space between adjacent teeth was present. b) Use of wider (≥ 4) mm implants rather than the 3.75 mm standard design, when possible.c) Use of a threaded design implant. d) Presurgical planning of the final restoration. e) avoid transmucosal loading at the implants.

It was mandatory to thoroughly review the patients' medical history. Special attention was devoted to patient-related factors that may affect bone healing. A systematic approach includes: a) General health status b) Concomitant medication c) Allergies (Allergic sinusitis) d) Tobacco and alcohol e) Compliance was accomplished. All patients met the requirements of a strict selection protocol (Table 5).

Inclusion

Presence of at least 1 mm residual bone height (RBH)

Good general health and patients with controlled medical conditions

Stable mental health condition

Ability to complete at least 24 month of clinical follow-up

Willingness to provide signed informed consent

Exclusion

Uncontrolled diabetes

Presence of immunodeficiency

Use of immunosuppressive

Use of bisphosphonate

Radiation therapy in head and neck included the maxilla

Chemotherapy in the 12-month period prior to proposed therapy

Heavy smokers more than 20 cigarettes/day

Tobacco use was not considered as absolute contraindication for surgical procedure.

Clinical and radiographic examination

A complete physical examination of oral hard and soft tissues was carried out for each patient, and an overall dental treatment plan was formulated. Diagnostic casts, wax-ups, and surgical guides were also used as needed. The ridge was assessed mesiodistally and buccolingually to ascertain whether it can accommodate an implant. Interarch clearance has been studied to determine space availability for the implant and crown. The prognosis and role of adjacent and opposing teeth was considered. The nature of the opposing dentition was noted as being either natured dentition, partially fixed prostheses, a removable partial denture, or a complete denture. The quantity of keratinized mucosa and the profile of the alveolar crest were evaluated: a thick mucosa and a regular alveolar crest are important prerequisites for flapless surgery and fixed prostheses. The preoperative examination consisted in most patients of a panoramic radiographs, and if necessary intra-oral periapical radiographs to exclude pathology. In a few patients conventional CT-scans were obtained. The radiographs were obtained from patients included in this study at baseline to evaluate the available bone quality

and quantity, angulation of bone, selection of potential implant sites and to verify absence of pathology. Panoramic radiographs were obtained to determine the vertical bone dimension, after second-stage surgery and after prostheses placement. CT scans were obtained to determine the existing osseous structure and to evaluate any pathology of the sinuses particularly for patients planned for TSFE combined with short implants. The values obtained from the panoramic measurements were corrected for their magnification (divided by the enlargement factor 1.2) as defined by the manufacturers. CT images were in their actual size (ratio 1:1).

According to analysis of CT scans or panoramic imaging the location of sinus walls and tuber region were assisted. Bone density in the posterior maxilla was determined by the resulted tactile sense during implant site preparation following the method of Misch [24] using a physiodespenser intrasurg 300 kavo Germany. This led us to modify our surgical protocol and treatment plan according to the resulted tactile sense during implant site preparation.

The insertion torque was recorded during implant placement with the help of the torque driver (Alpha Bio Israel) or through a torque gauge incorporated within the drilling unit INTRA surg 300 (kavo) Germany. Periotest measurement was performed for all patients at implant placement, at the second stage surgery, and at the start of loading. Each measurement was repeated until the same value was recorded twice; Periotest value (PTV) was given in form of an implant stability degree to allow comparison between the different study groups. To determine the implant secondary stability reverse torque test (RTT) was measured at the time of second stage surgery. The RTT was evaluated for each implant separately. It was measured with a hand torque wrench (Alpha-Bio Tech Israel) by unscrewing the implants with 20 Ncm if interfacial failure occurred, the implant was considered as failed. In all cases peri-implant marginal bone loss (MBL) was measured on conventional periapical, digital periapical or panoramic radiographs. At the time of implant placement, loading time, after 1 year, then annually to 5 years. The measurements were carried out using the threads of the implants as the internal standard. Measurements were calculated on 2 of the panoramic imaging from each patient one taken immediately after implant placement, and one taken at the last follow-up annually to 5 years. MBL was evaluated by subtracting the bone level at the time of implant exposure from that of the most recent follow-up. The number of threads unsupported by bone at both the mesial and distal sides of each implant was counted, and the higher number was used for bone loss calculation. This result was multiplied by the implant pitches (in mm). Manufacturer provided information about the pitch of implant system used.

Evaluation of long-term follow-up

All patients included in this study were part of a regular recall program. Data were collected at base-

line, at the conclusion of implant placement abutment connection; at the time of prostheses delivery until the last follow-up and analysed retrospectively. After prostheses delivery they were evaluated for the first year and annually thereafter. Of 162 patients 153 presented and followed underwent clinical and radiographic examinations. A periapical radiograph was obtained any time the patient reported unexpected pain or discomfort or if soft tissue health worsened. The recall program included assessment of marginal bone loss, pocket depth, the plaque and Gingival indices, implant mobility, and implant survival time. The initial postoperative radiograph was compared with the most recent one. Evaluated parameters were described and compared for the different surgical procedures. The images were evaluated for peri-implant conditions.

Implant success, survival and failure

Implant success was evaluated as suggested by Albrektsson et.al [2]. If any one of these criteria was not fulfilled, the definition of success was not met and it had to be changed to the level of survival and if the patient was dismissed, the implant was defined as not accounted for, and if the implant was mobile and was subsequently removed, it was regarded as a failure. Since failure do occur over different periods of time, early and late-failures were considered.

Surgical procedure

Anatomical considerations

Width and height of the posterior maxillary residual bone were totally acceptable in all cases for one of the specified alternative treatment options to exclude sinus augmentation. Corresponding to the classification of Lekholm and Zarb [20] the quality of jaw bone was subjectively graded in 3 groups. Type IV bone was the dominant one encountered. Advanced bone resorption had often resulted in a decreased high of the alveolar process, while satisfying amount of bone existed in the tuberosities, mesial and distal areas of the sinus and the palatal curvature. This situation was judged to justify implantation in one of the specified areas already mentioned. When planning for implants of the five specified treatment options, the implant length was estimated from the panoramic radiograph or from CT-scan if exists, so that the implant corresponds with the existing bone so that the maxillary sinus walls (anterior, posterior, palatal) should not be penetrated and when planning for tuber implants we should be absolutely certain not to interfere with the maxillary artery and its branches running superiorly of the pterygoid laminae and medially in the pterygopalatine fossa [46]. In the severely resorbed posterior maxilla, the amount of bone is limited; consequently, the implant position represents a compromise between the ideal axial position and the bone.

Surgical technique

All surgery was carried out by the same surgeon and was performed under local anesthesia (2% Lidocaine with 1:100000 adrenalin). Some of the patients

were orally premedicated with 15mg benzodiazepam one hour before surgery. Full mucoperiosteal buccal flaps were raised and the alveolar process and the facial bony wall were exposed. All implants in this study were surgically placed in healed bone or fresh extraction sites following the Branemark standard protocol [8]. The patients were submitted to a preventive protocol. This included amoxicillin and clavulanic acid (2g) one hour before surgery and twice daily thereafter for the following 7 days. Implants were placed in a one or two-stage approach. A flap technique is necessary to observe the underlying alveolar bone and adjacent anatomical structures and to place implants in the correct position. In cases of alveolar ridges that were too small to receive 3.75mm diameter implants, special surgical procedures were performed to increase the available bone width: split crest and guided bone regeneration (GBR) techniques were the first choices of techniques to augment the ridges horizontally.

To enhance the loosely structured trabecular bone in the posterior maxilla, undersized or underdimensioned drilling was used. Prior to placement of 3.75, 4.0 and 5.0mm implants, 2.0 to 3.8mm diameter twist drills were used respectively. Great care was taken to guarantee that the osteotomy maintained the perfectly concentric shape needed to achieve the required initial tight press-fit of the implant. In attempt to improve bone density at the implant site in bone type III or IV and to enhance primary stability condensing the bone with osteotomes was accomplished. To achieve good primary stability without creating excessive compression in the peri-implant bone implants were inserted with a torque of at least 30 to 45 Ncm until it was fully inserted. Another technique used to increase primary stability involves the use of tapered implants engaging the opposing cortical bone of the sinus floor. The thin cortical bone on the crest provided improved initial stability of the implant when it was compressed against the implant neck. The use of implants with a shoulder wider than its body increased the primary stability of the implants in a way that the implant shoulder engages the cortical crestal bone. The compressed soft bone not only provided greater stability, it also initiates a good healing with a higher bone Implant Contact (BIC). A brief description of the surgical techniques applied to the different treatment modality is presented and described in details in each specific section of the complete theses to avoid repetitions.

Specific surgical considerations

Short implants

The conventional surgical technique described by Branemark [8] and the osteotome procedure described by Summers [40] were used. The implants measured 8mm in length 3.7, 4.1, 4.2, 4.8, 5mm and 6.0mm in width. In cases of crestal bone height that were too small to receive 8mm long implants, transcresal sinus floor elevation to enlarge the ridge vertically without the need of grafting material. This technique was ac-

complished as described by Topalo et.al [44]. Implants were placed in the following clinical indications:

- a) Standard-diameter implants restored with single crowns in the posterior maxilla.
- b) Two-standard-diameter implants restored with a 3 unit fixed prostheses.
- c) Implants with 6.0mm diameter placed at the time of extraction and transcresal sinus floor elevation, utilizing previously described technique and restored with single crowns.
- d) One standard-diameter and one wider implant (6.0mm) supporting a 3-unit fixed partial denture.

Regenerative therapy was performed around implants placed at the time of tooth extraction in the posterior maxilla. Biocortical anchorage of short implants was desired to increase initial implants stability.

Tilted implants

A full mucoperiosteal buccal flap was raised and the facial bony wall was exposed in the posterior maxilla. Subsequently, the lateral sinus wall close to the anterior sinus border was perforated. By means of a straight probe, the inclination of the anterior sinus wall was noted. The implants were tilted distally or mesially approximately 30 to 35 degrees relative to the vertical plane and were placed close to and parallel to the anterior or posterior sinus wall anchoring the implant in the cortical anterior sinus wall, without perforating it. Implants were placed in a two-stage approach.

Palatal positioned implants

A full-thickness flap was made from site of first premolar distal to the second molar area, with releasing incisions to the buccal and palatal surfaces. The palatal flap was elevated until the superior border of the impression (sulcus) of the great palatal bundle was reached. The implants were placed from the alveolar ridge passed through the palatal cortical plate and sulcus formation, which assured that cortical anchorage was achieved. In cases where a drilled template was prepared in accordance to CT examination, the template was placed in the mouth and fitted onto the mucosa and was immobilized by the remaining teeth to prevent undesired movement of the surgical guide during implant site preparation. Through the prepared drill sleeve, a 2mm drill was initiated to determine the implant position at the top of the crest and to create the pilot hole to the desired depth. A second 2.8mm drill was inserted to enlarge the hole for implant placement. Sinus perforation was checked, if no perforation is detected, implants were placed to final position. Implants were placed at second premolar and first molar sites. Bone quality was classified as type III. This procedure often left few threads of the inserted implants exposed on the palatal side, which were then covered with autogenous bone collected from the surgical area. All implants were left submerged.

Pterygomaxillary implants

A crestal incision was made, along with a releasing incision located distal to the maxillary tuberosity. The

alveolar process was exposed. To maximally utilize the bone posterior of the sinus, in some cases the lateral sinus wall was perforated in order to explore the posterior wall of the sinus cavity with a probe. In this way implant site could be prepared in the tuber region without perforation in the sinus cavity. In some cases one additional implant was placed anteriorly of the sinus in the same manner as well. Preparation of the implant bed commenced with a pilot drill to establish the direction of the implant axis. To overcome the problem with low bone density, a 2.8mm drill for a 3.75mm implant or a 3mm drill with a 4.2mm implants, mostly combined with bone grafts harvested locally were used. Firm primary stability was achieved for all implants. Preparation continued with consecutive use of graded osteotomes in combination with drills of increasing diameter. The use of osteotomes assured the preservation of bone through direct manual contact and sense to form the bone site by expansion. The drills helped to widen the implant site through the very dense cortical bone. For patients with significantly soft or insufficient tuberosity, an implant was placed into the pterygoid plate. Specifically, preparation of the site is confined to drilling to the appropriate depth with 2 or 2.8mm twist drill while being sure to engage the supracortical plate if possible. Antero-posterior drilling angles were adapted to the patient's anatomy, entering 10 to 20 degrees mesially to stimulate the correct angulation of a third molar. It is important to feel the way from soft cancellous bone to hard cortical bone. Following Tulasne's recommendation, all implants were at least 13mm long to ensure anchorage in the pterygomaxillary region [45]. Implants were seated with bicortical anchorage if possible. The placement of two implants in the tuberosity if possible is advantageous to minimize possible risk of implant failure. Two implants in the tuber region were placed in each 8 patients in this study. Minimal countersinking was recommended if a thin cortical plate existed expecting crestal resorption after implant loading. All implants were submerged for a healing period of approximately 4 to 6 months. During both drilling and implant placement, care must be taken not to interfere with the maxillary artery and its branches and to avoid the greater palatine artery.

Implants with cantilevered prostheses

All implants in this group were surgically placed in the first or/and second premolars in partially dentate patients. In edentulous patients, 4 to 8 implants were placed from the second premolar of one side to the second premolar of the corresponding side including the premaxilla following the conventional surgical protocol. Implants supported partial cantilever fixed prostheses or complete cantilever fixed prostheses.

Results

Short implants

A total of 122 implants 8mm long were installed in 38 patients, 29 (23.7%) of 3.75mm diameter, 48 (39.4%) of 4.2mm diameter, and 45 (36.9%) of 4.8 and

5mm. All implants were functionally loaded. 4 short implants 3.3% became mobile and were removed following varying years of loading. Two of them were single implants restored with single crowns, one belong to the two implants group restored with 2 unit fixed prostheses, the another one belong to the four implant group. One failed implant was placed in type III bone and three failed implants in type IV bone. No additional failures were observed among the 8mm implants after 3 years and thus the survival rate was unchanged by 5 years follow up, success rate after 5 years was 96.7%. No probing depth > 5mm was detected at any implant sites. Fifty-three premolar (43.4%) and 69 molar (56.6%) were used for implant installation. Bone morphology according to the criteria of Lekholm & Zarb [20] was used to attribute implant sites as follows: Thirty two Type II (26.2%), 37 Type III (30.3%), and 53 Type IV (43.5%). Insertion torque values were between 25 to 35 Ncm. Twenty two (18%) implants of various diameters were placed at the time of transcrestal sinus floor elevation without grafting material. The reasons of failure included implant mobility, persistent inflammation and infection, severe bone loss, and periapical pathology. Three lost implants in two patients were 4.1-x 8mm in the first molar sites; these patients had smoking habits (moderate smokers), which likely developed peri-implantitis and consequent implant loss at the 24-month follow-up. With regard to implantation technique 8mm long implants showed a success rate comparable to those placed with TCSE (96.7% and 96.5% respectively). Most implants (n-117, 95.9%) showed bone resorption ranging from 1.4 to 1.8mm, and only 5 implants (4.1%) showed bone loss between 2.0 and 2.5mm at the 5-year follow-up examination. Fig. 1 shows short implants in different locations (Fig. 1a,b,c).

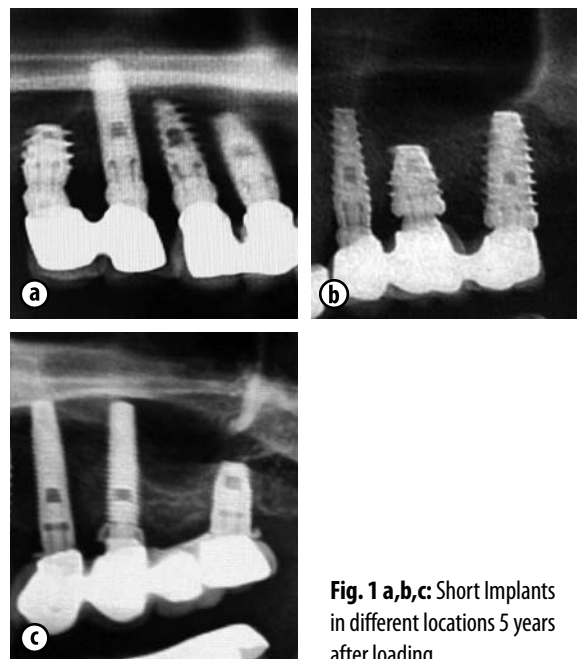


Fig. 1 a,b,c: Short Implants in different locations 5 years after loading

32 patients, with uni- or bilateral edentulous posterior maxilla (17 women and 15 men) were included

in this study group. Average age was 61.3 years. A total of 56 mesially and distally tilted implants in the second premolar and second molar region were placed in this group. Two tilted implants failed during the first year of loading. During the second year of loading another one implant failed too. The cumulative implant success rate was 94.6% up to 5 years follow-up of loading. The average of peri implant crestal bone loss evaluated 1.8mm for tilted maxillary implants. The implants ranged in length from 10 to 16mm and in diameter from 3.75 to 5.0mm. No sinus perforation was observed. Implants were placed in a tilted configuration, with an angle with the perpendicular line ranging from 20 to 35 degrees. Thirty-eight implants were close to the anterior wall and 18 were placed close to the posterior wall of the sinus. Implants were placed with a primary stability of 30-35 Ncm. One implant was lost before loading. Healing in all cases was uneventful, as expected. No additional implants were lost, and there was no infection or inflammation. Two implants showed excessive marginal bone loss exceeding 2mm without the need of implant removal. Fig. 2 demonstrates tilted implants after 5 years of loading (Fig. 2).

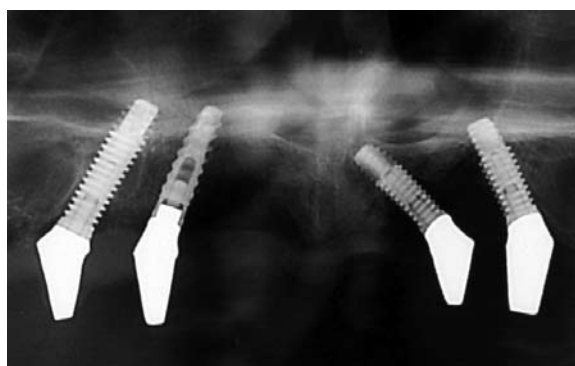


Fig. 2: Tilted implants 5 years after loading

Palatal positioned implants

Of the 28 implants placed in 15 patients into the palatal plate between the medial wall of the sinus and the hard palate, one implant was mobile at the time of abutment connection. The one implant was palatally tilted and placed in the molar region and was removed. Another one implant was lost one year after prostheses placement, showing early resorption around the implant. The patient reported tension and pain in the region at the time of prostheses tightening. During the 1 to 5 years follow up, neither significant radiographic changes of the bone around the implant nor discomfort of masticatory function were registered. A cumulative success rate of 93% was revealed.

Implants were placed with a primary stability of 30-35 N/cm. Sufficient primary stability was achieved for all implant insertions and the implants were judged to be clinically stable. The results of the periotest examination ranged between -4 to -6. New tomographs were obtained to confirm the implant position in the palatal wall of the maxilla, before starting the restoration phase (Fig. 3a, b, c).

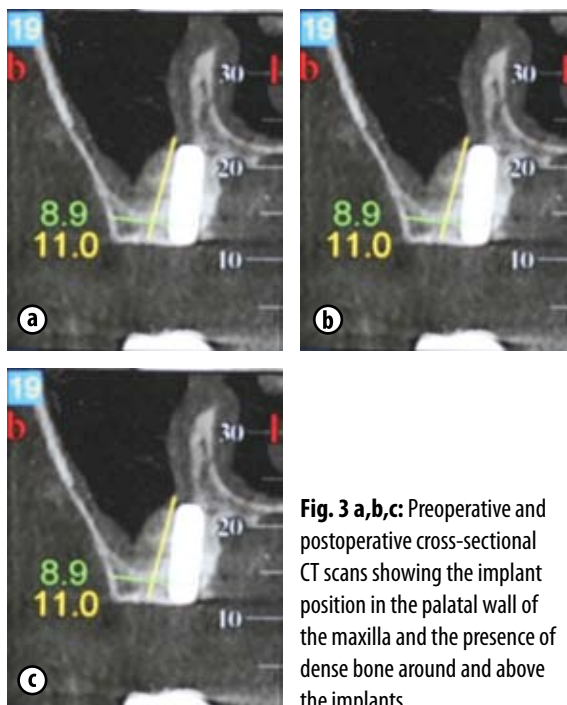


Fig. 3 a,b,c: Preoperative and postoperative cross-sectional CT scans showing the implant position in the palatal wall of the maxilla and the presence of dense bone around and above the implants.

The tomographs examination showed the presence of dense bone around and above the implants. The implants appeared to be well integrated with no peri-implant bone loss. The implants were positioned at the palatal axial inclination. Three schneiderian membranes of the sinuses were slightly detected. All sinus membrane perforations were repaired with collagen membrane and fibrin glue through the osteotomy sites. In two cases of sinus membrane perforation with simultaneous implant insertion a minor penetration of the implant into the sinus were noted, but no mucosal reaction at the implant site was noted. By evaluation of patients those with sinus perforation and those without sinus perforation significant difference was noted. The success rate of the 28 implants placed in palatal position after 5 years of follow-up was 93%. Peri-implants crestal bone loss averaged 1.6mm.

Pterygomaxillary maxillary implants

A total of 33 implants were placed into the pterygomaxillary-pyramidal region in 25 patients showing partial uni- or bilateral edentulous posterior maxilla. The group comprised 14 women and 11 men aged between 35 and 79 years. Of the 33 implants placed, one was mobile at the time of abutment connection and was considered as early failure. Of the remaining 32 one failed in the first year, the second in the third year of loading. The 5 year survival rate was 92%. Four implants were placed in type II bone, and all integrated. Twelve implants integrated in type III bone, and the remaining 17 implants were placed in type IV bone and 14 of them integrated. Of the patients with failed implants, two patients were smokers. The failed implants were 13mm long and 3.75 and 4.2mm wide, which were the most frequently used implants. MBL averaged 1.9mm. Fig. 4 shows intraoral radiograph of unilaterally edentulous patient with pterygomaxillary implant after 5 years (Fig. 4).

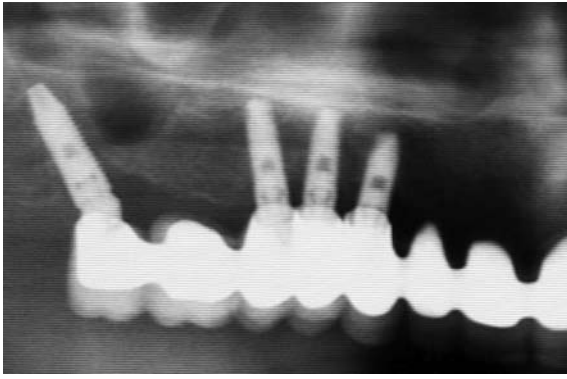


Fig. 4: Intraoral radiograph of unilaterally edentulous patient with pterygomaxillary implant after 5 years of loading

Implants with cantilevered prostheses

Fifty two patients 28 woman and 24 men, with partially or totally edentulous posterior maxillae, were treated with 104 implants placed in existing bone between the second premolars of both sides to support fixed prostheses with long cantilevers. Three implants positioned in the second premolar region failed after one year of loading, additional 2 implants were removed due to bone loss in the 3 to 4 years of loading. The cantilevered implant survival rate was 95.2%. MBL averaged 2.0mm. Fig. 5 demonstrates totally and partially edentulous maxilla with implant supported cantilever prostheses (Fig. 5).

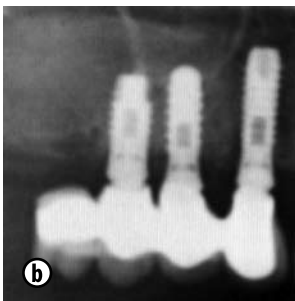
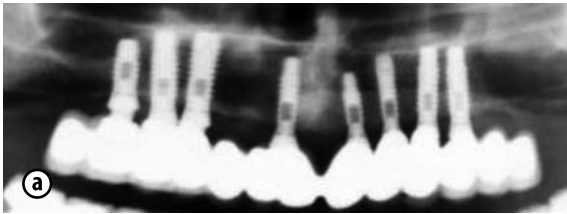


Fig. 5 a,b: Totally and partially edentulous maxilla with implant supported cantilever prostheses 5 years after loading

Discussion

Implant treatment of the posterior maxilla is a demanding procedure. Several recent investigations of long-term outcomes of implants in the posterior maxilla have been published [5,12]. Poor bone quality and severe resorption are the most significant factors associated with implant failure in most studies [5,17].

In the severely resorbed posterior maxilla, implant placement requires sinus grafting to increase the volume of bone necessary for implant placement, a well-documented procedure in the literature [12, 30]. Implant survival in grafted posterior maxilla has undergone steady improvement over the past 25 years. The current findings of overall 99.3% of 3-years post

loading survival rate of implants placed in augmented sinuses is a evidence of the trend of improvement [12, 30].

The drawbacks of sinus grafting are increases in treatment duration and costs, the choice of a donor site, possible surgical complications at the donor and host sites, and patient acceptance. To overcome these negative aspects, some have suggested using the existing anatomic features to place the implants, such as short implants, the anterior or posterior wall of the sinus, the palatal curvature, the pterygoid process [19, 9] and implants with cantilevered prostheses [35].

This alternative methods offers several surgical advantages compared to sinus augmentation procedures: less need for vertical bone grafting, less time for treatment, lower cost of treatment, less discomfort, easier surgery, and fewer surgical risks (e.g. sinus perforation, sinusitis, grafting material displacement). All of these factors make those implants a highly attractive restorative option. It has been suggested that such modified implant placement may resolve most cases without grafts, or at any rate involve a smaller grafting procedure. There is no consensus regarding the length defining a “short” implant. A recent redefinition of a short implant is one that has a designed intrabony length (i.e. length of implant required to achieve and maintain osseointegration) of $\leq 8\text{mm}$ [32]. We used this definition in our study. When short implants are used, ridge height is not a limitation for implant-supported prostheses. The most important limitation is ridge width, because a wide alveolar ridge is essential to retain implants with diameters of ≥ 4 additionally to 1mm cortical bone buccally and lingually. Ridge width of 6 to 8mm is required. As a consequence of reduced ridge height is an unfavorable crown/implant (C/I) ratio, which can be considered one of the prosthetic factors that may increase the risk of biomechanical complications, because unfavorable occlusal forces, such as overloading or non-axial loading. Short implants offer clear advantage over the different surgical techniques used to afford sufficient bone for placing longer implants. The surgery is very simple, because of the scant depth of implantation and the easy and direct irrigation access, the risk of bone overheating is lower [23]. However, a literature review by Misch [23] showed that implants of less than 10mm in length tended to yield higher failure rates than longer implants. Several factors were suggested as possible explanations for these results; lower bone density in the posterior maxilla, the presence of greater chewing forces and an excessively high (C/I) ratio. In order to optimize the function of short implants, Misch [23] proposes some procedural concepts to reduce excessive mechanical loading on the bone, and to distribute the forces over the prosthetic area. These may be achieved by reducing the lateral forces of the posterior implant-supported prostheses, or by placing a larger number of implants, with increased diameter, and with a greater surface area, and splinting the implants. We agree with these concepts.

Garces et.al [39] concluded that implants $\leq 10\text{mm}$ may be useful option in patients with severe alveolar bone resorption. The survival of short implant may be influenced by a number of factors, including location and bone quality, as well as design, type, and diameter of the implants. Atieh et.al [4] demonstrated success rates for short implants that were comparable to those of longer implants, irrespective of design, surface, and width. Most recently, Telleman et.al [42] evaluated a similar data of 29 studies involving 2611 implants up to 9.5mm in length. The authors concluded that there was a significant negative association between implant length and failure rate within the range of 5 to 8.5mm. The more recent employment of short implants with wider diameters may contribute to the high success rates. For every 1mm increase in diameter, implant may increase the functional surface area by 30% to 200% along with the area that is available for osseointegration [22]. Recently, Fugazzotto [15] also demonstrated that implant length had no effect on the magnitude of stress placed on the supporting alveolar bone crest around an implant, a short dental implant should be used if it would be more advantageous. A systematic review concluded that placement of short, rough-surfaced implants ($< 8\text{mm}$) was not less efficacious than implants of at least 10mm long [18]. It is noteworthy to observe that 75% of the failed implants failed before loading. This suggests that the impact of loading and the biomechanical inferiority of the shorted bone-implant interface may not be the major factors in the failure of short implants.

The reliability of short implants according to the literature is controversial with a number of studies concluding that shorter implants showed more failure. Tawil [41] however found no significant difference between survival rates of short (6 to 8.5mm long) versus 10mm long Branemark system implants. A further factor that could potentially affect the survival of short implants is the use of splinting. In this study all implants placed in adjacent sites were splinted, irrespective of implant length. The cumulative survival rates for short implants obtained in our study (96.7%) including the subgroup with TCSE is acceptable and similar to rates reported by others ranging between 88 and 100% [11, 32]. The use of posterior tilting of the implants represents various biomechanical advantages as compared with fairly upright positioned implants. The distalisation of the implant platform reduces the moments of force and improves the load distribution [21]. It should also be considered that the minimum angulation required to define an implant as tilted has not yet been established. In the present study an inclination degree for 30° to 45° of the distal implants was adopted with the use of an appropriate surgical template, however, the placement of tilted implants became easier in the recent years. Only in the study by Calandriello and Tomatis [9] a higher inclination was reported (45° to 75°). In most cases with severe atrophy, the angulation was individually defined according to available bone [9]. Regarding peri-implant

bone loss, no significant difference between upright and tilted implants was reported, except for the study of Calandriello and Tomatis [9]. In that study lower bone loss values for tilted implants were observed as compared with upright ones, which could be related to the position of the implants neck relative to bone crest: mesially, the neck was in a supracrestal position, while the distally was positioned subcrestally, resulting in a favorable soft tissue seal [9]. Thus, an implant that is placed close to the anterior and posterior sinus wall can be expected to provide the acceptable support for prostheses [19]. In the present study, tilting of the implants did not affect the marginal bone resorption pattern and the survival rate was 94.6%. This is in accordance with data obtained by other authors. Capelli et.al [10] placed upright and tilted implants and concluded that tilted implants achieved the same outcome as upright implants. Testori et.al [43] found similar cumulative survival rates for tilted and axial implants at up to 3 years. Krekmanov [19] placed 42 implants in 13 patients; 8 were placed parallel with the anterior sinus wall and none failed. Rosen and Gynther [38] placed 103 implants tilted along the anterior maxillary sinus wall, with a success rate of 97%. However, the hypothesis, that there was more marginal bone loss around tilted implants was not supported by Monje et.al [25], perhaps for the following reasons: 1) the length of the implants used was long and 2) splinting effect.

The advantages of placing implants in the pterygomaxillary region are: a) the ability to provide bone anchorage in the posterior maxilla without sinus augmentation, b) eliminate the lengthy cantilevers that may be necessary when only anterior implants are used for full-arch restorations [29]. According to Tulasne 80% of atrophic maxillae retain a bone corridor that is sufficient to enable placing of an implant 13 to 20mm [45]. This bony pillar consists of a) The maxillary tuberosity, 2) the pyramidal process of the palatine bone, and 3) the pterygoid process. Yamakura et.al [48] observed in his anatomical study that the angle of the tuberosity-pyramid-ptyergoid pillar in the edentulous maxilla is 67 degree in an anteroposterior direction relative to the Frankfort plane. The bony corridor inclination differs from the pterygoid implant (45°) described by several authors [7]. One of the drawbacks of the pterygomaxillary implants is the presence of nonaxial forces, which might compromise the implant survival. A 45° angle in an implant reduces its axial load capacity by half when comparing the same implant at 90° . By placing two implants in the premolar region and a pterygoid implant in the posterior region, a plane in a tripod shape is created that protects the entire framework from transverse force and load, making it possible to restore the posterior maxilla. The present study combined the use of drills and osteotomes to prepare implant beds. The use of blunt tools instead of sharp drills minimizes the danger of injury to arteries and nerves. The use of osteotomes requires no bone removal and it allows cortical bone compaction and lateroapical consolidation

of bone trabeculae. At least 13mm length were placed in the pterygoid region in this study which helps the clinicians achieve good primary stability. The success rate for pterygoid implants is one of the highest in the maxilla. Tulasne observed 97% success, Rodriguez 98%, Balshi et.al 88%, Valeron et.al 93% [45-47, 34]. Ridell et.al [33] reported of 22 pterygoid implants with follow-up of 1 to 12 years, and presented a 100% success rate. Most failures in the pterygomaxillary region occurred before implant loading [7]. According to those studies, it can be stated that pterygoid implants present good long-term survival. Some complications associated to the surgical procedure have been reported: venous bleeding, altering of the maxillary artery and its branches, trismus, misplacement of implant and continuous pain and discomfort [6]. Several authors note the low morbidity associated with the pterygoid implants [7, 45, 29]. In agreement with Balshi et.al [6], no extraordinary complications were observed in the present study. However, all implants achieved a firm primary stability, which is probably a more important factor than bone density itself. On the other hand, the implant had practically no cortical anchorage and most of them had a position where bite forces measures the highest values. Therefore, the use of pterygoid implants can be a prudent option in compromised patients. This technique requires detailed knowledge of the pterygomaxillary region and surgical skill to achieve good results. Rodriguez et.al [34] reported that mesiodistal inclination of the pterygoid implants at 70 degrees to the Frankfort plane decreases the non-axial loads and exhibits good long-term survival.

The present study demonstrate 33 implants inserted in the pterygomaxillary region with the survival rate of 92% similar to the overall survival rate reported in other studies in grafted maxillae.

In this study an alternative method, in which the maximum amount of the severely resorbed alveolar crestal bone was used by palatal positioning of implants, tangential to the palatal concavity in the maxilla, leading to optimal stability achieved by placing the implants along the cortical plate, to provide acceptable support for fixed prostheses.

Implant site preparation and implant placement for palatal positioned implants are similar to tilted implants, and pterygomaxillary implants. Care must taken under the entire drilling and implant placement to prevent sliding of the drill or implant from the bone. Desirable palatal tilting of implants in the premolar and molar regions may provide better load distribution on the implants. Branemark et al [8] to achieve primary implant stability overcame the bone deficiency by palatal positioning of implants leaving some uncovered threads on the palatal side. In the present study, uncovered threads were augmented and the bone buccal to the implant remain intact with more attached gingiva. Fortin et al [13] observed encouraging results of the use of an image-guided system (IGS) for blind surgery to reduce the invasiveness of surgical procedure to place implants in a very limited amount of bone with

high accuracy. Fortin concluded in his proof-of-concept study that the use of an IGS associated with bone spreading for oral implant placement in the atrophic posterior maxilla, particularly in the palatal curvature can be expected to provide acceptable support for fixed prostheses in areas of maximal occlusal loading.

The treatment modality of implants with cantilevered prostheses related to partially or completely edentulous patients. With prosthetic survival of 95% for the use of distal cantilevers, this treatment approach appears to be predictable and compared favorably with distal cantilevers retained by natural anterior teeth [35]. With the advent of the Branemark approach utilizing complete-arch implant supported cantilever prostheses, the distal cantilever has gained acceptance in implant dentistry [8]. There are inherent biomechanical differences in the implant treatment of completely edentulous arches and posterior partially edentulous segments, as the partial prostheses does not benefit from cross arch stabilization and, therefore, is more susceptible to bending loads. Some authors [49, 1] attempted to summarize the causes of failures/complications of implants associated with distal cantilevers. Pjetursson et al [31] concluded that solely implant-supported fixed dental prostheses (FDP) should be the first treatment option regarding survival and complication rates of different designs of FDP. On the contrary, different conclusions can be drawn from this treatment modality: the MBL around the implants supporting a cantilevered fixed prostheses met the success criteria of Albrektsson et al [2] so that this treatment approach should not considered as critical in increasing peri-implant bone resorption: Romeo et al [36] measured the amount of marginal bone loss at free-standing FDP's over a 5 year period of functional loading. The MBL was small and well below the criteria of a proper implant system. It was found that cantilever FDP's had a tendency to show a greater mean peri-implant bone loss and a higher frequency of implants with > 1 mm of bone loss than FDP's without cantilevers. In fact factors such as implant location, abutment length, implant length and type of prosthetic material influence the amount of MBL. The results of the present study revealed that ICFDP's are treatment variations with high predictability and favorable long-term outcomes for the partially edentulous patient, indicating that cantilever supported by implants may yield lower complication rates than cantilevers supported by teeth. As a consequence, it has to be advocated to avoid the use of diameter-reduced implants in the proximity of cantilever extensions in ICFDP's. The overall prostheses survival rate in the present study (95.2%) was comparable with the results of a previous systematic review on implant-supported FDP's [31], in which a meta-analysis including 14 studies yielded an overall estimated survival rate of 95%. The main overall marginal bone-level change of 2.0mm after 5 years at the implant-supported FDP's reported by this study was small and well below the degree of bone loss acceptable according to the success criteria described by Albrektsson et al [2].

An ICFDP's with a short cantilever extensions (one tooth unit) is an acceptable restorative therapy, and might be considered as an alternative to procedures that require sinus grafting surgery.

Conclusion

Despite the trend toward sinus grafting commonly used in patients with severely resorbed posterior maxilla, more attention should be given to the possibilities of implant placement using the anatomic features of the arches without the use of bone grafting procedures and this enhanced the possibility for simpler rehabilitation. Placing implants in pre-existing bone enables avoidance of more complex surgical procedures such as maxillary sinus floor augmentation. The treatment modalities adopted in the present study aimed at combining an optimized use of available bone engaging as much cortical bone as possible with the benefit of placing the implant in a denser cortical bone. These methods led to simpler, more comfortable, lower risks of morbidity, more predictable, less expensive, and less time-consuming treatment compared to more invasive maxillary sinus augmentation. It should also increase patient acceptance avoiding a second surgical area. A success rate of 96.7% for short implants, 93% for palatal positioned implants, 92% for pterygomaxillary implants, 94.6% for tilted implants and 95.2% for implants with cantilevered prostheses at 5 years follow up obtained in this study is a reasonable expectation for implants placed in the posterior maxilla and comparable to a success rate of 95.7% for 1-step sinus augmentation, 95.6% for 2-step sinus augmentation conducted in a separate article [25]. The data from this study indicate that success rates of implants exclusively anchored in preexisting bone or partly anchored in augmented sinuses were similar after an observation time of 5 years. Hence the implant anchorage provided by the bone was capable of standing with prosthetic loading, regardless of the clinical procedure chosen for augmentation and regardless of where it was derived, from nonaugmented, or partly augmented bone. Within the limitations of this study, encouraging results in favor of the use of preexisting bone for implant placement in the atrophic posterior maxilla were obtained. More studies are required to determine whether the success rate can be improved.

References

- 1 Aglietta M, Siciliano VI, Zwahlen M, et al. *A systematic review of the survival and complication rates of implant supported fixed dental prostheses with cantilever extensions after an observation period of at least 5 years.* Clin Oral Implants Res 2009; 20:441-451.
- 2 Albrektsson T, Zarb G, Worthington P.M.D. & Eriksson A.R. *The long term efficacy of currently used dental implants: A review and proposed criteria of success.* The International Journal of Oral & Maxillofacial Implants 1986; 1:11-25
- 3 Atamni F, Topalo V. *A comparative clinical study of implants in the posterior maxilla: methods of sinus floor augmentation versus standard implantation.* Romanian Journal of Oral Rehabilitation 2009; 1 (No. 4):47-53.
- 4 Atieh M, Zadeh H, Stanford C, Cooper F. *Survival of short dental implants for treatment of posterior partial edentulism: A systematic review.* Int J Oral Maxillofac Implants 2012; 27:1323-1331.
- 5 Bahat O. *Branemark System Implants in the Posterior Maxilla: Clinical Study of 660 implants Followed for 5 to 12 Years.* Int J Oral Maxillofac Implants 2000; 15:646-653.
- 6 Balshi TJ, Wolfinger GJ, Balashi SF. *Analysis of 356 pterygomaxillary implants in edentulous arches for fixed prosthesis anchorage.* Int J Oral Maxillofac Implants 1999;14:398-406.
- 7 Bidra AS, Huynh-Ba G. *Implants in the pterygoid region: A systematic review of the literature.* Int J Oral Maxillofac Surg 2011;40:733-781.
- 8 Branemark P-I, Hansson BO, Adell R, et al. *Osseointegrated implants in the treatment of the edentulous jaw. Experience from a 10-year period.* Scan J Plast Reconstr Surg 1977; 16 (suppl):1-132.
- 9 Calandriello R, Tomatis M. *Simplified treatment of the atrophic posterior maxilla via immediate/early function and tilted implants: A prospective 1-year clinical study.* Clin Implant Dent Relat Res 2005;7(suppl):S1-S12.
- 10 Capelli M, Zuffetti F, Del Fabbro M, Testori T. *Immediate rehabilitation of the completely edentulous jaw with fixed prostheses supported by either upright or tilted implants: a multicenter clinical study.* Int. J. Oral Maxillofac Implants 2007; 22:639-644.
- 11 Das Neves FD, Fones D, Bernardes SR, do Prado CJ, Fernandes Neto AJ. *Short implants-an analysis of longitudinal studies.* Int J Oral Maxillofac Implants 2006; 21:86-93.
- 12 Del Fabbro M, Rosani G, Taschieri S. *Implant survival rates after maxillary sinus augmentation. A systematic review.* Eur J Oral Sci. 2008; 116:497-506.
- 13 Fortin T, Isidori M, Bouchet H. *Placement of posterior maxillary Implants in Partially Edentulous Patients With Severe Bone Deficiency Using CAD/CAM Guidance to avoid Sinus Grafting: A Clinical Report of Procedure.* Int J Oral Maxillofac Implants 2009; 24:96-102.
- 14 Froum S. *Dental implant complications etiology, prevention, and treatment.* Blackwell Publishing, 2010.
- 15 Fugazzotto P.A., Beagle J.R., Ganeles J., Jaffin R., Vlassis J., Kumar A. *Success and failure rates of 9mm or shorter implants in the replacement of missing maxillary molars when restored with individual crowns: preliminary results 0 to 84 month in function. A retrospective study.* J Periodontol. 2004;75: 327-332.
- 16 Goene R, Bianchesi C, Huerzeler M, et al. *Performance of short implants in partial restorations: 3-year follow-up of Osseotite implants.* Implant Dent 2005; 14:274-280.
- 17 Jaffin RA, Berman CL. *The excessive loss of Branemark fixtures in type IV bone: A 5-year analysis.* J Periodontol. 1991;62:2-4.
- 18 Kotsovilis S, Fourmoussis I, Karoussis I K BC. *A systematic review and meta-analysis on the effect of implant length on the survival of rough-surface dental implants.* J Periodontol 2009, Nov; 80:1700-1718.
- 19 Krekmanov L. *Placement of posterior mandibular and maxillary implants in patients with severe bone deficiency: A clinical report of procedure.* Int J Oral Maxillofac Implants 2000; 15:722-730.
- 20 Lekholm U, Zarb G. *Patient selection and Preparation.* In Branemark PI, editor: *Tissue integrated prostheses: osseointegration in clinical dentistry.* Chicago, 1985, Quintessence.
- 21 Malo P, Rangert B., Nobre M. *All -on-4 immediate-function concept with Branemark System implants for completely edentulous maxillae: a 1-year retrospective clinical study.* Clin implant Dent Relat Res. 2005; 7 suppl 1:88-94.
- 22 Misch C, Bidez MW. *Contemporary Implant Dentistry.* St Louis, Mo: CV Mosby, 1999.
- 23 Misch CE, Steingra J, Barboza E, Misch-Dietsch F, Cianciola LJ, Kazor C. *Short dental implants in posterior partial edentulism: A multicenter retrospective 6-year case series study.* J Periodntol 2006; 77:1340-1347.
- 24 Misch CE. *Density of bone: effect on treatment plans, surgical approach, healing, and progressive loading,* Int J Oral Implant 1990; 6:23-31.
- 25 Monje A, Chan H, Suarez F, Galindo-Moreno P, Wang H. *Marginal Bone Loss Around Tilted Implants in Comparison to Straight Implants: A Meta-Analysis.* Int J Oral Maxillofac Implants 2012;27:1576-1583.
- 26 Nedir, R., Bischof, M., Szmukler-Moncler, S., Belser, U.C & Samson, J. (2006) *Prosthetic complications with dental implants: from an up-to-8-year experience in private Practice.* Int J Oral Maxillofac Implants 21:919-928.
- 27 Olate S, Lyrio MC, de Moraes M, Mazzone R, Moreira RW. *Influence of diameter and length of implant on early dental implant failure.* J Oral Maxillofac Surg 2010; 68:414-419.

- 28 Penarrocha M, Carrillo C, Boronat A, Balaguer J, Penarrocha M. *Palatal positioning of implants in severely resorbed edentulous maxillary*. Int J Oral Maxillofac Implants, 2009;24:527-533.
- 29 Penarrocha M, Carrillo C, Boronat A, Penarrocha M. *Retrospective study of 68 implants placed in the pterygomaxillary region using drills and osteotoms*. Int J Oral Maxillofac Implants 2009;24:729-726. Romeo, E., Lops, D., Margutti E., Ghisolfi, M., Chiapasco, M. & Vogel, G. (2003) *Implant-supported fixed cantilever prostheses in partially edentulous arches. A seven year prospective study*. Clinical Oral Implants Research 14:303-311.
- 30 Pjetursson BE, Tan WC, Zwahlen M, Lang NP. *A systematic review of the success of sinus floor elevation and survival of implants inserted in combination with sinus floor elevation. [Part I: Lateral approach.]* J Clin Periodontol. 2008 Sep; 35(8 Suppl):216-240.
- 31 Pjetursson, B.E, Tan, k., Lang, N.P, Bragger, U., Egger, M. & Zwahlen, M. (2004a) *A systematic review of the survival and complication rates of fixed partial dentures (FPDs) after an observation period of at least 5 years- I. Implant supported FPDs*. Clinical Oral Implants Research 15:625-642.
- 32 Renouard F, Nisand D. *Impact of implant length and diameter on survival rates*. Clin Oral Implants Res. 2006; 17 (Suppl 2): 35-51.
- 33 Ridell A, Grondahl K, Sennerby L. *Placement of Branemark implants in the maxillary tuber region: anatomical considerations, surgical technique and long-term results*. Clin Oral Impl Res 2009; 20:94-98.
- 34 Rodriguez X, Mendez V, Vela X, Segala M. *Modified Surgical Protocol for Placing Implants in the Pterygomaxillary Region: Clinical and Radiologic Study of 454 Implants*. Int J Oral Maxillofac Implants 2012;27:1547-1553.
- 35 Romanos E, Bhumija G, Eckert E. *Distal Cantilevers and Implant Dentistry*. Int J Oral Maxillofac Implants 2012; 27:1131-1136.
- 36 Romeo E, Tomasi C, Finini I, Casentini P, Lops D. *Implant-supported fixed cantilever prosthesis in partially edentulous jaws: a cohort prospective study*. Clin Oral Impl Res 2009; 20:1278-1285.
- 37 Romeo, E., Lops, D., Margutti E., Ghisolfi, M., Chiapasco, M. & Vogel, G. *Implant-supported fixed cantilever prostheses in partially edentulous arches. A seven year prospective study*. Clinical Oral Implants Research 2003; 14:303-311.
- 38 Rosen A, Gynther G. *Implant treatment without bone grafting in edentulous severely resorbed maxillas: A long-term follow-up study*. J Oral Maxillofac Surg 2007;65:1010-1016.
- 39 Sanchez-Garces M, Costa-Berenguer X, Gay-Escoda C, Short Implants: *A Descriptive Study of 273 Implants*, Clinical Implant Dentistry and Related Research, Volume 14, Number 4, 2012 12;508-516
- 40 Summers RB. *The osteotome technique: Part 3. Less invasive methods of elevating the sinus floor*. CompendContinEduc Dent 1994; 15:698-708.
- 41 Tawil G, Younan R. *Clinical evaluation of short, machined-surface implants followed for 12 to 92 months*. Intl Oral Maxillofac Implants 2003; 5:894-901.
- 42 Telleman G, Raghoobar GM, Vissink A, den Hartog L, Huddleston Slater JJ, Meijer HJ. *A systematic review of the prognosis of short (<10 mm) dental implants placed in the partially edentulous patients*. J Clin Periodontol 2011; 38:667-676.
- 43 Testori T, Del Fabbo M., Capelli M., Zuffetti F, Francetti L., Weinstein R.L. *Immediate occlusal loading and tilted implants for the rehabilitation of the atrophic edentulous maxilla. One year interim results of a multicenter prospective study*. Clin Oral Implants Res 2008;19:227-232.
- 44 Topalo V, Atamni F, Sirbu D. *The elevation of the maxillary sinus floor through crestal approach with simultaneous insertion of endosseous dental implants*. Medicina Stomatologica 2009; No. 1(10):36-40.
- 45 Tulasne JF. *Osseointegrated fixtures in the pterygoid region*. In: Worthington P, Branemark P-I (eds). *Advanced Osseointegration Surgery: Applications in the Maxillofacial Region*. Chicago: Quintessence, 1992: 182-188.
- 46 Turvey, T.A. & Fonseca, R.J. (1980), *The anatomy of the internal maxillary artery in the pterygopalatine fossa: its relationship to maxillary surgery*. Journal of Oral Surgery 38: 92- 95.
- 47 Valeron et al. *Long-term Results in Placement of Screw-Type Implants in the Pterygomaxillary-Pyramidal Region*. Int J Oral Maxillofac Implants 2007; 22:195-200.
- 48 Yamakura T, Abe S, Tamatsu Y, Rhee S, Hashimoto M, Ide Y. *Anatomical study of the maxillary tuberosity in Japanese men*. Bull Tokyo Dent Coll 1998;38:287-292.
- 49 Zurdo J, Romeo C, Wennstrom JL. *Survival and complication rates of implant-supported fixed partial dentures with cantilevers: A systematic review*. Clin Oral Implants Re 2009;20(suppl4):59-66

Data prezentării: 07.08.2013.

Recenzen: Natalia Rusu

ÎNCĂRCAREA FUNCȚIONALĂ PRECOCE A IMPLANTELOR DENTARE DE STADIUL I ÎN CADRUL EDENȚAȚIILOR UNIDENTARE

Rezumat

Studiul a fost efectuat în baza protezării a 34 pacienți cu edențații unidentare în diferite sectoare ale maxilarelor, cărora le-au fost instalate 39 de implante de stadiul I. Rezultatele obținute au permis elaborarea unei metodologii de protezare a edențațiilor unidentare prin intermediul implantelor dentare de stadiul I cu încărcarea funcțională precoce a lor. Analiza datelor din studiu și a revistei literaturii demonstrează că:

1. restaurările protetice dento-implanto-purtate cu utilizarea implantelor de stadiul I prezintă o alternativă bună pentru tratamentul protetic a edențațiilor unidentare;

2. ancorarea dento-implantară este un remediu de tratament la fel de previzibil în timp ca și restaurările protetice cu sprijin pur implantar;

3. utilizarea implantelor de stadiul I scurtează termenele de reabilitare protetică;

4. reabilitare protetică cu utilizarea implantelor de stadiul I este mai ieftină fiind mai accesibilă pentru majoritatea pacienților.

Cuvinte cheie: edențație unidentară, implante de stadiul I, conexiune dento-implantară, încărcarea funcțională precoce.

Gumeniuc Aureliu,
asist. universitar
Catedra Stomatologie
Ortopedică
„Ilarion Postolachi”
USMF „N. Testemițanu”

Topalo Valentin,
d.hab.m.,prof. univ.
Catedra Chirurgie OMF
și Implantologie orală
„Arsenie Guțan”
USMF „N. Testemițanu”

Mostovei Andrei,
doctorand
Catedra Chirurgie OMF
și Implantologie orală
„Arsenie Guțan”
USMF „N. Testemițanu”