

Atypical pure sensory forms of chronic inflammatory demyelinating polyneuropathies

Eugen Gavriiliuc, MD, PhD, Vitalie Lisnic, MD, PhD, Professor

Department of Neurology No 1, Nicolae Testemitsanu State University of Medicine and Pharmacy
Chisinau, the Republic of Moldova

*Corresponding author: eugen.gavriiliuc@medpark.md

Manuscript received April 19, 2019; revised manuscript May 21, 2019

Abstract

Background: There are still not enough data on clinical and laboratory peculiarities of atypical chronic inflammatory demyelinating polyneuropathy (CIDP), ranging from only sensitive symptoms without weakness to asymmetric motor deficit. Recent epidemiological data do not clearly elucidate the percentage of cases with atypical CIDP from total CIDP types. Nerves conduction study, the gold standard in diagnosing demyelinating polyneuropathies has low sensibility for atypical forms of CIDP. The purpose of this study was determining the criteria for clinical and laboratory diagnosis of atypical sensory CIDP.

Material and methods: Two groups of study were identified: 30 patients with typical CIDP and 30 patients with atypical CIDP. All patients underwent nerves conduction studies, blood was drawn for biochemical tests, also electrophoresis and serum protein immunofixation were done. Fibular nerve biopsy was performed in 9 patients. Overall Neuropathy Limitation Scale (ONLS) questionnaire was used for the assessment of functional disability.

Results: Nerves conduction studies in cases with sensory CIDP show normal motor conduction velocity in 10 cases, and diminished only in 4 cases. Total ONLS in patients with sensory CIDP is equal to 1.85 ± 0.21 points compared to total 4.17 ± 0.240 points in patients with typical CIDP ($p < 0.001$).

Conclusions: Nerves conduction study is not a gold standard for diagnosis atypical sensory CIDP. According to functional scores results, sensory CIDP is less disabling compared with typical CIDP.

Key words: sensory CIDP, demyelination, functional tests, polyneuropathy.

Introduction

The classic form of chronic inflammatory demyelinating polyneuropathy (CIDP) is symmetrical damage of motor and sensory nerves; motor involvement is greater than sensory [1]. The mechanism of nerves damage is presumed to be immune mediated [2]. Recent epidemiologic data have shown that up to 35% of CIDP patients may have only sensory symptoms [3, 4].

Several clinical variants of CIDP have been reported widening the spectrum of this neuropathy. According to the European Federation of Neurological Societies (EFNS) and Peripheral Nerve Society (PNS) guideline (EFNS / PNS, revised in 2010) CIDP can be classified into two clinical forms: typical CIDP and atypical CIDP [5].

Atypical forms can be classified according to the clinical manifestations in 4 major groups: pure motor, pure sensory, multifocal and of distal symmetrical impairment [6,7]. The diagnostic criteria for these forms are however not well defined possibly explaining their variable frequency ranging from 1% to 49% in different series and the reported differences in their treatment response [8,9].

A recent study fulfilled in USA showed that the majority of community neurologists had familiarity with the clinical presentations of typical CIDP, but many thought that atypical phenotypes were more various than what have been described in guidelines [10]. The aim of this study was to

underline the clinical and paraclinical peculiarities of pure sensory CIDP.

Nerve conduction studies (NCS), the gold standard in diagnosing demyelinating polyneuropathies, have low sensitivity for atypical forms of CIDP, that's why it's necessary to identify new ways of diagnosis [11]. Often the clinical picture of a sensory CIDP can simulate idiopathic axonal polyneuropathy, losing opportunity of proper immunomodulation treatment with subsequent resolution of symptoms [12]. Additive tests are required to establish the correct diagnosis of sensory CIDP: lumbar puncture, somatosensory evoked potentials (SSEPs), magnetic resonance imagings of the proximal portions of the cervico-brachial plexus and lumbosacral plexus, if necessary sural nerve or fibular nerve biopsies [13].

Two particular forms of sensory CIDP are described in scientific papers:

a) Clinical picture with distal, symmetrical, sometimes painful paraesthesia with a predominant onset of the soles or hands (feeling of socks tied to the talocrural joints, feeling of sand between the toes and on the soles of the feet, sensation of invisible sandals on the feet) which then progress ascending to the level of the thighs. The neurological objective examination shows a thermo-algic hypoesthesia in socks and gloves, diminished or preserved deep tendon reflexes. Muscle strength according to Medical Research

Council (MRC) scale – 5 points in all limbs. Romberg sign is negative in all the patients [14].

b) Clinical picture of chronic, ataxic neuropathy associated with distal paraesthesia. Ataxia manifests predominantly during walking with the presence of the positive Romberg sign and advanced self-perception disorders. A generalized areflexia is observed. NCS show the reduction in nerve conduction velocity across multiple trunks, increased distal motor latency and increased proximal F wave latency). Conductions blocks are uncommon, which explains the presence of normal muscle strength – 5 points in all muscle groups according to the MRC scale [15].

Material and methods

Two study groups were identified: 30 patients with typical CIDP and 30 patients with atypical CIDP according to the EFNS/PNS guideline (revised 2010).

Clinical examination included the following scales: Overall Neuropathy Limitation Scale – (ONLS), INCAT sensory score, 9-hole peg test, 10 meters test, MRC scale [16,17]. NCS were performed in all the patients. A full routine biochemistry, electrophoresis and immunofixation of serum proteins, all spectrums of anti-myeline and anti-ganglioside antibodies were performed. The proximal segments of the sensory peripheral nervous system can only be assessed by SSEPs [18]. SSEPs were considered to be suggestive of proximal demyelination when they revealed: (i) a significant increase in radicular conduction time with normal distal conduction time in at least 1 nerve and/or (ii) absence of N9/N18 potential or N13/N22 potential and/or delayed proximal volleys (N9 or N18) with normal distal conduction time in at least 2 nerves [19].

Cerebral spinal fluid (CSF) macroscopic/microscopic examination was performed in all the patients. Fibular nerve biopsies were obtained under local anesthesia from the lateral and inferior part of the shank. 5 patients with typical CIDP and 4 patients with atypical CIDP underwent superficial peroneal nerve biopsies. The 5 centimeters long superficial peroneal nerve specimen was divided into three pieces: first piece was fixated in paraformaldehyde and stained with haematoxylin-eosin; second piece was fixated in glutaraldehyde and the subsequent generation of semi-thin sections were stained with toluidine blue; third piece was frozen in liquid nitrogen and stored at -80 degrees Celsius - for immunohistological research [20].

Semi-thin (0.5 μ m) sections allow much greater resolution than that provided by specimens embedded in paraffin and allow accurate quantification of demyelination markers: the presence of onion bulbs, decreased number and density of large and small myelinated fibers, decreased thickness of the myelin sheath [21,22]. Statistical analysis was performed using statistical methods Mann-Whitney and Fisher (SPSS statistics 20). Cases with $p \leq 0.05$ were considered statistically significant.

Results and discussion

The percentage of patients with atypical CIDP was the following: 10 patients with Lewis-Sumner syndrome represent 33% of patients with atypical CIDP, 6 patients with distal acquired demyelinating symmetric (DADS) polyneuropathy – 20% of patients and 14 patients with sensory CIDP – 47% of patients with atypical CIDP. Our results suggest that sensory CIDP represents the most frequent form of atypical CIDP.

From the group of 14 patients with sensory CIDP – 4 patients fulfilled the EFNS/PNS guideline 2010 criteria for NCS demyelination, 10 patients didn't fulfill these criteria but instead were selected according to the criteria of the French Group of CIDP Experts [2].

The mean age of onset of the disease in the group of patients with sensory CIDP is 57.71 years. The clinical course of the disease is less disabling in sensory CIDP than in cases with typical CIDP. 14 patients were diagnosed with sensory CIDP, 10 patients had a monophasic disease course, 2 patients had evolution in relapses and remissions, and only 2 patients presented progressive disease course. As compared to patients with typical CIDP forms: 6 cases with monophasic evolution, 6 patients with relapsing and remitting disease courses and 18 patients had progressive evolution.

Ataxia and numbness are the main symptoms of patients with sensory CIDP: all patients had numbness in the lower limbs and 7 patients had postural instability. No muscle weakness according to MRC scale was identified in sensory CIDP patients. In the group of patients with typical CIDP all patients had a predominant muscle weakness in the proximal regions of upper and lower limbs, postural instability had 24 from 30 patients with typical CIDP. Regarding positive sensory symptoms, feet constriction sensation predominates in 5 out of 14 patients with sensory CIDP versus 4 out of 30 patients with typical CIDP ($p < 0.05$). In 12 cases, pain was also described in addition to numbness. Deep tendon reflexes were diminished in 6 cases, in 3 cases only ankle jerk reflex was abolished, diffuse areflexia was observed in 5 cases.

Total ONLS in patients with sensory CIDP is equal to 1.85 ± 0.21 points compared to total ONLS 4.17 ± 0.240 points in patients with typical CIDP ($p < 0.001$). Patients with Lewis-Sumner forms of atypical CIDP and patients with typical CIDP have the longest time of fulfilling the 9-hole peg test (fig. 1). This means that functional ability of

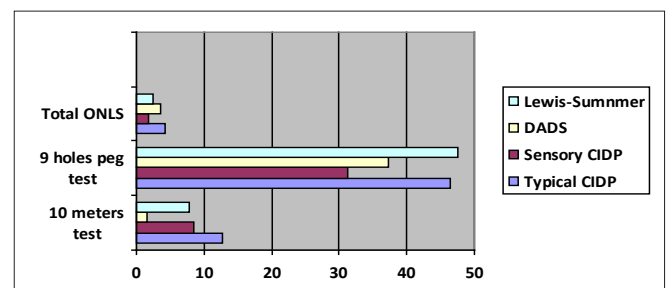


Fig. 1. The average values of functional assays in atypical CIDP subtypes compared to average values in typical CIDP.

their upper limbs is more affected than the functional ability of lower limbs. Also patients with DADS forms of atypical CIDP and patients with typical CIDP have the longest time of fulfilling the 10 meters test (fig. 1). It means that walking is most affected in this group of patients. Patients with sensory CIDP are less affected and have better prognosis of preserving their functional abilities.

According to NCS results presented in fig. 2, 3 – distal motor latencies, motor conduction velocities, proximal motor amplitudes, F waves latencies of median, ulnar, peroneal and tibial nerves are more preserved in atypical CIDP than in typical CIDP ($p < 0.001$). These data suggest a less demyelinating and degenerative process in atypical CIDP patients compared with typical cases of CIDP.

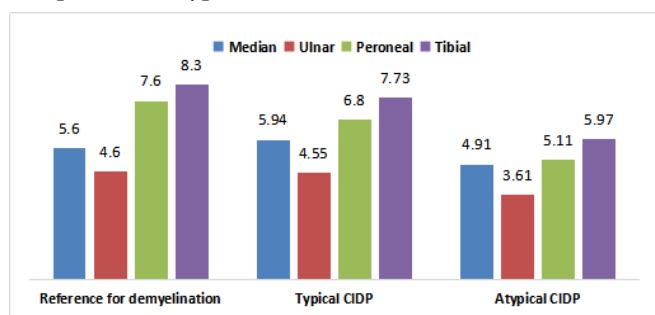


Fig. 2. Median values of distal motor latency (DML) in typical and atypical CIDP.

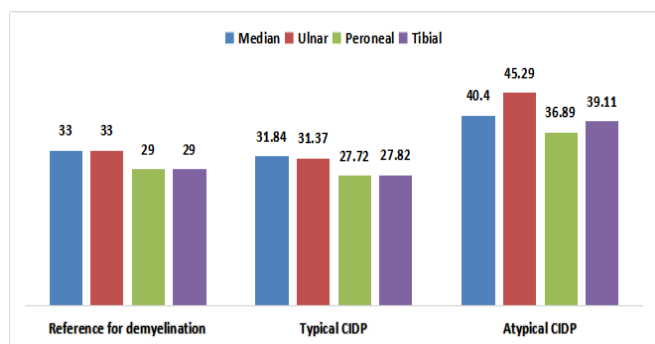


Fig. 3. Median values of motor conduction velocities (MCV) in typical and atypical CIDP.

NCS in 14 cases with sensory CIDP show normal motor conduction velocity in 10 cases, and diminished only in 4 cases. Also distal motor latency was diminished in 4 cases. Conduction block was present only in one case of sensory CIDP. Sensory conduction velocities in median and sural nerves were diminished in 6 cases. The amplitudes of the sensory nerve actions potentials (SNAP) in sural nerves were absolutely normal in 7 patients out of 14 with sensory CIDP (50% of patients with sensitive PDIC). From these 7 patients 6 out of them (43%) have so-called inverse ratio – amplitude of the sural nerve SNAP is greater than the amplitude of median nerve SNAP, which is an important supportive criteria for diagnosis of CIDP (fig. 4).

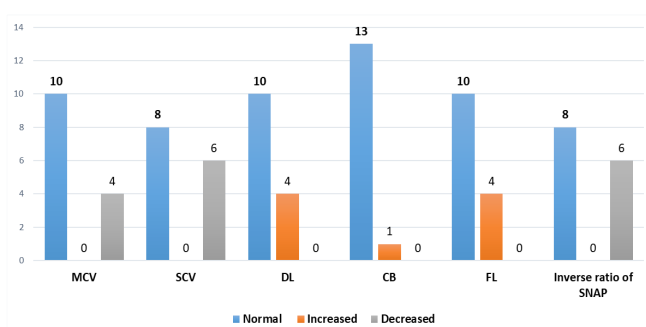


Fig. 4. MCV – motor conduction velocity (m/s), SCV – sensory conduction velocity, DL – motor distal latency (ms), CB – conduction block, FL – F-wave latency (ms), SNAP – sensory nerve action potential.

NCS show no evidence of demyelinating criteria for 10 patients with sensory CIDP, but these patients show clinical examination abnormalities that are not typical for chronic axonal polyneuropathies like: ataxia, generalized areflexia, distal hypoesthesia progressing toward the proximal portions of the limbs. Therefore, the SSEPs investigation was performed to demonstrate proximal demyelination, at pre- or post-ganglion levels, levels that are not accessible for the conventional NCS [23]. SSEP examinations were done in 10 patients diagnosed with sensory CIDP but with no signs of demyelination on NCS and compared with SSEP results of 10 patients with typical CIDP. 6 patients with sensory CIDP had prolonged radicular conduction time in at least 1 limb compared to 7 patients in typical CIDP ($p > 0.05$), and 7 had abnormal/delayed N9/N18 potentials and/or absent spinal potential in at least 1 limb compared to 8 patients with typical CIDP ($p > 0.05$). In summary, all patients with sensory CIDP had evidence of proximal demyelination on SSEPs with no statistical difference from the patients with typical CIDP.

CSF protein was elevated in 10 patients, ranging from 0.5-1.9 g/l, and normal in 4 cases. Data from our study are similar to the results of the French study [24]. CSF protein level was increased in 16 out of 22 patients with sensory CIDP (73% of patients studied) compared to 71% in our study.

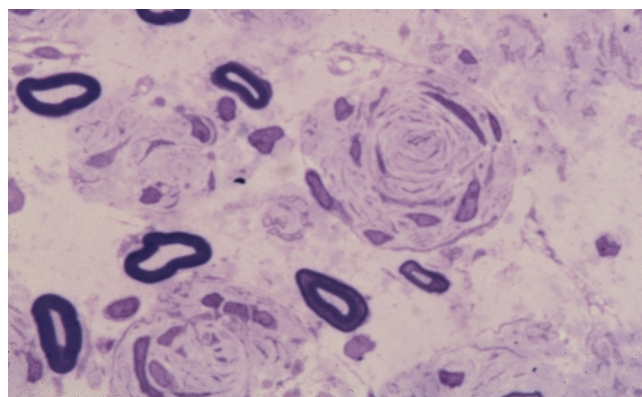


Fig. 5. Semi-thin transversal section of peroneal superficial nerve showing onion bulb formation in a patient with sensory CIDP.

Nerve biopsy findings were the following: reduction in myelinated fiber density was most frequent (100%), followed by demyelination (90%), inflammation (44%), and onion bulb formation (55%). Endoneurial inflammation was more frequent in the relapsing-remitting form (fig. 5).

Conclusions

1. NCS is the most important test used to diagnose demyelinating polyneuropathies. However, NCS are normal when demyelinating lesions are distributed proximally. This may lead to misdiagnosis or mismanagement.

2. SSEPs should be carried out in all cases of atypical sensory polyneuropathy (accompanied by ataxia, areflexia) to demonstrate the proximal demyelination (at pre- or post-ganglionic levels) not accessible for conventional NCS.

3. ONLS and 9 whole peg tests are efficient to evaluate the level of disability in patients with CIDP. According to ONLS scale, patients with typical CIDP are more impaired than sensory atypical CIDP patients.

4. Fibular nerve biopsy is performed only if the NCS don't bring any demyelinating findings, but the clinical evolution of the disease is progressive and disabling.

5. There is significant phenotypic variability in the clinical spectrum of CIDP suggesting that there are different immunopathological mechanisms at play. Future research is needed to identify disease markers.

6. NCS is not a sensitive test to diagnose sensory CIDP, in 70% of cases motor conduction velocities were not affected.

References

- Eftimov F, van Schaik I. Chronic inflammatory demyelinating polyradiculoneuropathy: update on clinical features, phenotypes and treatment options. *Curr Opin Neurol*. 2013;26(5):496-502.
- French CIDP Study Group. Recommendations on diagnostic strategies for chronic inflammatory demyelinating polyradiculoneuropathy. *J Neurol Neurosurg Psychiatry*. 2008;79:115-118.
- Ayrignac X, Viala K, Morizot Koutlidis R, Taieb G, Stojkovic T, Musset L, et al. Sensory chronic inflammatory demyelinating polyneuropathy: an under-recognized entity? *Muscle Nerve*. 2013;48(5):727-732.
- Lefter S, Hardiman O, Ryan AM. A population-based epidemiologic study of adult neuromuscular disease in the Republic of Ireland. *Neurology*. 2017;88(3):304-13.
- Joint Task Force of the EFNS and the PNS. European Federation of Neurological Societies/Peripheral Nerve Society Guideline on management of chronic inflammatory demyelinating polyradiculoneuropathy: report of a joint task force of the European Federation of Neurological Societies and the Peripheral Nerve Society - First Revision. *J Peripher Nerv Syst*. 2010;15(1):1-9.
- Doneddu PE, et al. Atypical CIDP: diagnostic criteria, progression and treatment response. Data from the Italian CIDP Database. *J Neurol Neurosurg Psychiatry*. 2019;90(2):125-132.
- Mathey EK, Park SB, Hughes RA, et al. Chronic inflammatory demyelinating polyradiculoneuropathy: from pathology to phenotype. *J Neurol Neurosurg Psychiatry*. 2015;86(9):973-85.
- Kuwabara S, Iose S, Mori M, et al. Different electrophysiological profiles and treatment response in 'typical' and 'atypical' chronic inflammatory demyelinating polyneuropathy. *J Neurol Neurosurg Psychiatry*. 2015;86(10):1054-9.
- Camdessanche JB, Jousserand G, Ferraud K, Vial C, et al. The pattern and diagnostic criteria of sensory neuronopathy: a case-control study. *Brain*. 2009;132(Pt 7):1723-1733.
- Gelinas D, Katz J, Nisbet P, England JD. Current practice patterns in CIDP: a cross-sectional survey of neurologists in the United States. *J Neurol Sci*. 2019;397:84-91.
- Nobile-Orazio E. Chronic inflammatory demyelinating polyradiculoneuropathy and variants: where we are and where we should go. *J Peripher Nerv Syst*. 2014 Mar;19(1):2-13.
- Sinnreich M, Klein CJ, Daube JR, et al. Chronic immune sensory polyradiculopathy: a possibly treatable sensory ataxia. *Neurology*. 2004;63(9):1662-1669.
- De Sousa EA, Chin RL, Sander HW, Latov N, Brannagan T. Demyelinating findings in typical and atypical CIDP: sensitivity and specificity. *J Clin Neuromusc Dis*. 2009;10(4):163-169.
- Léger JM, Bombelli F, Tran-Thanh H, Chassande B, Maisonobe T, Viala K. Chronic inflammatory demyelinating polyradiculoneuropathy: clinical heterogeneity and therapeutic perspectives. *Bull Acad Natl Med*. 2010;194(4-5):764-765.
- Van den Bergh PY, Rajabally YA. Chronic inflammatory demyelinating polyradiculoneuropathy. *Presse Med*. 2013;42(6 Pt 2):203-215.
- Graham RC, Hughes RAC. A modified peripheral neuropathy scale: the Overall Neuropathy Limitations Scale. *J Neurol Neurosurg Psychiatry*. 2006;77(8):973-976.
- Merkies I, Schmitz P, van Der Mechè F, van Doorn P. Inflammatory Neuropathy Cause and Treatment (INCAT) Group. Psychometric evaluation of a new sensory scale in immune-mediated polyneuropathies. *Neurology*. 2000;54:943-949.
- Yiannikas C, Vucic S. Utility of somatosensory evoked potentials in chronic acquired demyelinating neuropathy. *Muscle Nerve*. 2008;38(5):1447-1454.
- Kuwabara S, Misawa S. Chronic inflammatory demyelinating polyneuropathy: clinical subtypes and their correlation with electrophysiology. *Clin Exp Neuroimmunol*. 2011;2(2):41-48.
- Bosboom WM, van den Berg LH, Franssen H, Giesbergen PC, Flach HZ, van Putten AM, Veldman H, Wokke JH. Diagnostic value of sural nerve demyelination in chronic inflammatory demyelinating polyneuropathy. *Brain*. 2001;124(Pt 12):2427-2438.
- Kulkarni GB, Mahadevan A, Taly AB, Nalini A, Shankar SK. Sural nerve biopsy in chronic inflammatory demyelinating polyneuropathy: are supportive pathologic criteria useful in diagnosis? *Neurol India*. 2010;58(4):542-548.
- Vallat JM, Tabaraud F, Magy L, Couratier P. Importance of the nerve biopsy for the diagnosis of atypical forms of chronic inflammatory demyelinating polyradiculoneuropathy: 8 cases. *Bull Acad Natl Med*. 2003;187(2):387-399.
- Bril M, Banach M, Dalakas MC, Deng C. Electrophysiologic correlations with clinical outcomes in CIDP. *Muscle Nerve*. 2010;42(4):492-7.
- Viala K, Maisonobe T, Stojkovic T, et al. A current view of the diagnosis, clinical variants, response to treatment and prognosis in chronic inflammatory demyelinating polyradiculoneuropathy. *J Peripher Nerv Syst*. 2010;15(1):50-56.