

Treatment of inflamed skin wounds with biodegradable polymeric film “Biodep nano”

*¹Oleg Popadyuk, MD, PhD, Associate Professor; ²Roman Kutsyk; MD, PhD, Professor;
¹Maryana Voloshyn, MD, PhD, Associate Professor

¹Department of General Surgery, ²Department of Microbiology
Ivano-Frankivsk National Medical University, Ivano-Frankivsk, Ukraine

*Corresponding author: popadyukoleg@ukr.net

Manuscript received April 15, 2019; revised manuscript June 03, 2019

Abstract

Background: Experimental and clinical studies show that wound healing cannot be evaluated as optimally effective today. For the treatment of wounds today, various methods and means are used. Wound dressing was developed from both natural and synthetic materials. However, polymeric biodegradable materials, saturated with various active drugs, which are effective, easy to use, have insignificant disadvantages and need further study. The aim was to study the effectiveness of the use of biodegradable polymeric film “biodep nano” in the treatment of suppurable postoperative wounds of the skin in the experiment.

Material and methods: The research was carried out on 45 guinea-pigs of the species “Murchaky” in the clinical and biological base (Vivarium) of the Ivano-Frankivsk National Medical University, in accordance with the requirements for the maintenance and handling of laboratory animals. The pelvic wounds were simulated after *staphylococcus aureus* $2.0 \cdot 10^8$ KU/ml infection.

Results: The change in the wound area of the group IV and group V decreased slightly up to the third day, and after 7 days the area of the wound surface was reduced by 7% and 13.6% respectively. During the observation period, 14 days, the wound area in relation to the initial area was 35.5% in group IV and 43% in group V.

Conclusions: The biodegradable polymeric film “biodep nano” demonstrated high antimicrobial and wound healing properties in an experimentally simulated peptic cutaneous wound of the skin.

Key words: purulent wound, polymer films, treatment.

Introduction

Experimental and clinical studies show that the results of wound treatment cannot be estimated today as optimally effective, and success depends on their local treatment. It is important to search for new methods and means of local treatment of multi-directional actions that provide antimicrobial, anti-inflammatory and reparative effects [1].

The process of wound healing includes processes for restoring the barrier function of the skin, preventing dehydration and reducing the risk of bacterial infection [2].

The problem of effective healing of purulent wounds is also associated with high polyresistance of pathogenic microorganisms to modern antibacterial drugs [3].

Bacteria die under the action of antibiotics and antiseptics, which are used for wound dressing. In general, antibiotics for local wound therapy are not recommended because of minimal efficacy and also do not reach the bactericidal concentrations in situ, thus they can form resistant strains and further sensitization. However, in some indications, local antibiotic use still plays an important role in the clinical management of specific infections (e. g., keratitis, conjunctivitis, and otitis media). In the case of such wound infections, as a rule, systemic use of antibiotics is recommended [4].

For the treatment of wounds today, different methods and means are used. Wound dressing was developed

from both natural and synthetic materials. The ideal material should be elastic, maintain the moisture and pH in the wound environment, prevent bacterial contamination and promote painless and rapid healing of the wounds [5].

For example, the latest silk biomaterial bandages consisting of nano-sized silk fibers showed good result *in vivo* studies in treating skin wounds in mice [6].

However, polymeric biodegrading materials, saturated with various active drugs, which are effective, easy to use, have pitfalls and require further study [7, 8].

For the treatment of purulent wounds of different genesis, we have developed a biodegradable polymer film that contains nanosized zinc oxide and nanosized hydrated fullerene C_{60} .

Our comparative experimental studies *in vitro* have shown that zinc nanoxide is a highly effective antimicrobial agent in both gram positive and gram negative pathogen flora [9].

The first fullerenes of the C_{60} and C_{70} were discovered in 1985, and almost immediately fullerenes attracted the attention of many researchers, including from the point of view of the possibility of their use in biology and medicine [10, 11].

The biological activity of fullerene is due, of course, to its physical and chemical properties, and therefore it is capable

of illuminating the properties of an oxidant, while in the dark it acts as a highly active antioxidant due to its ability to “capture” free radicals [11].

Goal: To study the effectiveness of using a biodegenerative polymeric film “Biodep nano” with nanosized hydrated fullerene C_{60} in the treatment of inflamed wounds of the skin in the experiment.

Material and methods

The study was conducted on 45 guinea-pigs of the species “Murchaky” weighing 323 (303-346) grams, which were on a balanced diet of clinical and biological base (Vivarium), Ivano-Frankivsk National Medical University, according to sanitary and hygienic standards (Scientific and Practical Guidelines for the Maintenance and Operation of Laboratory Animals, 2002), in accordance with the requirements of the General Ethical Principles of Animal Experiments, approved by the National Congress on Bioethics (September 20, 2004, Kyiv, Ukraine), agreed upon with “The rules of the

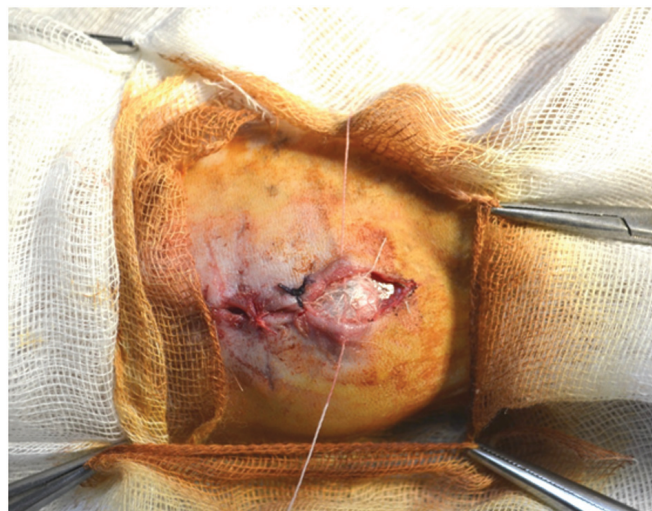


Fig. 1. The bottom culture of *Staphylococcus aureus* on the wound.

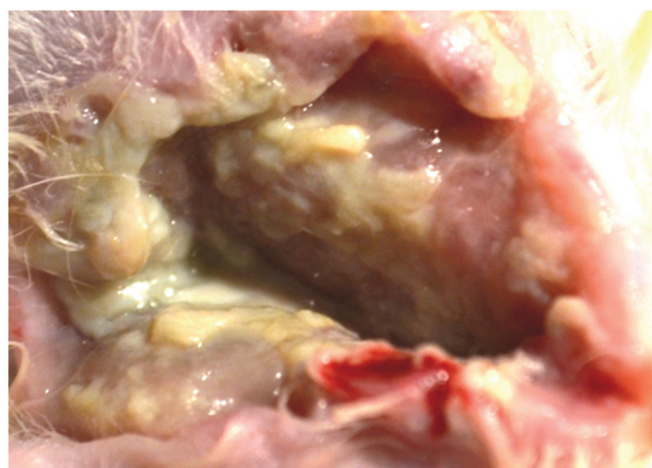


Fig. 2. The purulent wound after removed napkins with purulent contents and purified contents by physically sterile tupper.

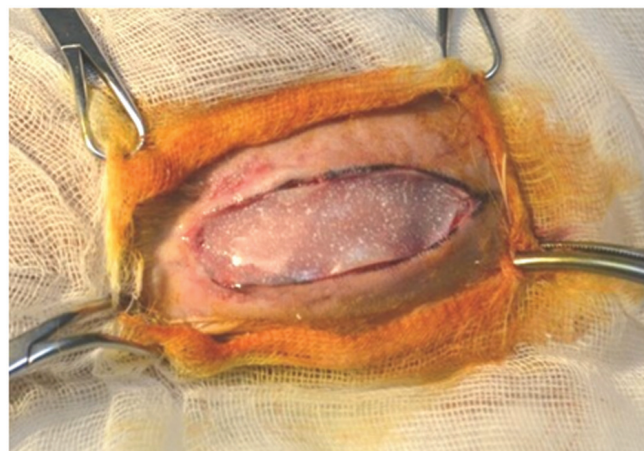

Fig. 3. Attachment of a polymer film to the wound.

slaughter of animals using experimental animals”, approved by the order of the Ministry of Health of Ukraine and the Law of Ukraine “On the Protection of Animals from Cruel Treatment” (No 1759-VI of 15.12.2009) and the rules of the European Convention for the Protection of Vertebrate Animals used for experimental and other scientific purposes [12].

For reproduction of puffy skin injury to animals under general anesthesia of oxybutyrate by the calculation of 0.15 ml per 100 g of animal weight in the interlopatal region, a cutaneous wound of skin covering 50 mm long was modeled. At the bottom of the wound, a cloth dampened with a culture of *Staphylococcus aureus* (concentration $2.0 \cdot 10^8$ KU/ml) was placed on the wound and 10 mm apart of the nodule seams were applied, the wound was treated with a betadine solution from the outside (fig. 1). 3 days later we removed seams, napkins with purulent contents and purified the wound from purulent contents by physically sterile tupper, washing with 0.9% physiological saline solution of sodium chloride (fig. 2). A sterile napkin was applied and fixed with a fixing tape on paper basis in two places.

Animals were divided into four groups: group I intact (5 animals); group II (10 animals) were not infected; group III (10 animals) wounds were infected and managed without additional treatment with the replacement of sterile gauze napkins every other day; group IV (10 animals) used curasorb ZN wounds; group V (10 animals) applied a biodegradable polymeric film “Biodep nano”, which was additionally saturated with a solution of hydrated fuller C_{60} .

The area of the wound was measured at the beginning of the study and according to the specified observation dates at 3,7,14 and 21 days.

The curasorb ZN wound coat used in the control group is made in the form of a plate, consisting of natural alginate fibers and contains zinc [13].

Results

After infecting and waiting for the time required to form purulent wound contents, it was found that the *Staphylococcus aureus* content in the wound exudate was $4 \cdot 10^8$ KU/ml.

After removal from the wound of wipes with the causative agent and purification of purulent contents, films were applied and observed (fig. 3).

By the 3rd day in the group III of infected animals, the wounds had purulent contents, swollen edges, and a significant excretion of the exudate and an increase of the wound area.

The decrease in the number of bacteria by the 3rd day was recorded in group IV and V, in contrast to group III, in two orders of magnitude, where the level of bacteria remained high, indicating an active increase in their number in the wound without a specific local antiseptic effect.

Wound coatings used in group IV and group V showed high sorption ability and gradually degraded the active substance. Visually, in animals of these groups, the wounds were well cleaned, and their bottom had virtually no purulent content. More pronounced sorption and regenerative effects were observed in group V up to the 7th day, as evidenced by the results of microbiological studies and measurement of the wound area. At day 7, the level of bacteria in the wound of group IV decreased sharply by 3 orders of magnitude and in the group V by 4 orders of magnitude comparatively. This testified to the high efficiency of absorbent roofing materials saturated with antiseptic agents. On the 14th day the pathogen was sown only in the group without treatment (tab. 1). One animal in this group died on the 7th day, one on the 14th day.

The change in the wound area of the group IV and group V decreased slightly until the third day, and by the 7th day the area of the wound surface was reduced by 7% and 13.6%, respectively. During the observation period, 14 days, the wound area in relation to the initial area was 35.5% in group IV and 43% in group V.

The results obtained by us testify to the effective influence of the biodegradable coating on the healing of the cutaneous wounds of the skin of infected *Staphylococcus aureus*. The closure of the wound defect occurred most rapidly by the application of our innovative roofing material for wounds in the form of a biodegradable nanofill polymer film saturated with zinc oxide and hydrated fullerene C₆₀. By the 21st day, the free area of the wounds of the animals of the group where the film was applied was 9.6%, which is critically low and indicates the high level of film exposure to wound healing (tab. 2).

Discussion

Local antiseptic is an anti-infectious treatment of choice. In the case of wound infections, it is advisable to use a local antiseptic to immediately stop the microbial replication, as well as the appropriate spread of the infection in the wound environment. This is of particular importance in the treatment of infections by multi-resistant strains such as *Staphylococcus aureus* resistant to methicillin, resistant to enterococci, and organisms that produce the extended spectrum of betalactamase [4].

The synthesis of the polymer proposed by us became possible due to microwave irradiation in accordance with the timelines, which facilitated the polymerization of the applied components. Thanks to the peculiarities of the composition and manufacturing technology, it was possible to achieve elasticity, gradual degradation, the required steam and moisture permeability. At the final stage of manufacture, zinc nanoparticles were added to the film, which provided excellent antimicrobial properties. Thus, on the third day, the concentration of *Staphylococcus aureus* was such that the pathogen was not at risk, which compared with uninfected

Table 1

The level of bacterial contamination of wounds in different terms of observation

Group	Infection	Terms of observation, the day				
		0	3	7	14	21
		Level of microbial contamination, CFU / ml				
II	-	-	-	-	-	-
III	2,0*10 ⁸	(4.1±0.5)*10 ⁸	(5.1±3.6)*10 ⁷	(6.6±2.4)*10 ⁶	(6.1±6.2)*10 ⁵	-
IV		(4.7±0.7)*10 ⁸	(3.6±0.4)*10 ⁵	(2.9±0.5)*10 ³	-	-
V		(6.7±2.8)*10 ⁸	(3.1±0.3)*10 ⁵	(2.1±0.7)*10 ²	-	-

Table 2

Level of wound area at different observation periods

Group	Terms of observation, the day				
	0	3	7	14	21
	area S, mm ²				
II	500(488-514)	453(444-463)	357(344-365)	149(144-154)	
III	521.5(509-534)	555.5(528-580)	510(487-530)	443.5(401-459.5)	265(255-281)
IV	534.8(593-578)	528(514-575)	497(482-505)	345(336-374)	84(78-96)
V	540.3(528-575)	508(480-517)	466(450-474)	307(280-336)	21(14-26)

wounds showed an effective stable effect of the polymer. The results of the application of polymer materials in the world literature confirm the results of the data, namely, the use of nanosized metal oxides such as MgO, TiO₂, Al₂O₃, CuO, SeO₂ and ZnO is highly effective against pathogenic strain-forming strains of *Staphylococcus aureus* [14].

The results of the study of the properties of polymeric materials in the treatment of wounds presented in literature confirmed the high efficiency of polymers due to high sorption and moisture-retaining properties, but at the same time revealed shortcomings and the need for their further improvement [5].

The results obtained by us showed and confirmed the effectiveness and feasibility of the use of fullerene in the treatment of wounds. The assertion that fullerene C₆₀ is an antioxidant is found in scientific literature. Thus, studies have demonstrated that the surface modified by fullerene has a pronounced antioxidant effect [15].

Prospects: The polymer material we have developed in the form of a film can be manufactured in different sizes and thicknesses, has good elasticity and takes the form of a wound or other surfaces, releases the active substance gradually over several days, thus reducing the bonding tarmines and their quantity, possesses moisture-preserving and sorption properties. That is why this polymer has the prospect of further research, study and application in surgery.

Conclusions

1. Biodegradable nanocontaining polymeric film “Bio-dep-nano”, which is additionally saturated with hydrated fullerene C₆₀, showed high antimicrobial properties in relation to pathogenic strains of *Staphylococcus aureus* in a comparative study with known roofing materials in experimentally simulated purulent wounds of the skin.

2. The proposed new biodegradable polymeric material is a promising means of local wound healing, requiring further study and implementation in practical surgery.

References

1. Mnikhovich MV, Eremin NV. Eksperimental'no-morfologicheskii analiz gistogeneza kozhnoi rany pod vlianiem nizkointensivnogo lazernogo izlucheniia [Experimental and morphological analysis of histogenesis of skin wounds under the influence of low-intensity laser radiation]. Vestnik Novykh Meditsinskikh Tehnologii [J New Med Technol] (Tula, Russia). 2013;20(2):113-120. Russian.
2. Rowan MP, Cancio LC, Elster EA, Burmeister DM, et al. Burn wound healing and treatment: review and advancements. Crit Care. 2015;(19):243. doi: 10.1186/s13054-015-0961-2.
3. Dauntan C, Kothari S, Smith L, et al. A history of materials and practices for wound management. Wound Pract Res. 2012;20(4):174-186.
4. Daeschlein G. Antimicrobial and antiseptic strategies in wound management. Int Wound J. 2013;10 Suppl 1:9-14.
5. Wiegand C, Hipler UC. Polymer-based biomaterials as dressings for chronic stagnating wounds. Macromol Symp. 2010;294:1-13.
6. Gil ES, Panilaitis B, Bellas E, Kaplan DL. Functionalized silk biomaterials for wound healing. Adv Healthc Mater. 2013;2(1):206-217.
7. Hakkarainen T, Koivuniemi R, Kosonen M, et al. Nanofibrillar cellulose wound dressing in skin graft donor site treatment. J Control Release. 2016;244(Pt B):292-301.
8. El-Feky GS, Sharaf SS, El Shafei A, et al. Using chitosan nanoparticles as drug carriers for the development of a silver sulfadiazine wound dressing. Carbohydr Polym. 2017;158:11-19. doi: 10.1016/j.carbpol.2016.11.054.
9. Popadyuk OY. Antimicrobial effect of biodegradable wound healing nano-containing polymer materials. Mold Med J. 2017;60(1):35-38.
10. Kroto HW, Heath S, O'Brien SC, Curl RE, Smalley RE. C₆₀: Buckminsterfullerene. Nature. 1985;318:162-163.
11. Piotrovskii LB, Kiselev OI. Fullereny v biologii [Fullerenes in biology]. SPb: Rostok; 2006. 336 p. Russian.
12. Popadyuk OY. Patomorfologichni osoblivosti vidnovlennia poskod-zhenikh miakikh tkanin iz zastosuvanniam biorozchinnoi polimernoi plivki v eksperymenti [Pathomorphological features of restoration of damaged soft tissues using a biodegradable polymer film in an experiment]. Ukrayins'kii Zhurnal Khirurgii [Ukr J Surg]. 2013;(4/23):67-72. Ukrainian.
13. Thomas S. Surgical dressings and wound management. Cardiff: Medetec; 2010. 708 p.
14. Brayner R, Ferarri-Iliou R, Brivois N, Djediat S, Benedetti MF, Fiévet F. Toxicological impact studies based on *Escherichia coli* bacteria in ultra-fine ZnO nanoparticles colloidal medium. Nano Lett. 2006;6:866-870.
15. Piotrovskii LB, Eroshkin MIu, Eroshkina EM, Dumpis MA, et al. Mekhanizmy biologicheskogo deistviia fullerenov - zavisimost' ot agregatnogo sostoianiiia [Mechanisms of biological action of fullerenes – dependence on the aggregate state. Psikhofarmakologiya i Biologicheskaya Narkologiya [Psychopharmacology and Biopharmacology] (St. Petersburg, Russia). 2007;7(2):1548-1554. Russian.