

ORIGINAL RESEARCH

DOI: 10.5281/zenodo.3404084
UDC: 611.134.1

Open Access

**The anatomical variations of the posterior circumflex humeral artery***¹Dan Croitoru, MD Undergraduate; ¹Zinovia Zorina, MD, Assistant Professor;
¹Galina Certan, MD, PhD, Associate Professor; ²Mihaela Galescu, MD; ³Eugen Cerevan, MD¹Department of Human Anatomy, Nicolae Testemitsanu State University of Medicine and Pharmacy²Division of Functional Diagnostic, Republican Center of Medical Diagnostics³Division of Vascular Surgery, Timofei Mosneaga Republican Clinical Hospital
Chisinau, the Republic of Moldova

*Corresponding author: danioncroitoru@gmail.com

Manuscript received April 01, 2019; revised manuscript June 05, 2019

Abstract**Background:** Arteries have a very variable origin, diameter, path, correlation, branching and terminal pattern. An honorable mention is necessary for the individual anatomical variations of the axillary artery branches, because this is a spot of frequent vascular lesions that are the result of blunt weapon traumas, proximal humerus traumas and glenohumeral dislocations.**Material and methods:** The morphologic variability of the posterior circumflex humeral artery was studied on a male adult cadaver, on 10 angiographies and 9 ultrasonographies of the upper limb arteries which also constituted the study poll. The origin variations were identified in 3 cases.**Results:** In correlation with gender, and the body part that is taken into consideration, the posterior circumflex humeral artery morphological variations are found more often in the male gender, predominantly on the right upper limb.**Conclusion:** The posterior circumflex humeral artery has a wide range of anatomical variations. More frequently the anatomical variations are found on the right upper limbs of male gender. The obtained data will become useful in the approaches of the axillary artery during arteriographies and also in choosing the right surgical intervention tactic on this topographical region.**Key words:** axilla, posterior circumflex humeral artery, arterial variation.**Introduction**

The axillary artery through its branches supplies the anatomical formations in the deltoid region, the lateral thoracic wall and the superior portion of the arm.

In the classical description of the axillary artery ramification, the specialized literature relates about a pattern of branching that implies 6 main branches and 5-6 accessory branches [1, 2].

The main branches have a very high variation not only in origin but also in path and number. The most variable of them being the lateral thoracic artery, posterior circumflex humeral artery and subscapular artery [3].

The posterior circumflex humeral artery has its origin in the infrapectoral portion of the axillary artery, 1-2 cm superiorly to the superior margin of the latissimus dorsi muscle insertion. During its path, to the posterior surface of the quadrilateral space, it passes infero-laterally between the subscapular muscle and the latissimus dorsi muscle, being variable in its position towards the axillary nerve, that in most cases is superior to the artery, in less cases inferiorly or between its branches in cases when the artery splits at the quadrilateral space level [4].

In the subdeltoidian space, the branches of the posterior circumflex humeral artery are distributing collaterally supplying the glenohumeral articulation, the deltoid muscle,

the teres major and minor muscles, the long head of the arm triceps muscle [5].

In the surgical neck traumas, the posterior circumflex humeral artery can be traumatized along with the axillary nerve, leading to major complications of the gleno-humeral dislocations, which are present in 15.8 – 48% of cases [6].

According to the data found in the specialized literature, surgical neck traumas represent 6% of the registered fractures, where in 64% of cases the axillary nerve is traumatized [7].

Along with that, the anatomical variations of the posterior circumflex humeral artery became more important in the last years, because of the gradual growth of the vascular surgical interventions, radiological interventions and not less importantly – reconstructive surgical interventions. Many errors in medical practice are caused by the misrecognition of the anatomical variation of these arteries [8, 9].

The study goal consists in the recognition and description of the anatomical variations of the posterior circumflex humeral arteries depending on the gender and the part of the body that is studied.

Material and methods

The study of the posterior circumflex humeral artery was performed on a male adult cadaver fixed in 10% formalin

and also on 10 angiographies (6 selective angiographies and 4 angio-CT) and 9 ultrasonography images (Vascular Dopplerographies) of the upper limb arteries that were obtained from the database of the Republican Center of Medical Diagnostics and the Timofei Mosneaga Republican Clinical Hospital.

The upper limb arteries of the cadaver were studied using the anatomical dissection method; we were able to establish the origin, number, path and correlation with the adjacent anatomical structures.

The imagistic poll that was implied in the study included 10 males and 8 females (one patient of female gender had a bilateral ultrasonography of the upper limb arteries), the age poll was between 49-65 years.

The arteries of the right axilla were studied at 11 patients (6 males and 5 females), and the left axilla – at 8 patients (4 males and 4 females).

The CT Angiographies were made on a Lightspeed VCT with 64 slices; the tomographic sections were made with a 5.0 mm thickness, the reconstructions – 1.5 mm in “Angio-RunOff” regime, MPP, MIP Thin and VRT. The imagistic study with this method offered us a very accurate topography of the posterior circumflex humeral artery, and the 3D reconstruction highlighted its origin.

The landmark for the recognition of the posterior circumflex humeral artery was the subscapular artery and the humerus, which helped us to identify the level and type of branching, and its anatomical variations.

Results and discussion

During the upper limb dissection we identified anatomical variations on the infrapectoral portion of the right axillary artery, while on the left upper limb, we found a classical pattern of the axillary artery branches. The posterior and anterior circumflex humeral arteries have their origin from a common arterial trunk, which emerges from the lateral hemicircumference of the axillary artery. The common trunk length constituted 0.4 cm, the external diameter – 0.64 cm. The posterior circumflex humeral artery had a 0.45 cm diameter and crossed the axillary nerve antero-superiorly, the anterior circumflex humeral artery – a smaller diameter of 0.15 cm and a transverse path that was following the surgical neck of the humerus.

The subscapular artery with an external diameter of 0.52 cm before its usual bifurcation (into the circumflex scapular artery and the thoracodorsal artery), launched 2 muscular branches that had a relatively big diameter (0.31 cm and 0.24 cm) and an unusual path.

The first muscular branch had its origin 0.5 cm inferiorly from the subscapular artery origin, following up to the superior scapular angle where it realised an anastomosis with the suprascapular artery, launching on its path 2 branches that penetrated the subscapular muscle.

The second muscular branch had its origin 2 cm inferiorly from the subscapular artery origin, it crossed with an oblique trajectory the subscapular muscle from the anterior

or side, and on its middle portion it penetrated the muscle (fig. 1).

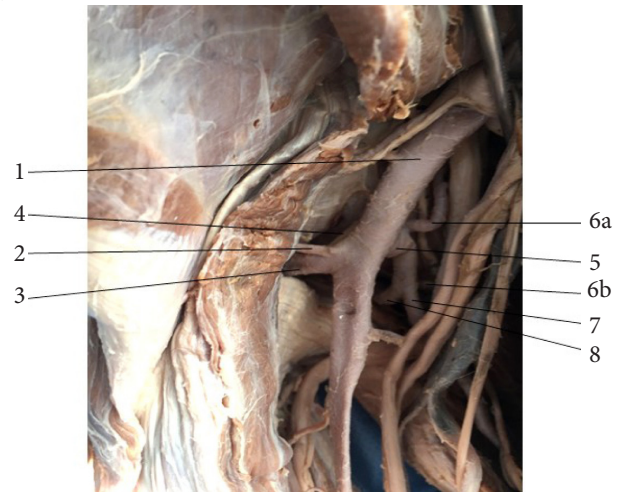


Fig. 1. Arteries of the axilla. 1 – axillary artery, 2 – anterior circumflex humeral artery, 3 – posterior circumflex humeral artery, 4 – axillary nerve, 5 – subscapular artery, 6a, 6b – muscular branches, 7 – thoracodorsal artery, 8 – circumflex scapular artery (Dissected by Zinovia Zorina).

The studied ecographic images of the upper limb offered us classical data that are relevant to the morphology and topography of the posterior circumflex humeral artery and no anatomical variations were identified, while the study of the angiographies offered us possibilities in their recognition. A variation model of the posterior circumflex humeral artery was identified at 3 upper limbs: 2 from the right side (one of male gender, the second of female gender) and 1 from the left side, of male gender.

The apparition of different anatomical variations of the posterior circumflex humeral artery can be caused by genetic factors or by the disturbance in the development of the primitive arterial axis of the upper limb, that takes place during the embryonic stage, also we can mention local factors like the fetus position, early limb movements and unusual muscular development [10].

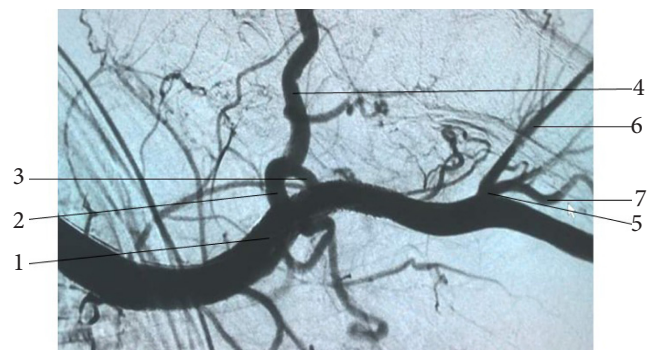


Fig. 2. Selective angiography. 1 – axillary artery, 2 – common trunk I, 3 – subscapular artery, 4 – posterior circumflex humeral artery, 5 – common trunk II, 6 – anterior circumflex humeral artery, 7 – deep brachial artery.

In the first case of a left upper limb of male gender, the origin of the posterior circumflex humeral artery and sub-

scapular artery was from a common trunk, that was emerging from the subpectoral portion of the axillary artery, and inferiorly, a common trunk from the brachial artery that was splitting into the anterior circumflex humeral artery and the profound brachial artery was identified (fig. 2).

The common arterial trunks appear because of the vasculogenesis disturbances, the consequences that are following, most commonly are related to unusual paths of the primary vascular plexus and fusion of the blood vessels that usually are solitary [11].

According to the literature data, the posterior circumflex humeral artery very often forms a common trunk with the subscapular artery, in 15.7 – 26% of cases [12].

In the second case, at the right upper limb of male gender was identified a common trunk that splits into the anterior and posterior circumflex humeral. This trunk has its origin from the third portion of the axillary artery, from its lateral hemicircumference, next to the subscapular artery. The anterior circumflex humeral artery had a smaller caliber and a sinuous ascendant path (fig. 3).

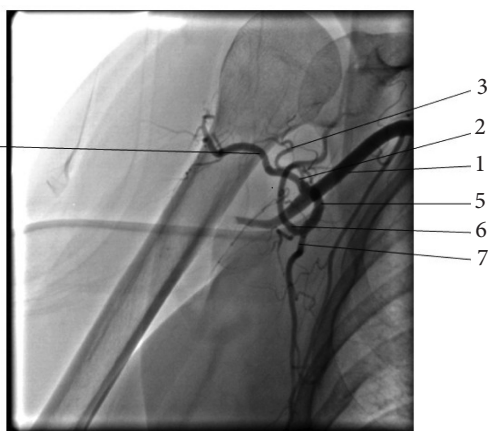


Fig. 3. Selective angiography. 1 – axillary artery, 2 – common trunk, 3 – anterior circumflex humeral artery, 4 – posterior circumflex humeral artery, 5 – subscapular artery, 6 – circumflex scapular artery, 7 – thoracodorsal artery.

Saeed M. [13] reported about the existence of a common trunk that splits into the posterior and anterior circumflex humeral arteries and the subscapular arteries in 3.8% of cases, and Astik R. [14] mentioned about a higher incidence of this variant for the female gender.

Mahendra K. [15] describes a common trunk, identified at the left upper limb of a male cadaver of adult age during a routine dissection that emerges from the subpectoral portion of the axillary artery and branches into the lateral thoracic artery, the thoracoacromial artery and subscapular artery. The subscapular artery is also branching into circumflex scapular artery, thoracodorsal artery and the posterior and anterior circumflex humeral arteries. In the third case, on a right upper limb of female gender was identified a common trunk that emerges from the postsclenic portion of the subclavian artery that subsequently splits into the posterior circumflex humeral artery and the profound brachial

artery. The path of the posterior circumflex humeral artery before the quadrilateral space was straight, after that it was sinuous (fig. 4).

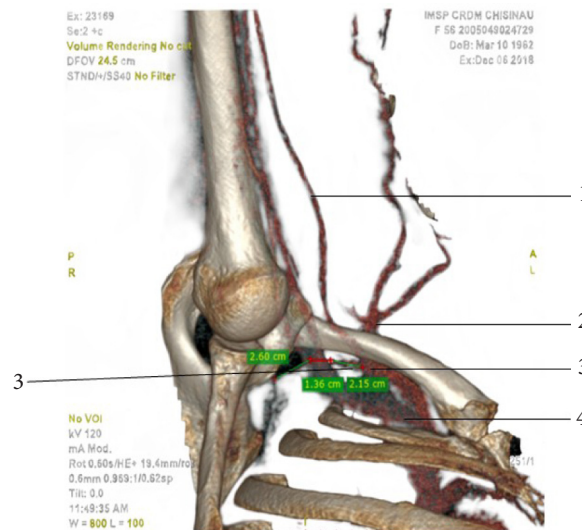


Fig. 4. Angiography with computerized tomography. 1 – profound brachial artery, 2 – thyrocervical trunk, 3 – common trunk, 4 – subclavian artery, 5 – posterior circumflex humeral artery.

In specialized literature the presence of such a trunk that had a diameter of 0.5 cm, was reported by Rajani Singh into a study of case [16].

By Kovalevich K. [12] reports, the posterior circumflex humeral artery is a branch of the axillary artery only in 40 – 62.8%, in other cases different origin variations are present.

The 3D reconstruction of the arteries offered us the possibility to perform a morphometry of the common trunk and its branches from an anterior and posterior aspect, measuring the length, diameters and their angle of emergence (tab. 1).

Table 1

Morphometric parameters of the variational arteries in the axillar region

N/o	Morphometric parameters	ScvA	CT	PCHA	PBA
1.	Length, cm	5.01	3.75	4.48	14.42
2.	Internal diameter, cm (anterior aspect)	1.26	0.52	0.38	0.41
3.	Internal diameter, cm (posterior aspect)	1.36	0.48	0.33	0.49
4.	Angle of emergence, °		90	85	55

Note: ScvA – subclavian artery; CT – common trunk; PCHA – posterior circumflex humeral artery; PBA – profound brachial artery.

The number of variations of the posterior circumflex humeral artery was identified at 2 right upper limbs of male gender. On one of these limbs, 2 posterior circumflex humeral arteries were identified; the first artery had its classical origin, from the subpectoral portion of the axillar artery, the second – from the profound brachial (fig. 5).

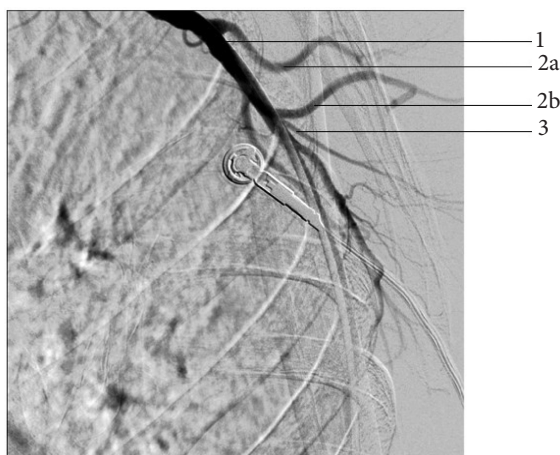


Fig. 5. Selective angiography. 1 – axillary artery, 2a, 2b – posterior circumflex humeral arteries, 3 – deep brachial artery.

Daimi S. [17] reports about a double posterior circumflex humeral artery in 1.28% of cases, and Gadzhieva F. [18] about its origin from the subscapular – in 23% of cases.

The exposed data from the specialized literature reports about the laterality character of the anatomical variations of the axillary artery and its branches, it relates to the fact that they are 2 times more often on the right upper limb opposing the left upper limb and 2.5 times more often only on one upper limb rather than on both [19, 20, 21].

Conclusions

1. The posterior circumflex humeral artery has a wide range of anatomical variations.

2. More frequently the anatomical variations are found on the right upper limbs of male gender.

3. The obtained data will become useful in the approaches to the axillary artery during arteriographies and also in choosing the right surgical intervention tactic on this topographical region.

References

1. Uzun A, Seelig LL Jr. The anastomotic artery connecting the axillary or brachial artery to one of the forearm arteries. *Folia Morphol.* 2000;59(3):217-220.
2. Stefanet M. *Anatomia omului* [Human anatomy]. 2nd ed. Vol. 3. Chisinau: Medicina; 2013. 428 p. Romanian.
3. Zorina ZA, Catereniuc IM. Variantnaia anatomii arterii verkhnikh konechnosti i ee vizualizatsiia sovremennymi metodami [Variant anatomy of the arteries of the upper extremities and its visualization with modern methods of research]. In: [Proceedings of the Republican international scientific-practical conference dedicated to the 60th anniversary of the Grodno State Medical University; 2018 September 28; Grodno]. Grodno; 2018. p. 14-16. Russian.
4. Ulmeanu D, Bordei P. Anatomia topografică și imagistică a membrilor [Topographic and imaging anatomy of the limbs]. Constanța: ExPonto; 2000. 233 p. Romanian.
5. Cascun N, Sarikcioolu L, Ozgur B, et al. Arterial, neural and muscular variation limb. *Folia Morphol.* 2005;64(4):347-352.
6. Avis D, Power D. Axillary nerve injury associated with glenohumeral dislocation. *EFORT Open Rev.* 2018;3(3):70-77.
7. Schumaider A, Gawe B. Proximal humerus fractures: evaluation and management in the elderly patient. *Geriatr Orthop Surg Rehabil.* 2018;9:215-218.
8. Robinson CM, Khan L, Akhtar A, Whittaker R. The extended deltoid-splitting approach to the proximal humerus. *J Orthop Trauma.* 2007;21(9):657-662.
9. Gadzhieva FG. Otsenka variantnoi anatomii podmyshechnoi i plechevoi arterii [Review of the variant anatomy of the axillary and brachial arteries]. In: [Actual issues of morphology: Materials of the International Scientific Conference dedicated to the birth centenary of Professor B. Z. Perlin; 2012 September 20-22; Chisinau]. Chisinau; 2012. p. 216-219. Russian.
10. Aughsteeen AA, Hawamdeh HM, Al-Khayat M. Bilateral variations in the branching pattern of brachial artery. *Int J Anat Var.* 2011;4:167-170.
11. Arey LB. *Development of the arteries*. In: Arey LB. *Developmental anatomy*. 6th ed. Philadelphia: Saunders; 1954. p. 375-377.
12. Kovalevich KM. Anatomicheskaiia izmenchivostii arterii verkhnei konechnosti pri sindromakh Patau, Edwardsa, Dauna i anencefalii: avtoreferat dissertatsii [Anatomical variability of the arteries of the upper limb in the syndromes of Patau, Edwards, Down, and anencephaly: abstract of dissertation]. Leningrad; 1991. p. 17-25. Russian.
13. Saeed M, Rufai AA, Elsayed SE, Sadiq MS. Variations in the subclavian-axillary arterial system. *Saudi Med J.* 2002;22(2):206-12.
14. Astik R, Dave U. Variations in branching pattern of axillary artery: a study in 40 human cadavers. *J Vasc Bras.* 2012;11(1):12-17.
15. Mahendra KP, Saim H, Sarangdhar SH. Variation in branching pattern of the axillary artery – a case report. *Int J Anat Var.* 2013;6:47-48.
16. Singh R. Abnormal origin of posterior circumflex humeral artery and subscapular artery: a case report and review of literature. *J Vasc Bras.* 2017;16(3):248-251.
17. Daimi SR, Siddiqui AU, Wabale RN. Variations in the branching pattern of axillary artery with high origin of radial artery. *Int J Anat Var.* 2010;3:76-77.
18. Gadzhieva FG, Okolokulak ES. Chastota variatsii podmyshechnoi arterii cheloveka [Frequency of the human axillary artery variations]. In: [Spring anatomical readings: proceedings of the scientific-practical conference dedicated to the memory of professor M. Kolesov; 2016 May 27; Grodno]. Grodno; 2016. p. 37-43. Russian.
19. Kovanov VV, Anikina TI. *Khirurgicheskaiia anatomiiia arterii cheloveka* [Surgical anatomy of human arteries]. Moscow: Meditsina; 1974. 360 p. Russian.
20. Yang HJ, Gil YC, Jung WS, Lee HY. Variation of the superficial brachial artery in Korean cadavers. *J Korean Med Sci.* 2008;23(5):884-887.
21. Vatsala AR, et al. A morphological study of axillary artery and its branching pattern. *Int J Anat Res.* 2014;2(1):266-269.