

REVIEW ARTICLES

The management of sarcoidosis

*D. Calaras, V. Botnaru, O. Munteanu

Department of Internal Medicine, Medical Clinic No 2 of Pneumology/Allergy
Nicolae Testemitsanu State University of Medicine and Pharmacy
1, Malina Mica Street, Chisinau, Republic of Moldova

*Corresponding author: bumdin@yahoo.com. Manuscript received January 10, 2013, revised February 11, 2013

Abstract

Sarcoidosis is a systemic granulomatous disease of unknown etiology that can affect virtually any organ, though there is clear predilection for the lungs and hilar lymph nodes. Unfortunately, there is a great uncertainty in establishing the diagnosis of this disease due to lack of knowledge of the true cause of this condition, the absence of a pathognomonic test, and the close similarity with other granulomatous diseases. In the past decades several imaging techniques and laboratory tests have emerged, all meant to ensure not only an accurate diagnosis, but also to assess the activity, severity and extent of the disease. The treatment of sarcoidosis is also a subject of debate because of the disease's ability to spontaneously resolve or to remain stable. In these conditions treatment is not always necessary. This is why sarcoidosis is a great challenge in terms of diagnostic and management, even for expert physicians. The following report reviews the diagnostic aspects and approach to the treatment of sarcoidosis.

Key words: sarcoidosis, diagnosis, treatment, corticosteroids.

Ведение пациентов с саркоидозом

Саркоидоз является системным гранулематозным заболеванием неизвестной этиологии, с возможностью поражения любых органов, в то же время преимущественно вовлекая легкие и корневые лимфатические узлы. Незнание этиологии, отсутствие высоко специфических тестов и значительное сходство с другими гранулематозными заболеваниями, существенно затрудняют установление диагноза. В последние десятилетия были внедрены новые радиологические и лабораторные методы исследования, призванные обеспечить не только точный диагноз, но и оценить активность, тяжесть и степень заболевания. Благодаря возможности болезни самоизлечиваться или иметь стабильное течение, лечение саркоидоза остается неоднозначной проблемой. Таким образом, диагностирование и лечение больных саркоидозом продолжает представлять трудности даже для опытных специалистов. В представленной статье проанализированы данные литературы касательно диагностики и лечения саркоидоза.

Ключевые слова: саркоидоз, диагностика, лечение, кортикостероиды.

Introduction

Sarcoidosis is a multi-systemic disorder whose cause is unknown. It commonly affects young and middle-aged adults, and is morphologically characterized by noncaseating epithelioid cell granulomas [1]. It often presents itself with bilateral hilar lymphadenopathy, pulmonary infiltration, and ocular and skin lesions.

Diagnosing sarcoidosis can be very challenging even for expert physicians, largely because of the lack of a diagnostic test for this disease, but also because of the multifaceted nature of the disease, that often leads to a lack recognition and misdiagnosis of the condition.

This report reviews sarcoidosis's clinical features, aspects of diagnosis, and treatment.

Diagnosis

An accurate diagnosis can be established when the following criteria are fulfilled: compatible clinico-radiological features supported by histological evidence of noncaseating epithelioid granulomas, and the exclusion of the known causes of granulomatous inflammation other than sarcoidosis [1]. Due to the large spectrum of other granulomatous diseases and the lack of a pathognomonic test, sarcoidosis is always a

diagnosis of exclusion. This is why these patients should be evaluated systemically, not only for establishing the diagnosis, but also for detecting other organs' involvement. Moreover, the evaluation should provide information about whether the disease is stable or presents signs of progression, and if the patient will benefit from the indicated treatment [1].

The recommended approach to all patients suspected of sarcoidosis is to conduct a number of screening tests (tab. 1) in order to assess the extent and the severity of the disease.

Table 1

Recommended initial evaluation of patients with sarcoidosis

1.	Comprehensive history (suggestive symptoms, family history, occupational/environmental exposure)
2.	Physical examination – looking for various organ involvement: lungs, eyes, skin, peripheral lymph nodes, heart, liver and spleen, neurological, etc
3.	Chest X-ray (postero-anterior and lateral view), if necessary pulmonary HRCT
4.	Pulmonary function tests: spirometry, lung volumes, DLCO

5.	Lab tests: CBC, blood calcium, liver enzymes (ALT, AST, alkaline phosphatase), blood urea, creatinine, ACE, ESR, urine analysis, 24 hours calcium excretion
6.	ECG (if any abnormality – investigate further with Holter ECG, EchoCG, cardiac MRI)
7.	Ophthalmologic examination (slit lamp and fundoscopic eye examination)
8.	Tuberculin test or IGRA, microscopy of the sputum for acid fast bacilli
9.	Fiberoptic bronchoscopy with mucosal, transbronchial biopsy, BAL for CD4/CD8 ratio
10.	Biopsy of extrapulmonary sites

HRCT – high resolution computerized tomography, DLCO – diffusion capacity for carbon monoxide, CBC – complete blood count, ALT – alanine aminotransferase, AST – aspartate aminotransferase, ACE – angiotensin converting enzyme, ESR – erythrocyte sedimentation rate, ECG – electrocardiogram, MRI – magnetic resonance imaging, BAL – bronchoalveolar lavage.

Modified from Costabel U., Hunnighake G.W., Ando M., Baughman R., Cordier J.F., du Bois R., *et al.*, *ATS/ERS/ WASOG Statement on sarcoidosis*. *Sarcoidosis Vasc Diffuse Lung Dis*, 1999. 16: p. 149-173.

Clinical presentation

Due to its multi-systemic nature, sarcoidosis has a wide variety of clinical symptoms. Several studies have reported that 30-50% of patients are asymptomatic at presentation [2]. This explains why the disease comes into attention when abnormalities are detected on a chest X-ray during a routine screening examination. Among patients who present symptoms, 20-30% have non-specific symptoms such as: fatigue, low grade fever, night sweats, weight loss and arthralgias [3]. While other patients present organ related symptoms: clinical signs of cardiac involvement occurs in less than 5%, symptomatic neurosarcoidosis < 10%, skin disease – 25-33% (fig. 1), ocular lesions in 10-90% of the cases, pulmonary symptoms (dry cough, dyspnea, chest discomfort) – 33-50% [1].

Natural course

The course and prognosis of sarcoidosis depend on the mode of onset and the spectrum of organ involvement. A recent debut and early course of the condition is defined as acute sarcoidosis [4]. However, the disease that persists longer than 2 years is defined as chronic sarcoidosis [5], which is characterized by its insidious onset, involvement of extrapul-

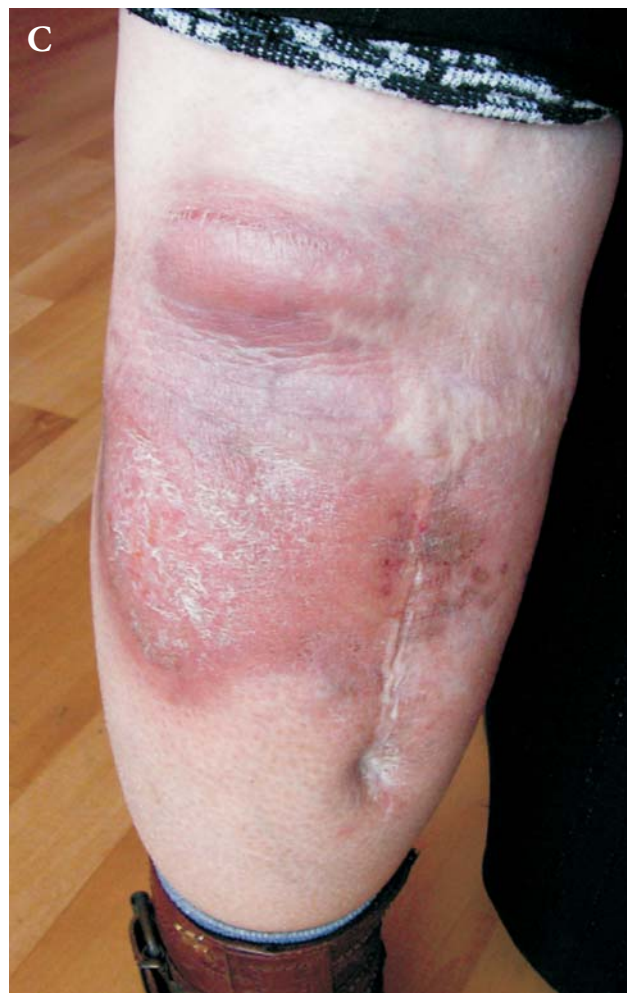
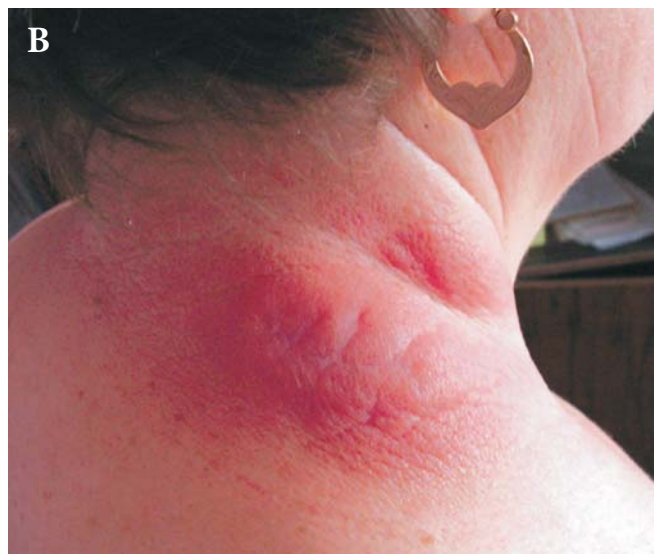
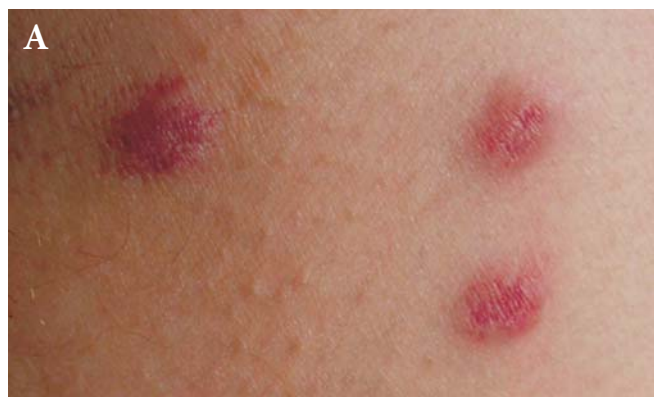Fig. 1. Cutaneous involvement in sarcoidosis. Here is presented a wide variety of skin lesions caused by sarcoidosis: from simple isolated papules (A), to infiltrated extensive disfiguring plaques (B, C).

monary organs, and persistent or progressive pulmonary disease, which usually requires therapy [6].

However, there are standard clinical characteristics that have been found to play a consistent role in the prognosis of the disease. A good prognosis, is expected in presence of fever, erythema nodosum, and arthritis (Löfgren's syndrome) [7]. On the other hand, age > 40 years, african ethnicity, the presence of *lupus pernio*, chronic uveitis, splenomegaly, bone lesions, neurosarcoidosis and myocardial involvement are all suggestive of poor prognosis [1].

Most patients with sarcoidosis have remission within 3 years after diagnosis, which occurs either spontaneously or under treatment, with few or no consequences [8]. About one third of patients will have a stable chronic course, and a minority of them will show inexorable progression of the disease, leading to clinically significant organ impairment. Less than 5% of patients die from sarcoidosis due respiratory failure, cardiac or neurologic involvement [1].

Imaging

Chest X ray is the most widely used diagnostic tool. The chest radiograph is abnormal in more than 90% of sarcoidosis patients. In 50-85% of the cases symmetric hilar adenopathy is noted. Bilateral pulmonary infiltrates are seen in 25-60%, with a predilection for the upper lobes [9].

Several decades ago, a radiologic staging system for sarcoidosis has been proposed. It included 5 stages: stage 0 – no pulmonary lesions (in patients with extrathoracic involve-

ment), stage I – bilateral hilar adenopathy, stage II – bilateral hilar adenopathy and pulmonary infiltrates, stage III – pulmonary infiltrates, no adenopathy, and stage IV – pulmonary fibrosis. Radiological stages correlate with the severity of pulmonary dysfunction, and mortality rate [9]. These stages seem to have a predictive role in spontaneous remission rates. It was found that in stage I, spontaneous remission occurs in 60-90% of cases, in stage II 40-70%, in stage III – in 20% of patients, and stage IV, due to fibrosis, no remission [6]. This is very important information when considering the decision to initiate treatment.

HRCT is a more accurate and reliable imagistic method, it often reveals more disease that it can be interpreted on a chest X-ray. Commonly, the imagistic pattern that defines pulmonary sarcoidosis is represented by nodules distributed in a perilymphatic manner [10] (fig. 2).

The pattern of distribution, upper lung predominance and coexistence of mediastinal lymphadenopathy strongly indicate the presence of sarcoidosis, helping distinguishing it from other nodular lesions such as eosinophilic granuloma, miliary tuberculosis, or metastasis [11].

Typical HRCT lesions include: peribronchovascular thickening, perilymphatic nodules, upper and mid-zone predominance, symmetric hilar lymph node enlargement, fibrotic changes with traction bronchiectasis, and parenchymal distortion [12] (fig. 3: A, B). Although typical radiological lesions can easily be recognized, sarcoidosis can mimic a large variety of other lung diseases. Knowing its atypical features is

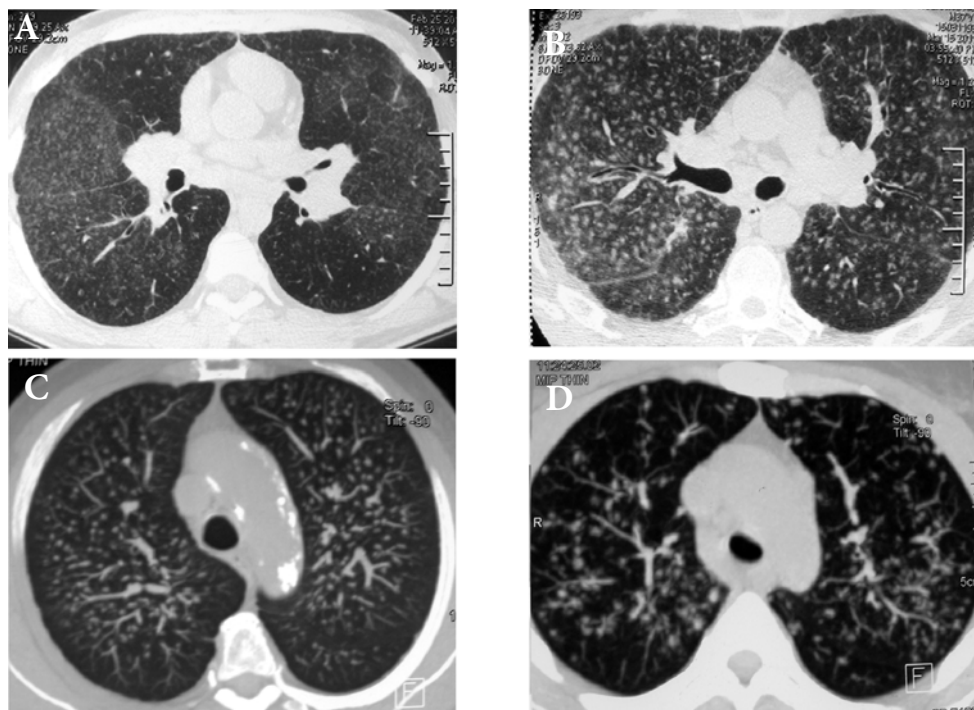


Fig. 2. HRCT appearance of pulmonary sarcoidosis. Nodules are the hallmark of sarcoidosis. They are typically distributed in a perilymphatic manner. HRCT can show a large variety of these nodules: from very fine, poorly defined nodules (A, B), accompanied by diffuse ground glass attenuation (A, B), to septal reticulation (arrows, B) and bilateral hilar adenopathy (A, B), to larger nodules with ill defined margins (C, D).

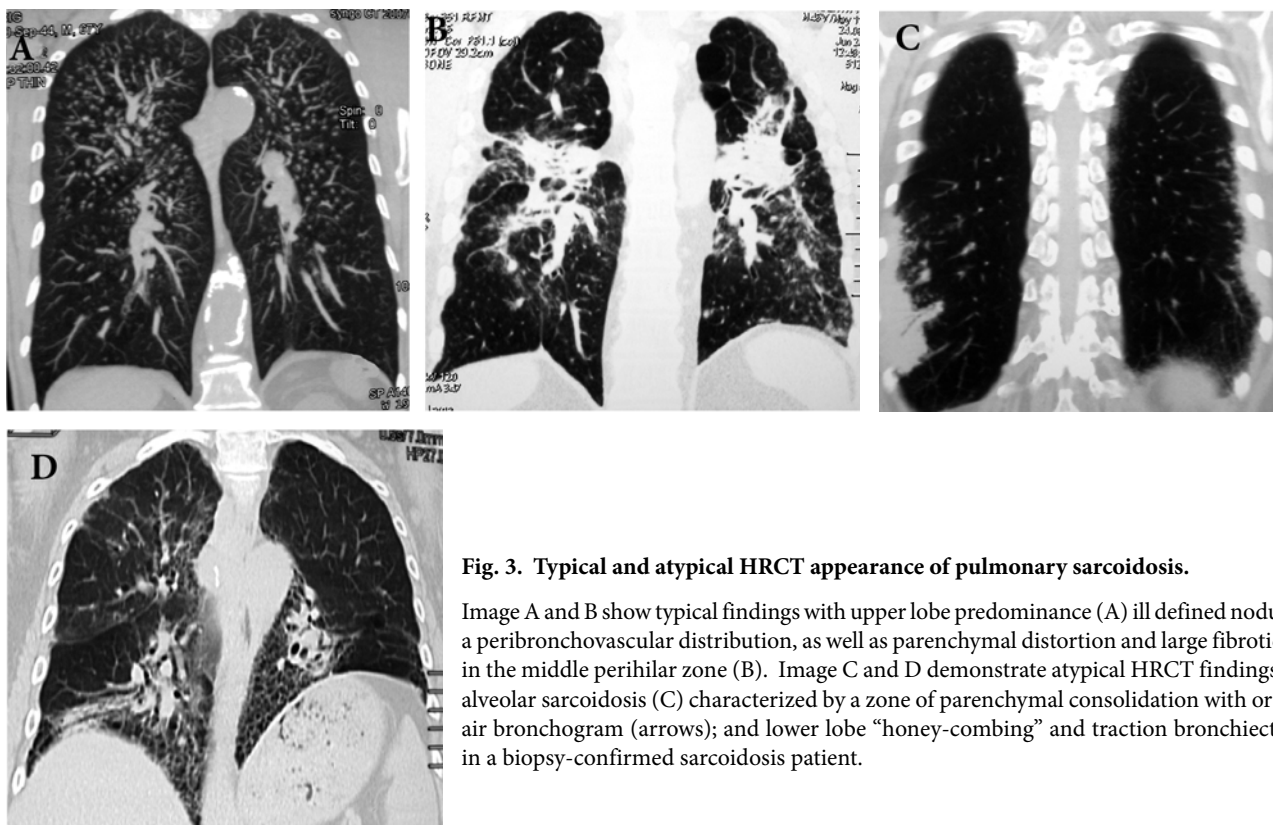


Fig. 3. Typical and atypical HRCT appearance of pulmonary sarcoidosis.

Image A and B show typical findings with upper lobe predominance (A) ill defined nodules with a peribronchovascular distribution, as well as parenchymal distortion and large fibrotic lesions in the middle perihilar zone (B). Image C and D demonstrate atypical HRCT findings such as alveolar sarcoidosis (C) characterized by a zone of parenchymal consolidation with or without air bronchogram (arrows); and lower lobe “honey-combing” and traction bronchiectasis (D) in a biopsy-confirmed sarcoidosis patient.

important for identifying sarcoidosis. Uncommon HRCT features include: pleural involvement, cavitation, patchy ground glass opacities, alveolar sarcoidosis, millitary pattern, unilateral disease, and aspergilloma [12] (fig. 3: C, D).

Although HRCT is superior to the chest X-ray in detecting pulmonary sarcoidotic lesions, there is insufficient evidence that CT has a clinical role in the management of pulmonary sarcoidosis [1].

MRI with gadolinium enhancement is another imaging technique particularly useful in detecting cardiac and neurological involvement [13].

Pulmonary function tests (PFT)

Often in sarcoidosis pulmonary function tests are within the lower limit of the normal range. *Winterbauer and colleagues* found a correlation between the radiological stage and abnormal PFT. Thus, in patients with no evidence of radiologic parenchymal lesions, the vital capacity, DLCO, and lung compliance are abnormal in 20-40% of cases. In contrast, in those with parenchymal radiological lesions, PFTs are abnormal in 50-70% of cases. The most severe pulmonary function impairment is registered in patients with stage IV sarcoidosis [14].

Although commonly thought of as a restrictive lung disease, airway obstruction has become a recognized feature of sarcoidosis in the past years. This phenomenon is explained by the involvement of the granulomatous endobronchial, or airway distortion from parenchymal disease, stenosis, or airway reactivity [15]. Depending on the case definition, airway obstruction from sarcoidosis has been reported in a broad range from 4 to 63% of cases [16]. *Viskum et al.* reported that

sarcoidosis patients with FEV1/FVC < 70% had increased mortality compared to those with FEV1/FVC ≥ 70% [17].

Bronchoalveolar lavage (BAL)

At the time of diagnosis, 90% of sarcoidosis patients show an increased number of lymphocytes found in the BAL fluid [18]. Most researchers agree that the BAL CD4/CD8 ratio > 3.5 shows high specificity for a sarcoidosis diagnosis (93-96%), although the sensitivity is low, 53-59% [19]. No parameter from the BAL cells profile is significant alone for the differentiation of other interstitial lung diseases, but a combination of them. Thus, if the BAL fluid analysis shows a normal or slightly elevated total cell count, with elevated number of lymphocytes, abnormal percentage of eosinophils and neutrophils, and no “foamy” alveolar macrophages or plasma cells – the most likely diagnosis is sarcoidosis [1].

Morphologic confirmation

Traditionally, a biopsy is needed for the definitive diagnosis of sarcoidosis [1]. However, certain clinical presentations are so specific for sarcoidosis, that the diagnosis can be accepted without a biopsy. Examples of these include Löfgren’s syndrome (fever, erythema nodosum, arthralgias, and bilateral hilar adenopathy), and Heerfordt’s syndrome (fever, parotid gland enlargement, facial palsy, and anterior uveitis) [1].

In all other cases, a biopsy specimen should be obtained from the involved organ that is most easily accessed, such as enlarged peripheral lymph nodes, skin, etc. Also, it is wise to select the least invasive method to confirm the suspected diagnosis.

Hilar lymph nodes and the lungs are the most frequent

affected organs in sarcoidosis [4]. This is why bronchoscopy and the biopsy techniques applied during this procedure are of great help in confirming the diagnosis. The endobronchial biopsy has a sensitivity of 40-60%. Supplemented by the transbronchial lung biopsy, the diagnostic yield is increased to 90%. Moreover, the addition of endobronchial ultrasound guidance increases the accuracy and success rate in the biopsy of mediastinal lymph nodes [9]. Of course, if none of these procedures are revealing, mediastinoscopy and surgical lung biopsy may be suggested.

Difficulties in establishing the diagnosis may arise if patients refuse biopsy, or if lung biopsy is considered to be a high risk. In these cases, clinical and radiological findings should be considered [1]. Researchers found that the reliability of these criteria is inversely correlated with the radiological stage. Thus, compatible clinical and radiological findings have a high accuracy in radiological stage I (98%), good diagnostic reliability in stage II (89%), and less reliable in stage III (52%) or stage 0 (23%) of sarcoidosis. Therefore, histological confirmation may not be needed in asymptomatic patients with symmetric hilar adenopathy. However, when hilar adenopathy is asymmetric, massive, or associated with large paratracheal enlargement, morphologic confirmation is strongly recommended [4].

Assessing disease activity and extent

Nowadays, there are several available techniques used for the evaluation of activity and stage of sarcoidosis. Nevertheless, clinical indices remain the cornerstone in evaluating disease activity and severity [1]. Thus, the presence of systemic symptoms such as uveitis, hypercalcemia, active skin lesions, enlarged parotid and salivary glands, enlarged liver and spleen, myocardial disease, neurosarcoidosis, and progressive respiratory symptoms, are indicative of activity of the disease [7].

A long list of biochemical studies have been proposed for activity evaluation. In practice, only a few of them have been assessed systematically. The most widely used biochemical marker is the serum angiotensin converting enzyme (ACE), which is produced by activated epithelioid cells and macrophages at sites of inflammation. This is why serum ACE level is thought to reflect the total body granuloma burden in sarcoidosis. However several studies suggest that its activity assessment's usefulness is questionable [20]. These researches showed no correlation of ACE levels with the disease activity in the lungs (intensity of lymphocytic alveolitis). Nevertheless, measuring ACE levels seems to be useful in monitoring the treatment effect, since increased serum ACE activity will reduce in a short time after the start of corticosteroid treatment [4].

More than 20 years ago it was stipulated that the quantification of BAL lymphocytes provide a sensitive and specific means of assessing the activity of the disease in the lungs, however it has little clinical application in patient care. Gallium scans have been valuable in detecting active granulomas, and fluorodeoxyglucose positron emission tomography (FDG PET) has proven to be even more accurate [21]. These two

techniques are useful tools not only in assessing activity, but, due to their high sensitivity in detecting the loci of inflammation, have also shown beneficial in looking at the extent of the disease. Of course, in terms of deciding whether to initiate treatment or not, assessing the extent and the severity of the disease becomes more important. However, in patients with radiological stage IV, with CT signs of pulmonary fibrosis, identifying the presence of residual active reversible lesions in a background of fibrosis provides valuable information that could serve as a guide for treatment [1].

Nevertheless, with the advanced imaging technology that is commonly nowadays available, in routine clinical practice, disease activity is assessed based on clinical findings: the mode of onset of the disease, the worsening or persistence of symptoms, the presence of skin lesions, progressive changes on chest radiographs, and pulmonary function tests [1].

Differential diagnosis

In most diseases, there is a morphological pattern that defines the condition, making a histological examination play the role of the ultimate investigation. Unfortunately, sarcoidosis is an exception. Sarcoidotic granulomas have no unique histological features to differentiate them from other granulomas, such as those from: tuberculosis, atypical mycobacteriosis, mycoplasma infections, fungal granuloma (aspergillosis, histoplasmosis, cryptococcosis, coccidioidomycosis, blastomycosis), drug reactions, aspiration of foreign material, hypersensitivity pneumonitis, pneumoconiosis (beryllium, aluminium, titanium), lymphocytic interstitial pneumonia, necrotizing sarcoid granulomatosis (NSG), pneumocystis carinii, Wegener's granulomatosis, lymphoma (especially in the lymph nodes), toxoplasmosis, etc. [1].

Exclusion of other causes of granulomatous inflammation requires special stains for acid-fast bacilli and fungi, as well as cultures for these organisms. The presence of necrotic lesions in the biopsy specimen requires further investigations for mycobacteria, fungi, other potential pathogens, and vasculitis [1].

Despite the imposing list of other granulomatous diseases, a chest X-ray demonstrating a bilateral hilaradenopathy will considerably reduce the list of differential diagnosis to sarcoidosis, lymphoma, tuberculosis, and fungal infections. Statistic data from a study conducted in USA revealed that 99,95% of patients with bilateral hilar adenopathy who underwent mediastinoscopy were diagnosed with sarcoidosis, 8 persons out of 33,000 with tuberculosis, 9 – with Hodgkin's lymphoma, and one with non-Hodgkin's disease [22]. Certainly, local investigations and adjustments upon the incidence of these diseases are needed, especially in tuberculosis high burden countries.

Treatment

Indications for treatment

Because the majority of patients with sarcoidosis will undergo spontaneous remission, indications for treatment remain a controversial subject. Moreover, due to considerable side effects of corticosteroids and higher relapse rates,

the initiation of systemic treatment should be done after a careful evaluation of compatible criteria.

There is a general rule that patients with potential dangerous diseases must be treated [1]. Although the indications for initiating treatment in cases of life threatening organ damage are more or less clear, there is much confusion about when to start treatment in pulmonary involvement. Due to high rates of spontaneous remission in earlier radiological stages, there is a common opinion not to treat asymptomatic patients with no or mild functional disturbances [1]. Instead, they should be followed-up at 6 months intervals for stage I, and every 3 months for the other stages [1, 4]. During the follow up period, patients who are worsening will be initiated for treatment immediately [1]. This way, patients who improved without treatment will be spared of corticosteroid's toxicity. Finally, there is no unanimous recommendation about patients who neither improve nor worsen during a period of 6 months of follow up. Some experts suggest they should be given a corticosteroid trial, or simply be monitored further [23].

Patients with excellent prognosis (Löfgren's syndrome) will be also closely observed, and will benefit, if necessary, from palliative treatment (NSAIDs for fever and arthralgias, bronchodilators and inhaled corticosteroids for cough and wheezing), or, in severe cases, short term systemic corticosteroids [23].

Regarding patients with symptomatic pulmonary disease with signs of clinical and radiological progression, most clinicians feel that they will require therapy [1], as well as do those who present severe pulmonary symptoms and pulmonary dysfunction [24]. Other candidates for systemic treatment are: asymptomatic patients with moderate to severe alterations of pulmonary function, most patients in stage III of sarcoidosis, and patients with stage IV with irreversible fibrosis and signs of co-existence of active alveolitis [1].

Inactive stage IV patients have shown to respond poorly to systemic corticosteroids, but the symptoms they commonly complain could be due to complications such as: bronchiectasis, haemoptysis, and aspergiloma, which are generally treated with antibiotics and antifungal agents [25]. Patients in stage IV with extensive fibrosis are candidates for lung transplantation [1].

In some cases, the pulmonary involvement is not severe enough to motivate the need for the initiation of treatment, but concomitant extrapulmonary disease can make it indicated. The decision to treat extrapulmonary sarcoidosis will be based on the organ involved and its degree of impairment, assessed by clinical and laboratory examinations [26]. Thus, cardiac involvement, neurosarcoidosis, eye lesions that are not responsive to local treatment, persistent renal impairment, hypercalcemia unresponsive to dietary measures, liver dysfunction with cholestatic symptoms, impaired synthetic function, or portal hypertension; splenomegaly with hypersplenism [26], diffuse or disfiguring skin lesions not responsive to topic treatment, chronic myopathy, weight loss, or severe fatigue [1, 4] will benefit from systemic corticosteroids.

Medication

Corticosteroids

Corticosteroids are the first-choice drugs in the treatment of sarcoidosis [24]. In mild cases, improvement can be reached by using only topic corticosteroids [1]. These include corticosteroid creams (e.g.: for isolated mild skin lesions), intralesional injections (for skin lesions, localized upper respiratory tract lesions), drops (in case of anterior uveitis), and sprays (for cough and wheezing) [26]. Systemic treatment is preferred to topical in treating refractory lesions and in the cases that were elucidated earlier in the *Indications for treatment* chapter.

Several studies performed in the past decades have reported that systemic corticosteroids improve symptoms, chest X-ray findings, and functional tests [27-29], although the fact that they are associated with a higher relapse rate within 2 years after treatment cessation [28, 30-32].

While the optimal doze and duration of treatment has not been standardized through randomized trials, treatment of pulmonary sarcoidosis is commonly initiated with a 0.5 mg/kg/day (20-40mg) prednisone or equivalent [33] for a period of 1-3 months. Cases of neurosarcoidosis and myocardial might need higher doses (1 mg/kg/day) [34, 35].

In cases of positive response after a reevaluation, the dose of corticosteroids should be slowly tapered to a daily maintenance dose of 5-10 mg, and continue treatment for at least 1 year [1]. Patients who failed to respond after a period of 3-6 months of treatment, tend to present a chronic evolution. These patients may need lifelong treatment of corticosteroid, administrated at the lowest effective dose [1].

Alternative treatment

Patients who require long term administration of corticosteroids, should benefit the treatment with corticosteroid sparing agents [1]. Usually they demonstrate a lower efficacy, and necessitate a longer period of administration to reach their maximum potency. More commonly, these drugs are used in combination with a low dose of corticosteroids [23].

Among cytotoxic agents, the most widely used are methotrexate and azathioprine. There are several studies where these drugs were used for chronic sarcoidosis, either alone or in combination with prednisone. They seem to be safe and efficient, although treatment with either azathioprine or methotrexate is associated with high relapse rates after discontinuation [36].

Antymalarial agents such as chloroquine and hidroxychloroquine have proved efficacy in disfiguring skin lesions (lupus pernio), in hypercalcemia and neurosarcoidosis [37]. Because of increased risk of retinopathy, chlorochine has a limited use, in contrast to hydroxychlorochine, which has not demonstrated such serious side-effects [38]. Moreover, hydroxychlorochine is preferred as treatment for diabetic patients with mild to moderate sarcoidosis, due to its positive effects in carbohydrate metabolism [39].

Recently, Infliximab, Thalidomide and Pentoxifylline have demonstrated some efficacy in various forms of treatment for sarcoidosis [4].

Follow up

As it was previously stated, patients with stage I sarcoidosis should be evaluated every 6 months, and every 2-3 months for all other stages [1]. Patients require evaluation for alterations in the physiologic function of the involved organs, in comparison with the initial investigation, [1]. New symptoms demand further investigations [1]. And of course, due to the toxicity of the drugs used for treatment, tests should be performed to assess any possible side effects.

After discontinuation of therapy, it is suggested that patients be monitored for a period of 3 years [1].

References

- Hunnighake GW, Costabel U, Ando M, et al. ATS/ERS/ WASOG Statement on sarcoidosis. *Sarcoidosis Vasc Diffuse Lung Dis.* 1999;16:149-173.
- Baughman RPTAS, Judson MA. Clinical characteristics of patients in a case control study of sarcoidosis. *Am J Respir Crit Care Med.* 2001;164:1885-1889.
- Drent MWRM, de Vries J. Association of fatigue with an acute phase response in sarcoidosis. *Eur Resp J.* 1999;13:718-722.
- Costabel U. Sarcoidosis: clinical update. *Eur Respir. J.* 2001;18(Suppl 32):56s-68s.
- Neville E, Walker AN, James DG. Prognostic factors predicting the outcome of sarcoidosis: an analysis of 818 patients. *Q J Med.* 1983;208:525-533.
- Judson MABRP, Thompson BW. Two year prognosis of sarcoidosis: the ACCESS experience. *Sarcoidosis Vasc Diffuse Lung Dis.* 2003;20:204-211.
- Mana J, Gomez-Vaquero C, Montero A, et al. Löfgren's syndrome revisited: a study of 186 patients. *Am J Med.* 1999;107:240-245.
- Teirstein AMA. "End-Stage" Pulmonary Fibrosis in Sarcoidosis. *Mount Sinai Journal of Medicine.* 2009;76:30-36.
- Lynch JP, Gay SE. Pulmonary sarcoidosis. *Clin Chest Med.* 1997;18:755-785.
- Dawson WBMNL. High-resolution computed tomography in pulmonary sarcoidosis. *Semin Ultrasound CT MR.* 1990;11:423-429.
- Takashi KHU, Kaori T, Shigeaki U, et al. Radiological Manifestations of sarcoidosis in various organs. *RadioGraphics.* 2004;24:87-104.
- Vagal ASSR, Meyer CA. Radiological manifestations of sarcoidosis. *Clinics in Dermatology.* 2007;25:312-325.
- Mana J. Magnetic resonance imaging and nuclear imaging in sarcoidosis. *Curr Opin Pulm Med.* 2002;8:457-463.
- Winterbauer RHHJF. Use of pulmonary function tests in the management of sarcoidosis. *Chest.* 1980;78:640-647.
- Shorr AFTKG, Hnatiuk OW. Endobronchial involvement and airway hyperreactivity in patients with sarcoidosis. *Chest.* 2001;120:881-886.
- Sharma OPJR. Airway obstruction in sarcoidosis. A study of 123 nonsmoking black American patients with sarcoidosis. *Chest.* 1988;94(2):343-346.
- Viskum KVJ. Vital prognosis in intrathoracic sarcoidosis with special reference to pulmonary function and radiological stage. *Eur Respir J.* 1993;6:349-353.
- Yeager H Jr WM, Beekman JF. Pulmonary and psychosocial findings at enrollment in the ACCESS study. *Sarcoidosis Vasc Diffuse Lung Dis.* 2005;22:147-153.
- Korosec PRM, Silar M, Kern I, et al. Deficiency of pulmonary Valpha24 Vbeta11 natural killer T cells in corticosteroid-naive sarcoidosis patients. *Respir Med.* 2010;104:571-577.
- Ziegenhagen MWRME, Schlaak M, Muller-Quernheim J. Bronchoalveolar and serological parameters reflecting the severity of sarcoidosis. *Eur Respir J.* 2003;21:407-413.
- Teirstein ASMJ, Almeida O. Results of 188 whole-body fluorodeoxyglucose positron emission tomography scans in 137 patients with sarcoidosis. *Chest.* 2007;132:1949-1953.
- Reich JMBMC, O'Connor EA, Edwards MJ. Mediastinoscopy in patients with presumptive stage I sarcoidosis. *Chest.* 1998;113:147-153.
- Judson MA. Sarcoidosis: clinical presentation, diagnosis and approach to treatment. *Am J Med Sci.* 2008;335:26-33.
- Judson MA. An approach to the treatment of pulmonary sarcoidosis with corticosteroids: the six phases of treatment. *Chest.* 1999;115:1158-1165.
- Sharma OP. Pulmonary sarcoidosis: management. *J Postgrad Med.* 2002;48(2):135-141.
- Judson MA. Extrapulmonary sarcoidosis. *Semin Respir Crit Care Med.* 2007;28(1):83-100.
- Sharma OP, Colp C, Williams MH Jr. Course of pulmonary sarcoidosis with and without corticosteroid therapy as determined by pulmonary function studies. *Am. J. Med.* 1966;41:541-551.
- Johns CJ, Zachary JB, Ball WC, Jr. A ten-year study of corticosteroid treatment of pulmonary sarcoidosis. *Johns Hopkins Med J.* 1974;134:271-283.
- Gibson GJ, Prescott RJ, Muers MF, et al. British Thoracic Society Sarcoidosis study: effects of long-term corticosteroid treatment. *Thorax.* 1996;51:238-247.
- Rizzato G, Montemurro L, Colombo P. The late follow-up of chronic sarcoid patients previously treated with corticosteroids. *Sarcoidosis.* 1998;15:52-58.
- Hunninghake GW, Gilbert S, Pueringer R, et al. Outcome of the treatment for sarcoidosis. *Am J Respir. Crit. Care Med.* 1994;149:893-898.
- Gottlieb JE, Israel HL, Steiner RM, et al. Outcome in sarcoidosis. The relation of relapse to corticosteroid therapy. *Chest.* 1997;111:623-631.
- Baughman R, Lower E, Lynch J. Treatment modalities for sarcoidosis. *Clin. Pulm. Med.* 1994;1:223-231.
- Schulte W, Kirsten D, Drent M, et al. Cardiac involvement in sarcoidosis. *European Respiratory Journal Monograph.* 2005;32:130-149.
- Hoitsma E, Sharma OP. Neurosarcoidosis. *European Respiratory Journal Monograph.* 2005;10:164-187.
- Lower EE, Baughman RP. Prolonged use of methotrexate for sarcoidosis. *Arch Intern Med.* 1995;155:846-851.
- Sharma OP. Effectiveness of chloroquine and hydroxychloroquine in treating selected patients with sarcoidosis with neurological involvement. *Arch Neurol.* 1998;55:1248-1254.
- Zic JA, Horowitz DH, Arzubiga C, et al. Treatment of cutaneous sarcoidosis with chloroquine: review of the literature. *Arch Dermatol.* 1991;127:1034-1040.
- Quatraro A, Consoli G, Magno M, et al. Hydroxychloroquine in decompensated, treatment-refractory noninsulin-dependent diabetes mellitus: a new job for an old drug? *Ann Intern Med.* 1990;112:678-681.

