

## Reparative osteogenesis in normal conditions and micronutrient iodine deficiency

A. N. Slobodian, P. Ye. Kovalchuk, M. V. Gasko, \*S. V. Tulyulyuk

Department of Traumatology, Orthopaedics and Neurosurgery, Bukovinian State Medical University  
Chernivtsi, Ukraine

\*Corresponding author: tulyulyuk\_serhiy@ukr.net. Manuscript received April 17, 2015; accepted June 05, 2015

### Abstract

**Background:** Today without attention of researchers a number of issues remain unsolved and require their study, including: the impact of iodine deficiency conditions on bone health, healing of bone defects and morphological characteristics of the process concerning iodine deficiency.

**Material and methods:** The experiments were performed on 63 redbreast albino male rats, 3-month old. The experiment was performed on the control, and the main groups of animals. The main group consisted of 42 rats, subdivided into two subgroups, with 21 experimental animals each. Iodine deficiency was modeled in the animals of the main group by using the diet with low iodine content (6 mg / 100 g) and using the drug daily during 21 days, once a day in the stomach in the form of aqueous starch suspension. Reparative osteogenesis was studied by means of histomorphological examination on the 7, 15 and 30<sup>th</sup> days after producing femoral defect with the diameter of 1 mm.

**Results:** The data obtained are indicative of negative effects of iodine deficiency on reparative osteogenesis and saline, demonstrating the suppression of these processes, involving disorders of forming callus, deterioration of the structural-functional state of the bone development, degenerative and necrotic changes in bone and epiphyseal cartilage.

**Conclusions:** In animals of the experimental group with simulated iodine deficiency regenerative bone formation was delayed and developed against the ground of pronounced disorders of blood supply. The reparative process was characterized by inhibition of formation and remodeling of the regeneration, leading to decrease in a relative area of lamellar bone tissue as compared to the controls.

**Key words:** reparative osteogenesis, iodine deficiency.

### Introduction

Iodine influence upon the skeleton and bone regeneration is of an indirect character. Iodine plays a key role in functioning of the thyroid hormones and is contained in its main hormones – triiodothyronine ( $T_3$ ) and thyroxin ( $T_4$ ) which are the chief regulators for normal development and functioning of the skeleton. Multi-aspect examinations of schoolchildren from Greece, Iran, India, residing in the areas with iodine deficiency detected retardation of growth and maturation of the osseous tissue, which positively correlated with the level of thyroid-stimulating hormone and thyroid dysfunction [2, 3, 10].

Today numerous investigations have proved the impact of the thyroid hormones upon the development and metabolism of the skeletal tissues. Thyroid hormones are essential for normal growth and development. Thyroid hormones are found to stimulate proliferation and activity of osteoblasts in physiological concentrations, and biosynthesis of matrix macromolecules and their formation outside the cells in particular, promote proliferation and maturation of chondrocytes of the epiphyseal cartilage, and cause longitudinal growth of bones [4, 5, 6]. The link of the mechanism of thyroid hormones action is the presence of nuclear receptors in osteoblast-like cells and osteoblasts, stromal cells of the bone marrow, osteoclasts and chondrocytes of the epiphyseal cartilage [7].

An indirect action of the thyroid hormones is connected with their regulation of other hormones and hormone-like substances important for growth and metabolism of the bone, such as interleukin-6 (IL-6), interferon and  $T_3$  growth hormone in the blood serum [8, 9].

Today a number of issues remain unsolved and require

their study including the influence of iodine deficiency conditions upon the osseous tissue and healing of post-traumatic bone defects under conditions of selenium deficiency.

**Objective:** to study in the experiment peculiarities of reparative osteogenesis in case of post-traumatic defects of femoral bone meta-diaphysis under conditions of iodine deficiency.

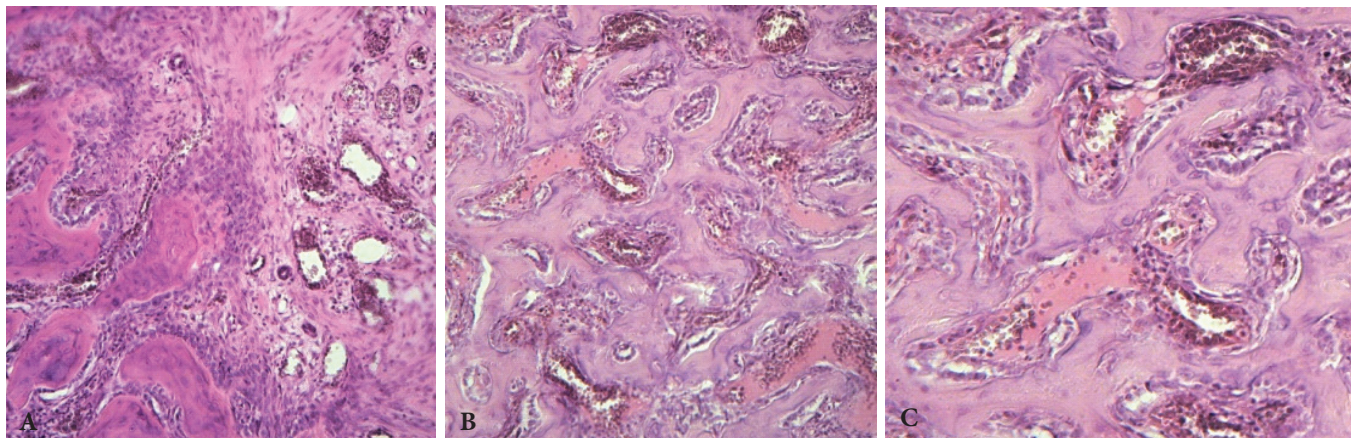
### Material and methods

The experimental part was performed on 63 redbreast albino male rats, 3-month old. Peculiarities of reparative osteogenesis were studied on the model of traumatic injury modeled as a single-type in the proximal meta-diaphysis of the femoral bone irrespective of the conditions of the experiment in the frontal plane in the shape of a perforated defect. The defect was received by means of a drill 1 mm in diameter. The animals were kept under conditions maximally corresponding to the requirements concerning their keeping and food ration. The experiment was conducted on the control and main groups of animals.

The control group included 21 animals. The course of reparative osteogenesis was studied on them without administration of medical or physical influence on osteogenesis.

The main group included 42 rats divided into two subgroups with 21 animals in each.

Iodine deficiency was modeled in the main group of animals by means of giving food ration with low iodine content (to 6 mg/100 g) and administering the drug Mercazolil which prevents secretion of the thyroid hormones in the parathyroid gland, but does not affect peripheral transformation of  $T_4$  and  $T_3$ , and is widely used in case of hyperfunction of the thyroid gland. The daily single dose of Mercazolil was introduced



**Fig. 1. Formation of osseous trabeculae of the rough fibrous osseous tissue.**

7 days after injury was made (a – control group, b – first subgroup, c – second subgroup). Hematoxylin-eosin staining. x10.

every day during 21 days into the stomach as a water-starch suspension.

21 days later a perforated defect was made on the portion of the proximal meta-diaphysis of the femoral bone of all the animals. After the injury was received, the first group of animals was still kept under conditions of iodine deficiency, and the second group of animals was helped out of iodine deficiency by means of giving food ration with high content of iodine in combination with the medicine Iodomarine in terms of 3.73 mkg per day.

The course of reparative osteogenesis under the influence of above-mentioned induced conditions of rats was examined by means of histomorphological method on the 7, 15 and 30<sup>th</sup> days after the defect was received.

Surgery on the femur was conducted in the vivarium operation room at Bukovinian State Medical University keeping to the rules of asepsis and antisepsis with aminazine-ketamine narcosis.

With the aim to prove the presence or absence of iodine deficiency condition in the examined animals iodine concentration in urine was measured by means of Iodtest kit No 50.

Histological specimens, stained with hematoxylin and eosin, were received by means of generally accepted methods. To measure the square of post-traumatic regeneration Avtandil's planimetric ruler was used [1].

During the experiment the animals were kept in the vivarium under appropriate climatic conditions with 12 hour regimen of lighting and standard food ration according to the principles of European convention for the protection of vertebrate animals used for experimental and other scientific purpose: Council of Europe (18.03.1986. – Strasburg. – 1986. – 52.), Law of Ukraine № 3447-IV dated 21.02.2006. "On protection of animals against brutal treatment" and bioethical norms.

The material was processed statistically with the use of the software support Statisticav. 5.5. The norm of distribution was checked by means of Shapiro-Whilcky. The hypothesis concerning a statistical similarity of two samples was checked

by means of Student criteria, correlation analysis – by means of Spirmen criterion.

## Results

7 days after receiving the defect an active cellular proliferation from the site of periosteum and endosteum with the formation of rough fibrous osseous tissue against the ground of slightly pronounced signs of hyperemia and edema in the control group of animals was observed, the defect was filled with newly formed osseous tissue in  $31.86 \pm 1.06\%$  (fig. 1a). The animals of the first and second subgroups demonstrated a network of osseous trabeculae of an irregular thickness, intratrabeular cells mostly filled with fibroreticular bone marrow, with diffused lumen of the capillaries filled with blood and pronounced plasmostasis and signs of edema (fig. 1 b, 1 c). The defect was filled in  $19.57 \pm 0.95\%$  and  $22.36 \pm 0.82\%$  respectively.

On the 15<sup>th</sup> day after a perforated defect was made in the control group of animals a slow formation of the periosteum osseous regeneration was detected microscopically. It was mainly limited by the traumatic area of the femoral diaphysis. Endosteum reparative process was characterized by the formation of the rough fibrous osseous tissue and its rebuilding, the defect was filled with newly formed osseous tissue in  $48.71 \pm 2.03\%$ . Intratrabeular cells in the first group of animals were mainly filled with fibroreticular bone marrow with a diffuse lumen of the capillaries filled with blood and pronounced signs of edema and plasmostasis, the compact osseous tissue of the margins of the femoral defects contained spread areas of necrosis, along their periphery the formation of the osseous tissue layer by the type of obturator trabecular was found. The defect was filled in  $23.57 \pm 0.95\%$ . The second subgroup demonstrated a gradual restoration of a reparative activity of the osseous tissue formation, which was accompanied by an increased activity of proliferation and osteoblast cellular elements,  $29.00 \pm 0.82\%$ .

On the 30<sup>th</sup> day in the control group of animals proliferative activity of the cells of the epiphyseal cartilage and the

process of endochondral ossification were indicative of rather high activity and physiological regeneration (formation) of the osseous tissue in the process of a longitudinal growth of the bone, the defect was filled with newly formed osseous tissue in  $95.42 \pm 2.03\%$ . In the first subgroup of animals certain peculiarities of the formation of osseous regeneration were observed, they were induced by insufficient selenium intake into the body. The changes found first of all concerned with proliferation and differentiation of cells into osteoblasts responsible for the formation of osseous tissue. The defect was filled in  $38.14 \pm 1.50\%$ . In the second subgroup regenerative processes were progressing and resulting in the formation of osseous tissue, in its apposition on the surface of osseous trabeculae intratrabecular cells were filled with proliferating osteogenic cells, the areas of not numerous osteoclasts were detected. They promoted dystrophic and necrotic resorption of the osseous tissue changed. The filling  $51.28 \pm 1.50\%$ .

Therefore, the data mentioned here are indicative of a negative influence of iodine deficiency upon reparative osteogenesis, which is revealed by inhibition of this process and accompanied by disorders of formation of the osseous regeneration, deterioration of the structural-functional condition of the osseous tissue, development of degenerative-necrotic changes in the osseous tissue and epiphyseal cartilage.

### Conclusions

1. Formation of the osseous regeneration was slow and occurred against the ground of pronounced disorders of blood supply in the experimental group of animals with modeled iodine deficiency.

2. Progressing of the reparative process in the first subgroup of animals with modeled iodine deficiency was characterized by inhibition of the formation and remodeling of regeneration, which is reflected in the decrease of a relative plane of the laminar osseous tissue as compared to the control.

### References

1. Avtandilov GG. Medical morphometry. Guidelines. 1990;384.
2. Brusko AT. Theoretical and biological aspects of healing bone fractures. Surgical treatment, medical rehabilitation, physiotherapy of bone fractures and diseases of joints: International scientific-practical conference with international participation, April 10-11. 2008;14-17.
3. Gayko GV, Brusko AT. Theoretical aspects of physiological and pathological regeneration of bones from the position of systemic views. *Journal of the Academy of Medical Science of Ukraine*. 2013;19(4):471-81.
4. Grygorovskiy VV, Magomedov SM. Metabolic reaction of the body and reparative regeneration of the bone in case of initiated injury. *Orthopaedic traumatology*. 2000;2:101-2.
5. Kostrub AA, Lytovchenko VA, Berezka MI, et al. Changes of hormonal state in case of complicated course of reparative osteosynthesis after numerous and combined fractures of long bones. *Problems of osteology*. 2000;3(4):35-6.
6. Laurberg P, Jorgensen T, Perrild H, et al. Danish investigation on iodine intake and thyroid disease Dan Thy: status and perspectives. *European Journal of Endocrinology*. 2006;155:219-28.
7. Ren FL, Guo RX. Effect of selenium and iodine deficiency on bone, cartilage growth plate and chondrocyte differentiation in two generations of rats. *Osteoarthritis Cartilage*. 2007;15:1171-77.
8. Visser TJ. The elemental importance of sufficient iodine intake. *Endocrinology*. 2006;147(5):4039-45.
9. Bassett K, Nordstrom K, Boyde A, et al. Thyroid status during skeletal development determines adult bone structure and mineralization. *Mol Endocrinology*. 2007;21(8):1893-904.
10. Volzke H. Association Between Serum Insulin-Like Growth Factor I Levels and Thyroid Disorders in a Population-Based Study. *J of Clinical Endocrinology & Metabolism*. 2007;92(10):4039-45.

