

CZU: 615.322:616.311.2-002

PHYTOTHERAPY | FITOTERAPIA  
IN TREATMENT OF GINGIVITIS | ÎN TRATAMENTUL GINGIVITEI

Nadezhda Krautsova-Kukhmar, Natallia Shakavets, Olga Mushkina, Tatyana Kidyasova

Belarusian State Medical University

**Rezumat.** Gingivita este cea mai frecventă boală a țesuturilor parodontale la copii. Medicamentele pe bază de plante sunt adesea folosite pentru a trata această patologie. Gelul cu conținut de tinctură de frunze de arin negru reprezintă unul dintre aceste medicamente. *Scopul lucrării* este de a evalua eficacitatea unui fitogel în tratamentul gingivitei experimentale. *Materiale și metode.* 42 animale au fost selectate pentru a simula gingivita experimentală. Au fost împărțite aleatoriu în 6 grupuri după apariția semnelor clinice de inflamație. Gelul cu conținut de tinctură de frunze de arin negru și gelul ce conține metronidazol au fost utilizate pentru tratament în decurs de 2 și 4 zile. Toți șobolanii au fost biopsiați pentru examinare histologică în a 8-a și a 10-a zi de la începutul experimentului. *Rezultate.* Semnele clinice ale inflamației au dispărut în ambele grupuri în a 2-a zi. Semnele histologice ale inflamației din grupul cu gel ce conține metronidazol au persistat în a 4-a zi. Regenerarea structurii gingiei din grupul cu gel care conține tinctură de frunze de arin negru a fost determinată în a 4-a zi după aplicare. *Concluzii.* Gelul cu conținut de tinctură de frunze de arin negru este un medicament eficient în tratamentul gingivitei experimentale.

**Cuvinte cheie:** gingivită experimentală, gel cu conținut de tinctură de frunze de arin negru, gel cu conținut de metronidazol.

**Abstract.** Gingivitis is the most common disease of periodontal tissues in children. Herbal drugs are often used to treat this pathology. One of them is a gel containing tincture of black alder leaves. *The aim of the work* is to evaluate the effectiveness of a phytogel in the treatment of experimental gingivitis. *Materials and methods.* 42 animals were selected to simulate experimental gingivitis. They were randomly divided into 6 groups after the onset of clinical signs of inflammation. A gel containing tincture of black alder leaves and a gel containing metronidazole were used for treatment during 2 and 4 days. All rats were biopsied for histological examination on the 8th and 10th day from the beginning of the experiment. *Results.* The clinical signs of inflammation disappeared in both groups on the 2th day. The histological signs of inflammation in the group with gel containing metronidazole persisted on the 4th day. The regeneration of the gum structure in the group with gel containing tincture of black alder leaves was determined on the 4th day after application. *Conclusions.* Gel containing tincture of black alder leaves is an effective drug in the treatment of experimental gingivitis.

**Keywords:** experimental gingivitis, gel containing tincture of black alder leaves, gel containing metronidazole.

## INTRODUCTION

Gingivitis is the most common pathology among inflammatory diseases of the marginal periodontium tissues. Periodontal diseases are a set of common oral infections caused by a variety of bacterial colonizers inside and around the gingival tissues. Gingivitis is an early inflammatory response that is initiated by the bacterial toxins in dental plaque. It occurs by redness and edema in the gingival tissue without periodontal attachment loss. The pathogenesis of gingivitis is a complex of microcirculatory and connective tissue reactions to damage to cells and blood vessels by toxins produced by microorganisms of dental plaque. Usually treatment of gingivitis consists of professional oral hygiene and the usage of medications. A gel containing metronidazole and chlorhexidine is very often used for gingivitis treatment in Belarus, but it has limitations in its application in children [1].

The medicinal plants are widely used for the treatment of various types of dental pathology. Biologically active natural compounds are easily included into the metabolic processes of the body, have a wide spectrum of therapeutic action, a good tolerance and the low cost. People of

different age groups are able to use them with a minimum number of side effects.

The abundant chemical composition of plants, including various classes of compounds, determines their polyvalent action and effects on the pathological process [2,3,4]. The development of new effective and safe herbal medicines that provide a comprehensive pharmacological effect on all parts of pathogenesis is still relevant. Herbal drugs, according to their structure, have anti-inflammatory, hemostatic, wound healing and antimicrobial effects in gingiva therapy. The drugs with black alder contain tannins, flavonoids, phenol carboxylic acids. A decoction of fresh alder leaves, bark and cones is used in treatment of stomatitis and gingival bleeding in traditional medicine [1, 6]. Black alder leaves are used as diaphoretic, as well as in skin diseases therapy [5]. Experimental studies have confirmed the presence of anti-inflammatory, antimicrobial and antioxidant properties of extracts from black alder leaves [7,8,9].

Taking into account the experience of traditional medicine, the chemical composition and the results of studying the pharmacological activity the tincture from the leaves of black alder was used to obtain a soft dosage form-gel. It

was used in experiment for the treatment of inflammatory diseases of the marginal periodontium tissues.

The **aim of the work** is to evaluate the effectiveness of a phyto-gel in the treatment of experimental gingivitis.

## MATERIALS AND METHODS

The principles of bioethics were followed in accordance with the regulatory documents during the experimental study: "International Recommendations (Code of Ethics) for the conduct of biomedical research using animals" [10], "European Convention for the Protection of Vertebrate Animals used for Experimental and Other Scientific Purposes" [11], "Rules for working with experimental animals" (approved by the Academic Council of the Moscow State Medical Institute on 04.24.1996) [12], "Good laboratory practice" [13]. The research protocol was approved at the ethical commission meeting of the Belarusian State Medical University before the experiment.

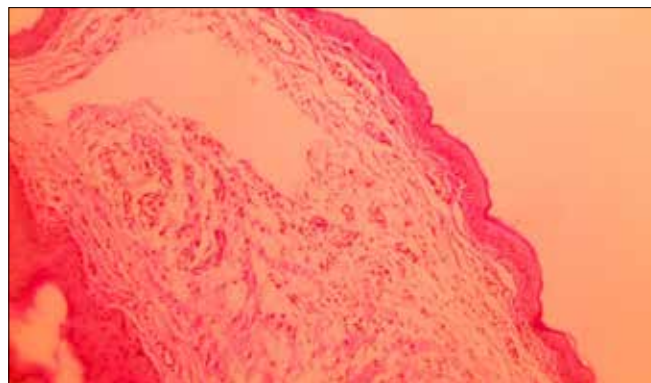
42 white Wistar rats aged 3 months were selected to simulate experimental gingivitis. They were randomly divided into 6 groups after the onset of clinical signs of inflammation: group 1A - animals that were treated with experimental gingivitis with a single application of a gel containing tincture of black alder leaves for 2 days; group 2A - animals that were treated with experimental gingivitis with a single application of a gel containing metronidazole for 2 days; group 3A - animals with experimental gingivitis (control group), group 1B - animals that were treated with experimental gingivitis with a single use of a gel containing tincture of black alder leaves for 4 days; group 2B - animals treated with experimental gingivitis with a single use of a gel containing metronidazole for 4 days; group 3B - animals with experimental gingivitis (control group). In animals 1A-3A of groups a biopsy was taken on the 8th day from the start of the experiment, in group 1B-3B on the 10th day from the start of the experiment.

The animal was injected once in the region of central incisors into the submucosal layer of gingiva with the drug "Vipraxon" (an aqueous solution of viper venom) in a volume of 0.2 ml to simulate experimental gingivitis. Therapeutic drugs (a gel containing tincture of black alder leaves and a gel containing metronidazole) were applied in a thin layer to the area of inflammation after the appearance of clinical signs of gingivitis (6 days from the beginning of the experiment).

All animals were fed a standard diet. A biopsy was taken in the area of the right lower incisor sized 1.0 × 1.0 cm. For histology material was kept in 10% neutral formalin. Later it was stained with hematoxylin and eosin. Micro-preparations were investigated using optical microscope and photographed (digital camera Levenhuk).

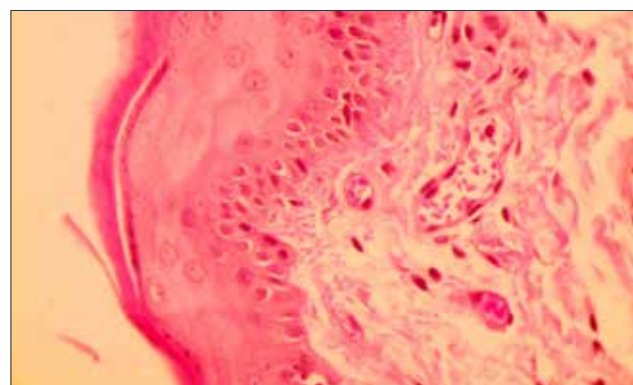
## RESULTS AND DISCUSSIONS

It was found that in the groups 1A and 2A clinical signs of inflammation decreased by the 2nd day of the use of drugs: in both groups there was only slight hyperemia of the marginal gingiva of the central incisors without signs of bleeding.



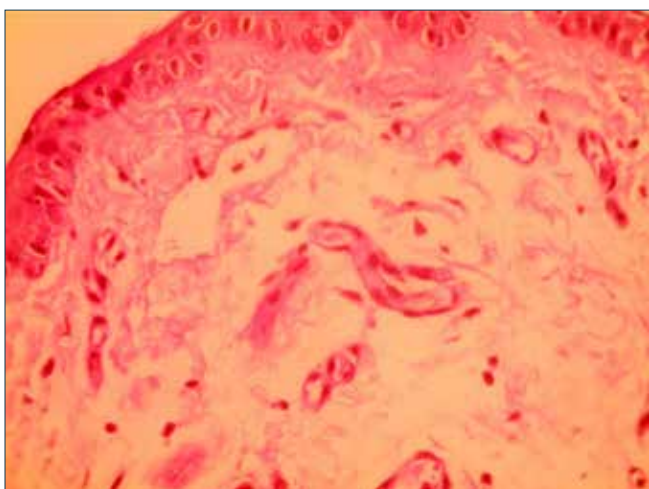
**Figure 1.** Rat gingival mucosa on the 8th day from the beginning of experiment. Vesiculation of stratum basale cells cytoplasm. Disintegration of cells of the stratum spinosum and stratum granulosum of the epithelium. Intracellular focal edema of the stratum granulosum of the epithelium. Vascular fullness (venous). Microscopical examination, H&E stain. Original magnification, x200.

In the histological preparations of gingiva in the group 1A (Figure 1) and the group 2A (Figure 2) was noted the restoration of connective tissue layer, however, structural changes in the epithelial cells of the stratum basale were preserved, while in the group 2A the number of such cells was more. Also in this group was defined disintegration of the cells of the stratum spinosum and stratum granulosum. There was a decrease in the smoothness of the papillae of the surface layer of the mucosal lamina propria in both groups, which remained swelling, infiltrated by single lymphocytes, mast and plasma cells. In the group 1A isolated areas of defibrination and fragmentation of fibrous structures were determined, while in the group 2A the number of such changes was higher. Both groups retained connective tissue vascular fullness.



**Figure 2.** Rat gingival mucosa on the 8th day from the beginning of experiment. Vesiculation of stratum basale cells cytoplasm. Disintegration of cells of the stratum spinosum and stratum granulosum. Edema and infiltration by lymphocytic cells. Vascular fullness (venous). Microscopical examination, H&E stain. Original magnification, x400.

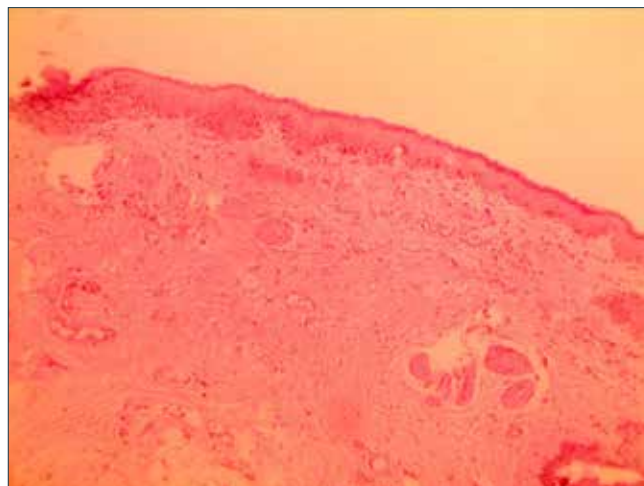
In the 3A group where no treatment was performed both clinical and histological signs of inflammation were noted. Redness and swelling of the marginal gingiva and gingival papilla, slight smoothness of the contour was visually preserved, bleeding was noted during touching. In histological preparations of gingiva intracellular edema of the stratum spinosum was determined, cell nuclei were shifted to the periphery, marked smoothness of the papillae of the surface layer of the mucosal lamina propria, edema, significant infiltration by cells of the lymphocytic range was noted. Areas of defibrination and fragmentation of fibrous structures, numerous vascular fullness was determined (Figure 3).



**Figure 3.** Rat gingival mucosa on the 8th day from the beginning of the experiment. Smoothness of the papillae of the mucosal lamina propria. Edema and infiltration by lymphocytic cells. Defibrination of fibrous structures. Microscopical examination, H&E stain. Original magnification, x400.

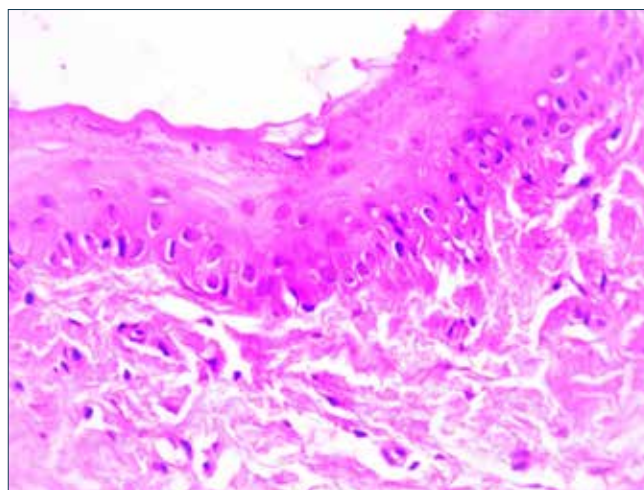
There was a complete disappearance of clinical signs of inflammation after using of drugs for 4 days in the 1B group and the 2B group: the gingiva had a gentle pink color, without changing the shape and contour, bleeding was absent.

In histological preparations of gingiva of animals from group1B the complete restoration of the gum structure was noted. The stratum basale was represented by layers of short cells located in places in the form of a stockade. The cells of the stratum spinosum were unbalanced arranged, there was no swelling of the epithelium. The mucosal lamina propria recovered completely and was represented by a fibrous connective tissue with a large amount of collagen and elastic fibers. Not numerous vascular fullness was preserved (Figure 4).



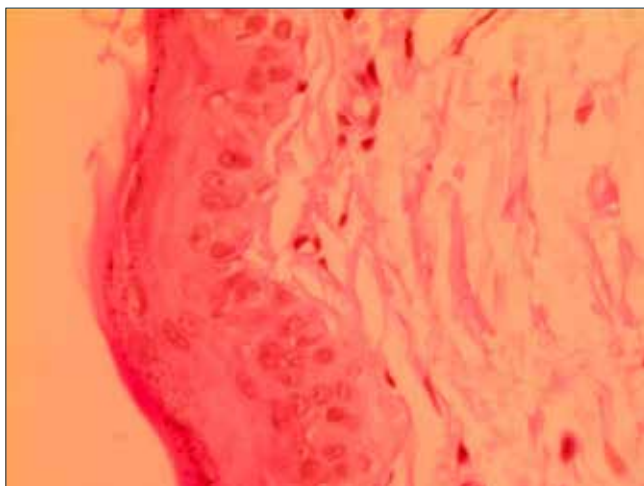
**Figure 4.** The mucous membrane of rat gingiva on the 10th day from the beginning of experiment. The stratum basale is represented by cells in the form of a stockade. The mucosal lamina propria is predominantly wide and low. Microscopical examination, H&E stain. Original magnification, x200.

In group2B intracellular edema of the epithelium of the stratum spinosum was noted. The process of reparation of connective tissue papillae of mucosal lamina propria was determined but swelling and vascular fullness (venous) persisted, endothelial cells were rounded, swollen. There were cell infiltrations, but defibrination of fibrous structures decreased (Figure 5).



**Figure 5.** The mucous membrane of rat gingiva on the 10th day from the beginning of experiment. Slight edema and infiltration by lymphocytic cells. Vascular fullness. Slight defibrination of fibrous structures. Microscopical examination, H&E stain. Original magnification, x400.

Only slight redness of marginal gingiva and smoothness of its contour were noted during visual inspection of the gingiva in group 3B, bleeding was absent. All the signs of the inflammatory process were preserved in histological preparations: changes in epithelial cells of the stratum basale, disintegration of cells of the stratum spinosum and stratum granulosum. The smoothness of the mucosal lamina propria papillae, edema and infiltration by lymphocytic cells were determined. There were defibrination and fragmentation of fibrous structures with the vascular fullness of numerous vessels of connective tissue (Figure 6).



**Figure 6.** The mucous membrane of rat gingiva on the 10th day from the beginning of experiment. Disintegration of stratum spinosum cells. Smoothness of mucosal lamina propria papillae. Edema and infiltration by lymphocytic cells. Fragmentation of fibrous structures. Microscopical examination, H&E stain. Original magnification, x400.

## CONCLUSIONS

It was found that after using a gel containing tincture of black alder leaves the restoration of gingival structure occurred after 4 days, while the use of a gel containing metronidazole did not lead to the disappearance of histological signs of inflammation. Thus, the high efficiency of the gel containing tincture of black alder leaves in the treatment of experimental gingivitis was established.

## REFERENCES

1. Ilyina, T.A. Medicinal plants of Russia / T.A. Ilyina. – M.: Eksmo, 2006. – 189 p.
2. Gurina N.S. Promising directions in the study of medicinal plants / N.S. Gurina, O. V. Mushkina, A.S. Bakun et al. // Mat. int. Conf., dedicated to the 60th anniversary of the pharmaceutical. Faculty of Modern Achievements of Pharmaceutical Science and Practice. – Vitebsk, 2019. – p. 60–63.
3. Karomatov Inomzhon Medicinal properties of alder / I.D. Karomatov, D.K. Aslanova // Biology and Integrative Medicine. – 2017. – No. 5. – p. 63–68.
4. G.V. Nesterov Influence of the fermentation process on the quality indicators of alder leaves of the species *Alnus Incana* (L.) and *Alnus Glutinosa* (L.) Gaerth / Nesterov G.V., Litvinova T.M., Kondrashev S.V. // Pulse. – 2020. – No. 22 (3). – p. 67–71.
5. Zuzuk BM Alder, alder *Alnusincan* (L.), Moench. Analytical review / BM Zuzuk [etc.] // Pharmacist. – 2007. – № 9. – p. 37–41
6. Dhaifallah Alshehria Treatment efficacy of photoactivated disinfection versus *Salvadora persica* gel in experimental gingivitis / Dhaifallah Alshehria, Ali Alqerbanb, Abdulaziz Samran // Photodiagnosis and Photodynamic Therapy. – 2020. – V. 29.
7. Mushkina O.V. Influence of extracts from the leaves of gray alder and black alder on the biochemical parameters of blood in generalized inflammation / O.V. Mushkin, S.A. Gurin // Bulletin of Vitebsk State University. – 2010. – No. 5 (59). – pp. 45–48.
8. Mushkina O.V. Antimicrobial activity of biologically active substances from *Alnusglutinosaleaves* / O.V. Mushkina, D.M. Petrovich, N.S. Gurin, I.I. Generalov // Actual problems of modern medicine and pharmacy: materials 59 total. scientific and practical conf. stud. and young scientists. – Vitebsk, 2007. – p. 218 – 220.
9. Mushkina O.V., Activity and total phenolic content of *Alnus glutinosa* and *Alnus incana* leaves / O.V. Mushkina, N. S. Gurina, M.M. Konopleva et al. // Acta scientiarum polonorum. Hortorum Cultu. – 2013. – V. 12(3). – p. 3–11.
10. International guidelines (code of ethics) for the conduct of biomedical research using animals. – 2018.
11. European Convention for the Protection of Vertebrate Animals used for Experimental and other Scientific Purposes. – 2020.
12. Denisov S.D. Requirements for a scientific experiment using animals / S.D. Denisov, T.S. Morozkina // Health. – 2001. – No. 4. – p. 40–42.
13. Technical Code of Good Practice “Good Laboratory Practice”, approved by the Resolution of the Ministry of Health of the Republic of Belarus dated March 28, 2008 No. 56