

# PNEUMOTORAX POSTTRAUMATIC: TIPURI, OPȚIUNI DE DIAGNOSTIC ȘI TRATAMENT

Rotaru Andriana

Catedra de Chirurgie Nr.1 “Nicolae Anestiadi”, USMF “Nicolae Testemițanu!”

## Introduction

Traumatic pneumothorax is air in the pleural space resulting from trauma and causing partial or complete lung collapse. Symptoms include chest pain from the causative injury and sometimes dyspnea. Diagnosis is made by chest x-ray. Treatment is usually with a thoracostomy tube.

## Keywords

Traumatic pneumothorax, lung collapse, thoracostomy tube, trauma, hemothorax, types of pneumothorax.

## Purpose

This topic is important for the prevention of post-traumatic pneumothorax, namely the vital consequences that could also be the use of other medical maneuvers to prevent pneumothorax.

## Material and methods

<https://www.ncbi.nlm.nih.gov/pmc/articles/PMC2700561/>;  
<https://www.atitimisoara.ro/content/ghiduri/2007/Conferinte%20Crisis%20Management/14%20Pneumotoraxul.pdf>;

## Results

Due to the early detection of post-traumatic pneumothorax, the drastic consequences for human health could be avoided.

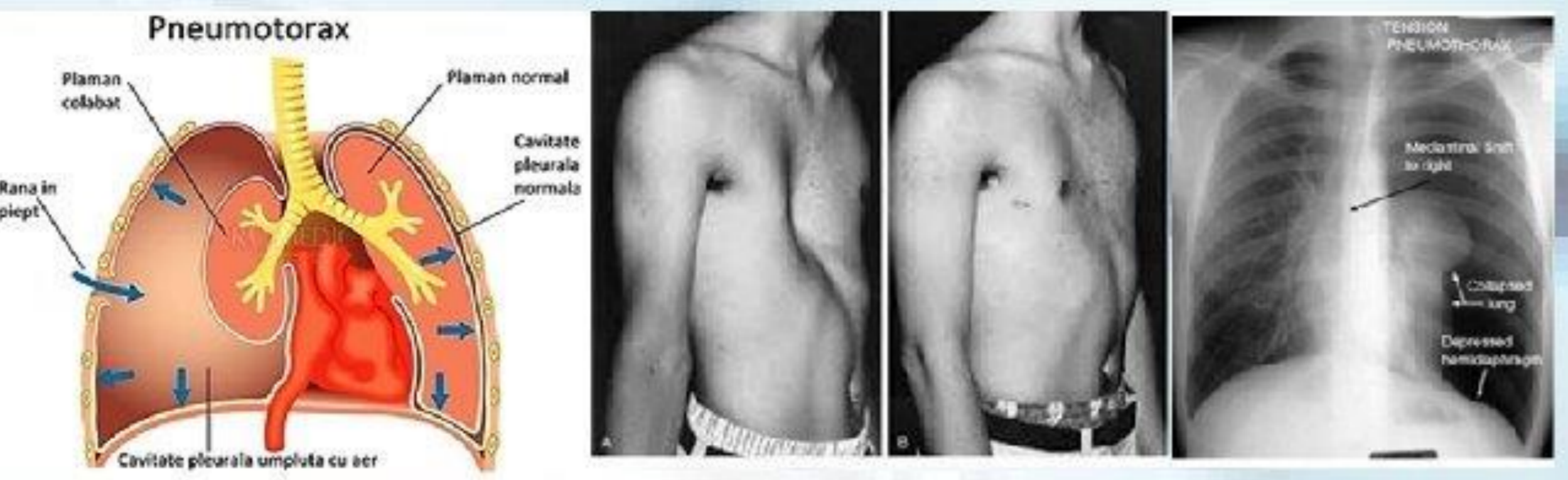
## Conclusions

Post-traumatic pneumothorax is a very serious pathology. Advise persons to wear seat belts and passive restraints while driving. However, medical maneuvers performed, such as subclavian vein cannulation or other transbronchial procedures, must be performed very carefully or as an alternative.

**PNEUMOTORAXUL POSTTRAUMATIC**

*Pneumotoraxul posttraumatic* reprezintă acumularea intrapleurală de aer ca urmare a unui traumatism toracic.

Severitatea simptomatologiei depinde de dimensiunile pneumotoraxului și de statusul respirator preexistent al bolnavului.



Radiologic se constată hipertransparență pulmonară corespunzătoare plămânului colabab, precum și deplasarea mediastinului.

Pneumotoraxul ocult este evidențiat la examenul tomografic, dar nu și pe radiografiile clasice toracice, apărând la 2- 12% dintre pacienții cu contuzii toraco-abdominale.

