

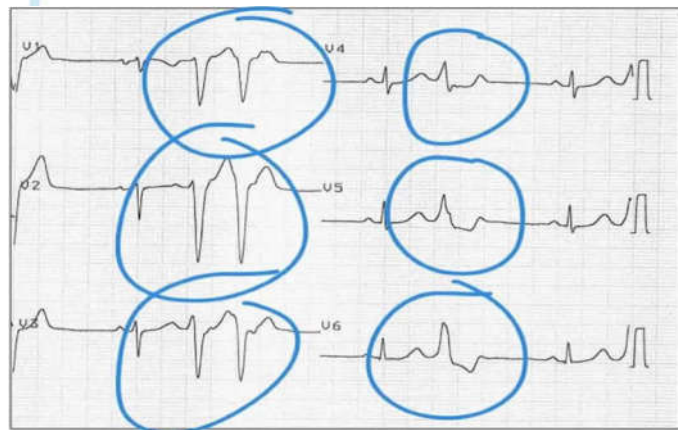
## THE EVOLUTION OF SUPRAVENTRICULAR AND VENTRICULAR PREMATURE BEATS IN CHILDREN

**Author:** Ostrovsky Avital

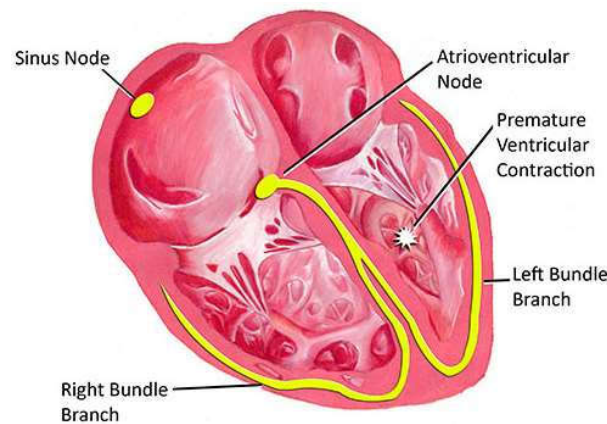
**Scientific advisor:** Romanciuc Lilia, Pediatric Department, USMF „Nicolae Testemițanu”.

**Introduction:** Supraventricular premature beats represent premature activation of the atria from a site other than the sinus node and can originate from the atria, A premature ventricular beats is caused by an ectopic cardiac pacemaker located in the ventricle.

**Purpose:** to evaluate the clinical and paraclinical manifestations in premature supraventricular and ventricular contractions in children (Figure 1).



**Figure 1.** Premature beats in ECG, Dr. J.A. and the HealthJade Team, 2019.



**Figure 2.** PVC mechanism, Merit Dr, Dallas, Pediatric Heart Specialists, 2022.

**Material and methods:** electronic databases (MEDSCAPE, UpToDate) was searched using a trailed search strategy in collaboration with books information (nelson book of pediatrics), the databases were symmetrically search and compared with the relevance of the study.

**Results:** premature ventricular contractions (PVCs) are less common (Figure 2) than premature atrial contractions (PACs) in infancy, PVCs were detected in 18% of normal neonates, PACs beats were detected in 51% of normal newborns but more common in older children. Recognizing symptoms depends on the age and maturity of a child. Older children may have lightheaded or palpitations. For infants and toddlers, may occur paleness of the skin, irritability, and disinterest in eating. The premature beat is not preceded by a P wave and the QRS complex is wide and bizarre. If the heart is structurally normal, and the premature beats are singleton, uniform in focus, and disappear with increased heart rate. Usually benign and require no treatment.

**Conclusions:** This poster was a review of the brief epidemiology, common clinical presentations and paraclinical changes in supraventricular and ventricular premature contraction in children.

**Keywords:** children, supraventricular and ventricular premature beats.