

ORIGINAL RESEARCHES

DOI: 10.5281/zenodo.3865972
UDC: 616.61-002.951.21



Isolated renal hydatid cyst in the primary generation of the larval cyst

*^{1,3}Jana Bernic, ^{2,3}Vergil Petrovici, ^{1,3}Victor Roller, ^{1,3}Anatolii Curajos, ^{1,3}Eva Gudumac

¹Natalia Gheorghiu Scientific Center of Pediatric Surgery, ²Department of Morphopathology
Institute of Mother and Child, Chisinau, the Republic of Moldova

³Natalia Gheorghiu Department of Pediatric Surgery, Orthopedics and Anesthesiology
Nicolae Testemitanu State University of Medicine and Pharmacy, Chisinau, the Republic of Moldova

Authors' ORCID iDs, academic degrees and contributions are available at the end of the article

*Corresponding author: jana.bernic@usmf.md

Manuscript received April 02, 2020; revised manuscript May 28, 2020; published online June 10, 2020

Abstract

Background: In the Republic of Moldova echinococcosis has a uniform geographical distribution, with an incidence of 10/100000 inhabitants. Renal hydatidosis occupies an important place in surgical pathology. Today's modern diagnostics and treatments of renal hydatidosis include, in addition to surgery, the drug therapy as well: Helmex, Albendazole, Mebandazole, etc. The surgical techniques in renal hydatidosis are adapted according to the clinical polymorphism of hydatidosis, the cyst topography, the multitude of hydatid vesicles, the volume of the cyst, as well as its complications.

Material and methods: The study materials included the anamnestic data, the preoperative diagnostic imaging methods, such as ultrasound, computed tomography and laboratory data, the surgical resolution, followed by the morphopathological assessment of the postoperative renal hydatid cyst specimen.

Results: Clinical and paraclinical assessment, characterized by a predominantly pain-related morbidity status, included the diagnostic imaging findings, which revealed a parapelvic cyst with no infiltrative or obstructive processes present. The histopathological examination of the cyst specimen showed the presence of proligerous membrane and daughter vesicles, which confirmed the diagnosis of a renal hydatid cyst.

Conclusions: Currently, the hydatid diseases, including the renal one, remain a major health problem, requiring specific surgical approaches and techniques. The surgical treatment of hydatid cysts is an individualized approach depending on their size and location, which might range from cystectomy or cyst enucleation to a complete removal of the impaired kidney.

Key words: renal diagnostic techniques, surgical treatment, children.

Cite this article

Bernic J, Petrovici V, Roller V, Curajos A, Gudumac E. Isolated renal hydatid cyst in the primary generation of the larvocyst. *Mold Med J.* 2020;63(2):5-11. doi: 10.5281/zenodo.3865972.

Introduction

Renal echinococcosis is a rare nosological entity, commonly revealed, due to the early patient's referral and diagnosis of thoracic and hepatic hydatidosis.

Secondary echinococcosis results from the evolution of the "small cycle". The parasitic echinococcus develops from scolex, which might graft on any living tissue. The "small cycle" may evolve on the same patient showing the following characteristics and mandatory stages: the rupture of the primitive vesicle, their release, grafting and the evolution of the host tissue scolices. The fertile scolices might evolve either into an adult form when they reach the intestine of the dog, or into a parasitic form, when they get into contact with the host's tissue due to a hydatid rupture.

The ruptured hydatid cyst may result from medical maneuvers, but commonly due to traumas, particularly in large cysts [1].

Thus, according to the aforementioned, the hydatid cysts denote the larval stage of a parasitic infection or echinococ-

cosis, caused by *Echinococcus granulosus*, an endemic parasite, showing a medical and biological impact and being commonly encountered in many countries worldwide [2, 3], including the Republic of Moldova.

The hydatid cyst disease was first described by Hippocrates, however it was more accurately defined by Goeze, J. A. E. [4] and Leuckart R. [5], who discovered its parasitic origin. Vogel H. [6] describes the evolutionary cycle of the parasite: (*Taenia echinococcus*), the larval stage in humans – intermediate host – hydatid disease.

The major steps in highlighting the etiopathogenesis, diagnosis and treatment of this parasitic disease were made at the beginning of the 20th century by F. Deve, who was also considered as founder of Modern Hydatidology [7].

The biological, epidemiological, and clinical aspects of the disease were further revealed by Eckert J. and Deplazes P. [8]. In the Republic of Moldova, many outstanding surgeons like professors Constantin Țibirnă, Natalia Gheorghiu, Eva Gudumac, Gh.Ghidirim, Gh. Grosu, Stanislav Babuci and

Alexandru Jalbă performed surgical interventions on hydatid cysts in children, thus describing a number of diagnostic techniques, surgical resolutions and prophylaxis for preventing recurrences [9-15].

Over the last decades, the morbidity rate in the southern regions of the Republic of Moldova accounted for 9.13-15.5% per 100000 inhabitants [16, 17]. The most commonly reported human cases involved liver, followed by impaired lungs, and other organs, including kidneys that make up 8-10% [18, 19]. Isolated primary renal echinococcosis in primary human infection accounts for 1.5%-5.0% [20], however, its occurrence being briefly reported in single clinical cases among children [21, 22].

The purpose of this study is to highlight the diagnostic and surgical management applied for isolated hydatid cyst with primary generation of larval cysts in kidneys.

Material and methods

Over the last 20 years, 4 cases with renal cysts were examined and operated at *Natalia Gheorghiu* Clinic of Pediatric Surgery. It should be mentioned that 2 patients underwent surgical interventions on renal hydatidosis with concomitant pulmonary hydatid cysts on both lungs (1), both lungs + liver (1), two isolated cases on the kidneys, of which one patient exhibited a “crushed eggshell” type due to trauma. The assessment of the anamnestic data, ultrasound or CT preoperative diagnosis, the intraoperative characteristics and the morphopathological studies were carried out within the postoperative period of the patients enrolled in the study. The biological specimens were collected according to the current research principles, approved by the Research Ethics Committee of *Nicolae Testemitanu* State University of Medicine and Pharmacy (positive opinion dated on May 13, 2015, report No 55). The histological examination was carried out by assessing and processing the pericystic surgical material and larval cysts, according to the standard histological procedures [23].

Results

The diagnosis included the ultrasound and CT scan exams. The diagnostic strategy, based on the technical findings and interpreted according to specific principles, was followed by a detailed study of the adjacent organ relationships, being a main stage of a CT diagnosis in cases of renal hydatid cysts. The CT assessment of the surrounding organs allows to establish the compression degree of an organ, due to an expansive process, invasion of the hollow organ wall, displacement of a hollow organ, or abnormal rotation of the impaired kidneys. The immunological tests are of great importance, though, they are not always available and do not reveal the anatomical location of a hydatid cyst [21]. The diagnostic strategy also involves both anamnestic and imaging data (abdominal and urinary ultrasound, computerized tomography (CT), magnetic resonance imaging (MRI), and renal scintigraphy), which allow to establish not only the cyst location, but also its relation with other surround-

ing organs, density measurement, the cyst size, as well as images from sagittal planes, etc. [1].

CT scanning is a basic imaging method for diagnosing a renal hydatid cyst. The contrast medium administration (in CT angiography) will be differentiated and adjusted to each individual case depending on the particularities, in order to exclude possible involvement of the vascular structures.

It is worth mentioning that, there has not been developed any complete efficient surgical approach for the treatment of this pathology, so far. However, the current method of choice for the resolution of the hydatid cyst, including the renal one is still the surgical treatment, being maximally conservative and oriented towards the maintenance of renal function [24].

The specialized literature has described a number of techniques for diagnosis and surgical management of hydatidosis, including those encountered in children, which mainly attempt to solve two major problems: surgical removal of the hydatid cyst and drainage of the pericystic cavity. However, the abundance of the surgical techniques actually proves that no method is an ideal criterion for solving these two major problems. A major concern related to hydatidosis, is that like any parasitic disease, it might graft on any healthy organs or those impaired by various acquired congenital disorders such as hydronephrosis, renal hypoplasia, renal multicystosis and ureteral calculi, which might also affect both the proper diagnosis and positive disease prognosis [25]. There is a difficulty in establishing the diagnosis of this disease, since only 4 cases of renal hydatid cyst, caused by activity outside the disease- endemic area, have been detected in the Republic of Moldova. The impact of diagnostic errors might trigger an inadequate individualized surgical approach, as well as improper prophylactic treatment of these patients. Therefore, we analyzed and presented the anamnestic and diagnostic data, as well as the surgical resolution, followed by the morphopathological study of the postoperative specimen of a recently operated clinical case, dated on 10.02.2020.

We believe that this clinical case will be useful for young specialists, who are interested in this pathology.

Clinical case study

The morbidity data. According to the hospital registry data, a 6-year-old female patient, A.D., was admitted to the Department of Urology, at the Mother and Child Institute and at *Natalia Gheorghiu* Clinic of Pediatric Surgery, with abdominal and low back pain lasting for 6 months since the disease onset. Over 6 years the patient did not present any renal-related complaints. At the age of 5 years 6 months, the patient began to feel pain in the abdomen and in left lumbar region. The patient underwent a treatment within the outpatient department, by administering antibiotics and antispasmodics. Even though the pain subsided, it persisted periodically, accompanied by febrile syndrome. The patient was assessed for the causative factor of the morbid status within our clinic, based on the diagnostic, imaging and paraclinical research protocols.

Imaging diagnosis. The patient underwent the primary ultrasound assessment of the urinary system on 06.02.20, which revealed an anatomical dissociation of the kidney size with the following data: the right kidney – 80x31mm, the parenchyma – 10 mm, the right renal pelvis – 2mm, slightly deviated left kidney compared to the right one – 88x31 mm, the parenchyma – 10 mm and the left renal pelvis – 2 mm. A 55x29 mm formation was determined in the left lower middle part of kidney, featured by a solid + fluid content and regular renal contour (fig. 1A). The dynamic contrast-enhanced spiral CT (fig. 1B) of the kidneys (arterial and nephrogenic phase), dated on 05.02.20, revealed a more detailed assessment of the cystic lesion. CT images showed 7.6 cm for longitudinal right diameter and 7.5 for left diameter. Homogeneous right parenchymal and left intraparenchymatous patterns were revealed on the lateral-medial surface. A cyst formation with a size of 4.8x3.8x2.6 cm (vertical x transverse x anteroposterior) was found within the middle 1/3 of the kidney that extended into the parapelvic

lowering levels of albumin – 46.3 (reference range 38-54 g / l), aspartate aminotransferase – 14.5 (reference range 0-32 U/L), direct bilirubin – 0.50 (reference range 0-5 μ mol / l), total bilirubin – 12.6 (reference range 0-21 μ mol / l), serum creatinine – 46.0 (reference range 64-83 μ mol / l), total protein – 65.0 (normal range 60-80 g / l), fibrinogen – 2.1 (normal range 2-4 g / l), INR values – 1.08 (normal range 0.85-1.25), Quick prothrombin values – 83.3 (normal range 70-130%).

On 6.02.20, the urinalysis showed the following: the urine amount – 40 ml, yellow urine color, density – 1020, acidic urine reaction, transparent, absence of proteins, flat epithelial cells 4-6/hpf, WBC 3-6/hpf. The clinical and paraclinical assessment showed a predominant pain-related morbidity status, whereas the diagnostic imaging data revealed the presence of a parapelvic cyst with no infiltrative or obstructive processes. No serological investigations were available at that moment. The location and size of the cyst, the risk of developing complications such as obvious compression of the pelvicaliceal system, as well as an infection

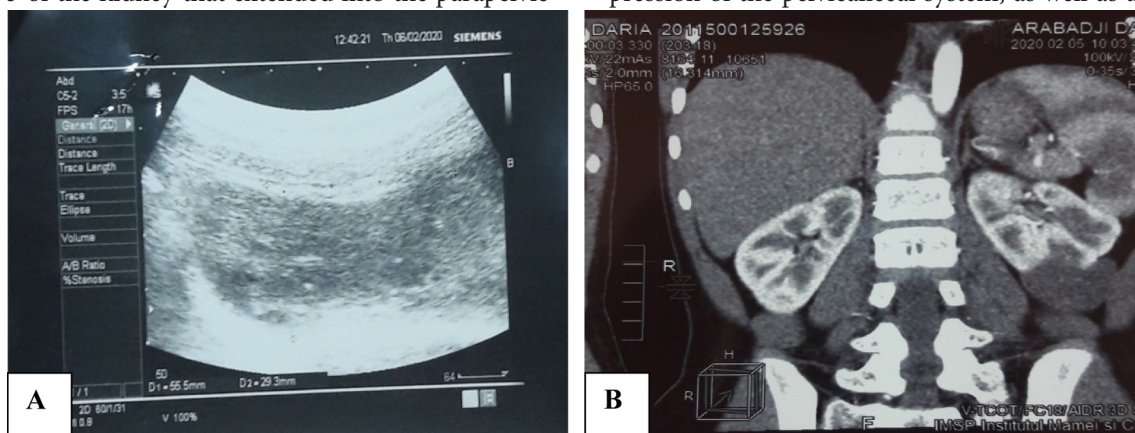


Fig. 1. Ultrasound and CT imaging patterns: A – The left kidney ultrasonography, 55x29mm cyst formation, solid + fluid content, regular contour in the lower and middle pole; B – The left parapelvic renal cyst of Bosniak type I.

and retroperitoneal space of a polygonal shape, clearly contoured with homogeneous content (native density + 12 UH, post-contrast – at minimum amplification, no intrastromal septa, wall thickness, no calciform inclusions, moderate exert of mass effect on the left kidney). Anterior rotation of the lower pole. Equal bilateral corticomedullary density. Normal right pelvis system was determined over 3 minutes after the intravenous introduction of the iodine substance. A compressed left pelvis system was also found on the aforementioned formation. Conclusion: Imaging data suggested a left parapelvic solitary renal cyst of Bosniak type I.

The paraclinical diagnosis included the hemolothogram, blood biochemistry, and urinalysis. On 05.02.2020, the hemolothogram revealed: Hb – 112 (reference range 115 – 137 g / l), RBC – 3.60 (reference range 4.1-4.5 x 10¹² / L), color index – 0.92 (reference range 0.71-1.01), WBC – 8.8 (reference range 5.7-8.7 x 10⁹ / L), non-segmented neutrophils – 9.0 (reference range 1-3%), segmented neutrophils – 41 (reference range 43-59%), eosinophils – 5.0 (baseline blood range 3.0-4.6%), monocytes – 3.0 (baseline blood range 4-8%).

Blood biochemistry, dated on 5.02.2020, revealed the fol-

lowing levels of albumin – 46.3 (reference range 38-54 g / l), aspartate aminotransferase – 14.5 (reference range 0-32 U/L), direct bilirubin – 0.50 (reference range 0-5 μ mol / l), total bilirubin – 12.6 (reference range 0-21 μ mol / l), serum creatinine – 46.0 (reference range 64-83 μ mol / l), total protein – 65.0 (normal range 60-80 g / l), fibrinogen – 2.1 (normal range 2-4 g / l), INR values – 1.08 (normal range 0.85-1.25), Quick prothrombin values – 83.3 (normal range 70-130%).

Surgical treatment

On February 10 2020, the child underwent a classic surgical intervention via lumbotomy incision on the left, which revealed a cystic white-yellowish formation within the paranephral / retroperitoneal space that was 5.0 x 2.5 cm in size. A jelly-like fluid with a translucent capsule was found at the opening of the thickened tissue capsule, suggesting a hydatid cyst (fig. 2). A conservative surgical approach was considered in order to preserve normal kidney functioning. Simple internal endocyst excision, followed by internal excision of the capsule and pericyst were performed after the removal of the cystic content. The residual wall cavity was carefully processed with 10% polyamine iodide solution. Subsequently, the hemostatic tamponade of the cyst cavity was performed through the paranephron tissue, followed by application of drainage and a layered wound suturing.

In this case, the surgical technique was adapted according to the location and size of the renal hydatid cyst, in or-

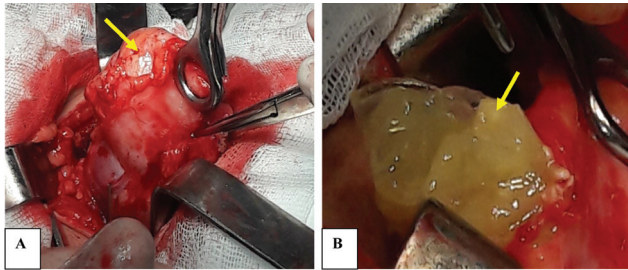


Fig. 2. Intraoperative features of the hydatid cyst: A – The lower pole of the left kidney distorted by the cyst; B – Opening of the pericyst, translucent yellowish-colored hydatid cyst, with a small yellowish-pale plateau.

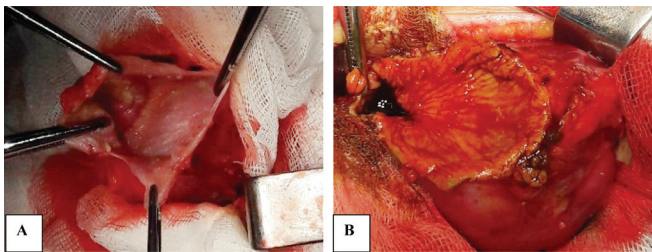


Fig. 3. Intraoperative pericyst features. A – The pericystic cavity after the extraction of the larval cyst; B – The remaining superior renal pole after the resection of the pericyst and treatment with 10% Betadine solution.

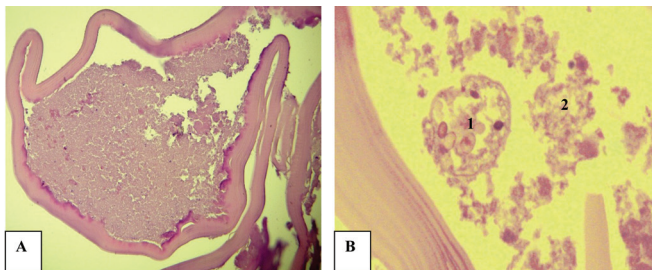


Fig. 4. The general pattern of the hydatid cyst: A – Lamellar cuticle with a microgranular mass of hydatid fluid $\times 25$. H-E coloring; B – The germinating layer – degenerating dead protoscoleces (1), disintegrated prolifer membrane (2). $\times 200$. H-E coloring.

der to perform the intact ablation of the hydatid vesicle with preservation of the pericyst.

The intraoperative morphological patterns are reflected within the following figures (fig. 3, 4, 5, 6 and 7). A small prominent yellow-pale plateau in the lumen was observed through the translucent larval cystic wall.

After the removal of the larval cyst contents, the pericyst exhibited elasticity, with a minimum thickness of 0.1-0.15 cm, sometimes up to 0.3 cm. The internal surface revealed a pinkish colored appearance with small, non-significant yellowish foci, and no blood vascular fistulas present.

The histological examination of the excised surgical specimen of the translucent cyst and pericyst confirmed the parasitic origin, as well as the morphological particularities of the renal cyst formation (fig. 4). A primary larval stage of the Echinococcus granulosus cestode was detected from the proliferating membrane and lamellar cuticle with dystrophic and necrotic changes that characterized a dead lar-

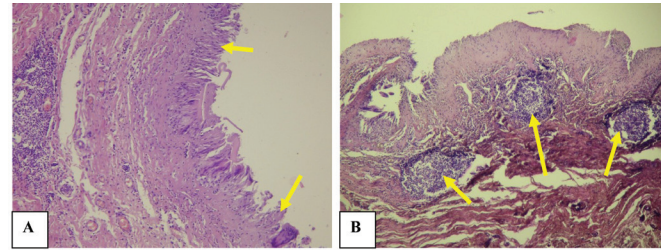


Fig. 5. General pericyst pattern: A – The inner surface of the pericyst in polynuclear giant simplast layers in palisade $\times 50$ H-E coloration; B – Sclerosis of the pericyst surface, hyalinized by well-circumscribed lymphoid follicles in chain. $\times 25$. H-E coloring.

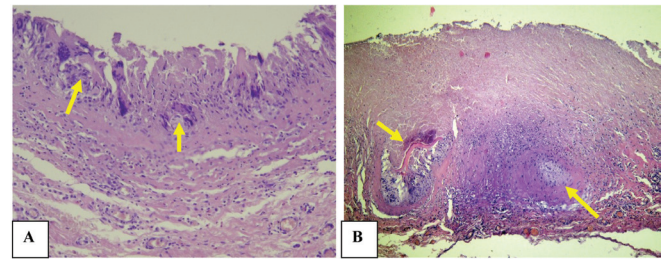


Fig. 6. Extra germ migration patterns: A – Necrotic simplast layers in palisade with formation of epithelial nodules surrounding the parasitic microvesicles $\times 50$. H-E coloring; B – Small dead cysts in the pericyst region within necrotic areas. $\times 25$. H-E coloring.

val cyst, though a former outbreak fertilization activity was observed intraoperatively in the plateau aspect. Cyst fertility was proved by presence of degenerating protoscoleces in the larval mass (fig. 4).

The pericyst was mostly characterized by tissues of the host organ with fibrillar connective tissue and a reduced focal fibrosis, whereas the internal surface consisted of simplast polynuclear palisade cells. The fibrillar and connective features of the pericyst showed a chaotic, slightly dispersed lymphocyte cellular component, whereas some lymphoid follicular structures were found between the pericyst and parenchyma border (fig. 5A). The subcapsular area of the upper pole revealed areas, which were lacking simplast palisade cells with a marked sclerosis, including hyalinization with discrete cellular aspect, while the perifocal area showed multiple well-circumscribed lymphoid follicles in chain (fig. 5B).

Some areas concomitantly exhibited superficial necrotic foci on the simplast layer of palisade cells, as well as the presence of actively proliferating cell nodules with pseudo-microvesicular inclusions within their surrounding areas and on the borders with the pericyst. A distinct eosinophilic cell component was found in the fibrillar structure of the connective region (fig. 6A). Therefore, we might conclude that these particularities of common pericyst with degenerative changes of the larval cyst justify the pathway for germ cell migration. It was also confirmed by the presence of marked necrotic changes of the pericyst within some regions, or being transformed into a mass of cellular debris with smaller mortified cysts, followed by a pronounced inflammatory

response (fig. 6B). The pericystic area revealed no renal parenchyma. The pericystic vascular network had no endo- or perivasculitis, thrombi or parasitic elements. A non-significant sclerosis with solitary glomeruli was observed adjacent to its borders.

The final morphopathological diagnosis: A primary renal hydatid cyst (*echinococcus granulosus*) with a maternal mortified larval cyst and peri-larval mortified daughter vesicles were identified, as well as reactive focal and inflammatory necrolytic features within the pericyst, suggesting a risk for spread. The intensive postoperative therapy was aimed at managing the volume loss and maintaining the fluid-clotting balance, as well as the active assessment of the liver and kidney functions.

The postoperative period did not show any complications. Over 10 days, the child had a satisfactory condition and underwent an USI scanning. The child was discharged, being referred to and supervised by the family doctor. The patient was administered the following drug therapy: Escazole 400 mg, 1 tablet/day, per oral during mealtimes for 5 days. After being discharged from the Pediatric Urology Clinic, the patient data were included in a dispensary protocol carried out by the family doctor. The child was examined on the 20th day after the hospital discharge. The child proved to be healthy with no signs of renal disorder or other distant complications.

Discussion

Human echinococcosis, due to its medical, social and economic impact, remains a constant issue for surgeons, parasitologists and epidemiologists, who are interested in its invasive-destructive patterns affecting the liver and lungs, rarely involving kidneys and spleen [11, 14, 15, 18, 26, 27]. This disease is considered hyperendemic in Moldova. However, recent studies of the molecular biology of cystic echinococcosis in humans and pigs have reported both *Echinococcus granulosus sensu stricto* and *Echinococcus canadensis* G6 / G7 within several outbreaks from our country [28].

In the Republic of Moldova, renal echinococcosis, especially in children, rarely occurs, thus making it difficult to establish the diagnosis, particularly in cases of malignancy [17, 20].

A number of studies have highlighted the particular epidemiological patterns of this disorder, namely, its evolution towards the cystic extension and total destruction of renal parenchyma, the uncommon and severe features of this cyst type, specific precautions that should be considered by the surgeons during the surgical intervention, as well as the preventive measures to avoid the infection [17].

Most studies report that the hydatid cysts are spherical fluid-filled, unilocular vesicles, defined as “rock water”. Three membranes limit the hydatid larva: 1. Internal, fragile, or proligerous membrane. 2. External, with a milky yellowish appearance. 3. Peripheral, the surrounding tissues are removed, showing a sclerotic reaction of the interstitial

connective tissue, which forms a third membrane, thus justifying the absence of the cleavage plane during the surgical procedure. The anatomical and pathological evolution is oriented towards the increase of the cyst volume. The third membrane becomes sclerotic and calcified, being visible on CT [20, 23].

Renal hydatid cyst may be primary or secondary, single or multiple, with or without concomitant parasitic damage of the adjacent organs. Sometimes, complicated evolutions of the disease have been reported. The most serious complications include the cyst rupture within the excretory pathways, characterized by hematuria, puria, hydraturia, etc. Ruptures in the surrounding organs have also been described i.e. pleura, lungs, peritoneum [3, 17, 29, 30]. Therefore, cysts can affect different organs. Typically, 70% of tapeworm eggs are filtered within the liver; however, if these pass through the liver border, they might get into the lungs. Commonly, the cysts might be accidentally discovered on an occasional ultrasound imaging, thus a differentiated diagnosis is required to exclude other cystic formations that can be located in the liver and less frequently in the kidneys. This disease causes moral and cost prejudices within population, thus the medical and veterinary authorities are facing the problem for improving the prevention and control measures of echinococcosis [20, 27].

Conclusions

1. Echinococcosis, including the renal one, remains one of the most significant problems, requiring specific surgical approaches and techniques.

2. The severity of the parasitic cyst infections arises from their multiple localization and the superimposed surface, which leads to associated complications.

3. The disease is encountered in most countries worldwide and currently affects about one million people. Albendazole is used in patients with hydatid cyst before and after the surgery, if a cyst rupture occurred or if live cysts have been discovered during the surgical intervention, due to a percutaneous drainage of the cyst for diagnostic or therapeutic purposes. Pre-operative administration of mebendazole has been applied in all reported cases. The direct echinococcosis-related mortality rate is low (0.29-0.60%), though being accompanied by recurrent incidence in nearly 10% of cases.

4. The individualized surgical treatment is selected based on the size and location of the hydatid cysts, ranging from cystectomy treated by enucleation to a complete removal of the impaired kidney.

5. A mandatory medical treatment with Mebendazole or Albendazole (dose of 5 mg / kg / day, post-operatively for a period of 28 days, with a 14-day break) is given both before and after surgery, to prevent hydatid recurrences. Pre- and post-operative intensive treatment with antibiotics was also administered to control the suppurative, inflammatory phenomena, followed by uroseptic drugs (Furamag, Furagin, No-Cyst).

6. Hydatid diseases, including the renal ones require an adequate selection and a collaboration between various specialists like pediatric surgeons, pediatric anesthesiologists and reanimatologists, imaging specialists and pathomorphologists.

7. Despite the popularity of the medical treatment, the surgical approach is still a method of choice in treatment of a hydatid disease, especially in cases of giant and ruptured cysts, as well as in those suppurative and calcified ones.

8. The selection of a surgical approach depends on the clinical situation, associated with administration of anti-parasitic therapy (Albendazole, Escazole, Doxycycline, and Helmex), which allows to prevent the post-hydatid disease, characterized by cavity remnants, hemorrhage and secondary recurrences.

9. The follow-up of all the surgical cases, carried out at 1-6 month intervals did not reveal any recurrent cases.

References

- Zmerli S, Ayed M, Horchani, et al. Hydatid cyst of the kidney: diagnosis and treatment. *World J Surg*. 2001;25(1):68-74.
- Horchani A, Noura Y, Kbaier I, Attyaoui F, Zribi AS. Hydatid cyst of the kidney: a report of 147 controlled cases. *Eur Urol*. 2000;38(4):461-7.
- Ramteke VV, Deshpande NS, Balwani MR, Bawankule CP. Primary renal echinococcosis. *Indian J Nephrol*. 2017 Jul-Aug;27(4):316-318.
- Goeze JAE. Des Herrn Baron Karl Degeer Koniglichen Hofmarschalls. *Abhandlungen zur Geschichte der Insekten aus dem Franzosischen ubersetzt und mit Anmerkungen herausgegeben*. Vol. 6 [Baron Karl Degeer's royal court marshal. *Treatises on the history of insects translated from French and published with annotations*]. Nurnberg: Raspe; 1782. 200 p., 30 pls. German.
- Leuckart R. *Die Blasenbandwürmer* [The bladder-tapeworms]. Giessen, Germany;1856. German.
- Vogel H. Über den *Echinococcus multilocularis* Süddeutschlands. I. Das Bandwurmstadium von Stämmen menschlicher und tierischer Herkunft [*Echinococcus multilocularis* in South Germany. I. The tapeworm stage of strains from humans and animals]. *Z Tropenmed Parasitol*. 1957;8:404-54. German.
- Dévé F. L'échinococcose alvéolaire [The alveolar echinococcosis]. *Prensa Med Argent*. 1932;19:966-76. French.
- Eckert J, Deplazes P. Biological, epidemiological, and clinical aspects of echinococcosis, a zoonosis of increasing concern. *Clin Microbiol Rev*. 2004 Jan;17(1):107-35.
- Babuci S. Argumentarea patogenetică și clinico-morfopatologică a tratamentului medico-chirurgical în hidatidoza pulmonară la copil [The pathogenetic and clinico-morphopathological argumentation of the medico-surgical treatment in pulmonary hydatidosis in children] [dissertation abstract]. Chisinau: *Nicolae Testemitanu* State University of Medicine and Pharmacy; 2005. 31 p. Romanian.
- Gudumac E, Babuci V, Dionidis I, Fuior I, Petrovici V. Corelații diagnostice morfologice și scintigrafice în hidatidoza hepatică la copii [Morphological and scintigraphic diagnostic correlates in hepatic hydatidosis in children]. *Arta Medica* (Chisinau). 2007;(4):133. Romanian.
- Gudumac E, Babuci S, Jalbă A, Petrovici V. Valoarea senzitivă a metodelor imagistice de diagnostic în chistul hidatic pulmonar la copil [Sensitive value of diagnostic imaging methods in pulmonary hydatid cyst in children]. *Asociația chirurgilor pediatri universitari din Republica Moldova: Anale științifice* [Association of University Pediatric Surgeons of the Republic of Moldova: *Scientific Annals*]. 2003;3:30-34. Romanian.
- Gudumac E, Babuci V, Petrovici V, Malanco S. Tehnici medico-chirurgicale de rezolvare a cavităților reziduale în chistul hidatic hepatic la copil [Medical-surgical techniques for solving the residual cavities in the hepatic hydatid cyst in the child]. *Asociația chirurgilor pediatri universitari din Republica Moldova: Anale științifice* [Association of University Pediatric Surgeons of the Republic of Moldova: *Scientific Annals*]. 2007;9:9-14. Romanian.
- Gudumac E, Babuci S, Tcacenco V, Jalbă A. Chistul hidatic pulmonar la copil: Recomandări metodice [Lung hydatid cyst in children: Methodical recommendations]. Chisinau; 2006. 32 p. Romanian.
- Gudumac E, Jalbă A. Particularitățile etiopatogenetice, clinice și diagnostice ale echinococozii chistice umane [The etiopathogenetic, clinical and diagnostic features of human cystic echinococcosis]. *Asociația Chirurgilor Pediatri "Natalia Gheorghiu": Anale științifice* ["Natalia Gheorghiu" Pediatric Surgeons' Association: *Scientific Annals*]. 2010;12:79-90. Romanian.
- Ghidirim G, Mișin I, Condrașchi E. Hidatidoza lienală. [Splenic hydatidosis]. *Arta Medica* (Chisinau). 2009;(2):58-61. Romanian.
- Gogus O, Beduk Y, Topukcu Z. Renal hydatid disease. *Br J Urol*. 1991;68(5):466-469.
- Radu M, Sima C, Badescu D, Constantin T, Jinga V. Dubla afectare renală: tumora chistică și hidatidoza – prezentare de caz [Double renal impairment: cystic tumor and hydatidosis – case presentation]. [Romanian *Med J*]. 2014;61(4):325-327. Romanian.
- Bondari L, Bondari V. Cercetări asupra epidemiologiei și epizootologiei echinococozii/hidatidozei în R. Moldova [Research on the epidemiology and epizootiology of echinococcosis/hydatidosis in Moldova]. [Romanian *J Parasitol*]. 1998;8(1):67-68. Romanian.
- Sarah JM, Christopher WJ, Warren DJ. Parasitic diseases of the genitourinary system. In: Wein AJ, Kavoussi LR, Novick AC, Partin AW, Peters CA, editors. *Campbell-Walsh Urology*. 9th ed. Philadelphia: Saunders; 2007. p. 458-9.
- Prisacari V, Pinteau V, Lungu V, Iarvoiu P. Echinococoză (hidatidoza): etiologie, patogenie, tabloul clinic, diagnostic, tratament, epidemiologie și profilaxie: Indicații metodice [Echinococcosis (hydatidosis): etiology, pathogenesis, clinical picture, diagnosis, treatment, epidemiology and prophylaxis: Methodical recommendations]. Chisinau; 2012. 29 p. Romanian.
- Sarmast AH, Sherwani AY, Dangroo SA, et al. An isolated renal hydatid cyst in 6-year-old child: a rare case report. *J Res Med Sci*. 2014 Mar;19(3):279-281.
- Cankorkmaz L, Korğalı E, Atalar MH, Köylüoğlu G. Case report: isolated renal hydatid cyst in a boy. *Türkiye Parazitoloj Derg*. 2019 Jun 17;43(2):89-91.
- Petrovici V. Particularități clinico-morfopatologice ale hidatidozei hepatice la copil [Clinical-morphopathological features of hepatic hydatidosis in children] [dissertation]. Chisinau: *Nicolae Testemitanu* State University of Medicine and Pharmacy; 2012. 170 p. Romanian.
- Rexiati M, Mutalifu A, Azhati B, Wang W, Yang H, Sheyhedin I, Wang Y. Diagnosis and surgical treatment of renal hydatid disease: a retrospective analysis of 30 cases. *PLoS One*. 2014;9(5):e96602.
- Ciubotaru M, Ciută C, Andricu R, Nechifor V, Miron A, Costache C, Pricop C. Chist hidatic renal asociat litiazei ureterale – probleme terapeutice [Renal hydatid cyst associated with ureteral lithiasis – therapeutic problems]. [Romanian *J Urol*]. 2014;13(2):110. Romanian.
- Rădulescu A, Farcaș C, Dinu M, Mădan V, Bratu O, Spânu D, Popescu R, Botea V, Mischianu D. Localizare rară a bolii chistice hidatice [Rare location of hydatid cystic disease]. [Romanian *J Urol*]. 2014;13(2):108. Romanian.
- Eckert J, et al, editors. *WHO/OIE manual on echinococcosis in humans and animals: a public health problem of global concern*. Paris: OIE; 2001. 286 p.
- Umhang G, Chihai O, Bastid V, et al. Molecular identification of cystic echinococcosis in humans and pigs reveals the presence of both *Echinococcus granulosus* sensu stricto and *Echinococcus canadensis* G6/G7 in

- the hyperendemic focus of the Republic of Moldova. *Parasitol Res.* 2019 Oct;18(10):2857-2861.
29. Juravle I, Mihaly A, Dobrota F, et al. Chist hidatic renal rupt in caile urinare [Broken renal hydatid cyst in the urinary tract]. [*Romanian J Urol*]. 2014;13(2):109.
30. Kriger AG, Vishnevskii VA, Son AI, Lomovtseva KKh. Disseminirovanoe porazhenie briushiny posle laparoskopicheskogo udaleniiia ekhinkokkovoii kisty pochki [Disseminated peritoneal lesion after laparoscopic removal of renal hydatid cyst]. [*Pirogov Russian J Surg*]. 2015;(11):71-74. Russian.

Authors' ORCID iDs and academic degrees

Jana Bernic, MD, PhD, Professor of Pediatric Surgery – <https://orcid.org/0000-0001-6991-9814>.

Vergil Petrovici, MD, PhD, Assistant Professor of Morphopathology – <https://orcid.org/0000-0001-8352-4202>.

Victor Roller, MD, Assistant Professor of Pediatric Surgery – <https://orcid.org/0000-0002-3003-6886>.

Anatolii Curajos, MD, Pediatric Urologist – <https://orcid.org/0000-0002-5655-434X>.

Eva Gudumac, MD, PhD, Academician, Professor of Pediatric Surgery – <https://orcid.org/0000-0001-8474-4338>.

Authors' contribution

JB drafted the first manuscript, VP acquired and interpreted the morphological data, VR interpreted the data, AC collected the data, EG designed the trial and revised the manuscript critically. All the authors revised and approved the final version of the manuscript.

Funding

The study was supported by Institute of Mother and Child and *Nicolae Testemitanu* State University of Medicine and Pharmacy. The authors are independent and take responsibility for the integrity of the data and accuracy of the data analysis.

Ethics approval and consent to participate

The research protocol No 55 (of June 18, 2015) was approved by the Research Ethic Board of *Nicolae Testemitanu* State University of Medicine and Pharmacy.

Conflict of Interests

The authors have no conflicts of interests to declare.

