

Obliteration and reconstruction of the mastoid cavity with auto osteomatrix forte autograft

Sergiu Vetricean, MD, PhD, Associate Professor

Department of Otorhinolaryngology, Nicolae Testemitsanu State University of Medicine and Pharmacy
Chisinau, the Republic of Moldova

Corresponding author: svetricean@yahoo.com. Received August 27, 2018; accepted October 01, 2018

Abstract

Background: Over the past decades, there have been a multitude of reports on the effectiveness of various techniques for the reconstruction and obliteration of the mastoid cavity.

Material and methods: A comparative study on the meatotympanoplasty effectiveness using the auto osteomatrix forte autograft associated with temporal fascia and mastoid obliteration with pediculated musculoperiosteal flap in 58 patients after total tympanomastoidectomy and 59 patients after revision surgery of the eardrum cavity. The patient batches were similar according to age, gender and living environment.

Results: 12 months postoperatively, in all patients of both study groups was determined: significant decrease of complaints, ameliorated anatomical outcomes (small, clean and dry eardrum cavity), eradication of the eardrum cavity pathology, improvement of the auditory functional results (statistically significant increase in the perception of voice on whispering and speech, airway and bone conduction), improvement of the vestibular function and life quality.

Conclusions: Meatotympanoplasty with the use of the auto osteomatrix forte autograft when associated with the temporal fascia and the mastoid dislocation with pediculated musculoperiosteal flap is a feasible and safe technique for pathology eradication involving the eardrum cavity. The use of the autologous bone for reconstruction is effective for the stability of the external auditory canal and for the tympanic membrane. It preserves and / or restores hearing, and has a lot of advantages: is immediately available in primary and revision surgeries, is economical, does not cause inflammation processes in the body, contributes to the growth of the new bone, reduces the risk of infection, resorption and subsequent degradation and improves life quality.

Key words: mastoidectomy, reconstruction, obliteration, auto osteomatrix forte autograft.

Introduction

The objectives of mastoidectomy in chronic suppurative otitis media with cholesteatoma are: eradication of the disease, obtaining dry ears, prevention of recurrent pathology and the possibility to restore the affected sonic transmission mechanism. Canal wall down mastoidectomy (CWD) is one of the commonly used surgical techniques for the effective eradication of the middle ear disease. This approach is aggressive with the removal of affected anatomical structures. Thus, it leads to an open cavity formation, in this way changing middle ear anatomy and physiology. Although most patients experience postoperative minor short-term problems, there are a considerable number of patients with chronic disorders associated with the eardrum cavity persistence [1].

Otorrhea and recurrent infections are the commonest causes of frequent complaints of patients with mastoid cavities. Other frequent complaints include water intolerance with the development of infections, frequent need for otomicroscopic treatment and removal of pathological secretions, dizziness caused by exposure to water or air, barometric induced dizziness, and hearing loss with the inability of wearing the traditional hearing aids [1].

Reconstruction techniques of the posterior wall of the external auditory canal (EAC) and the methods of mastoid cavity obliteration appeared as an effort to avoid the disadvantages of CWD mastoidectomy techniques. Reconstruction procedures of the posterior wall of the external auditory canal (EAC), mastoid cavity obliteration and ossiculoplasty may be performed primarily during the same procedure

along with CWD mastoidectomy or as a secondary procedure for revision of the mastoid cavity with chronic otorrhea and hypoacusis [1].

So far, the otosurgeons do not have a unanimous opinion on the optimal material used to restore ear structures after the aggressive surgery. Both organic and inorganic materials currently used in reconstruction surgery, along with indisputable advantages, present serious disadvantages. More and more specialists tend to use materials obtained from bone and autologous cartilage tissue which possess osteoinductive properties [1].

Over the last few decades, there have been a large number of reports on the effectiveness of a variety of mastoid cavity techniques. The commonest applied and popular techniques are local flaps (muscle, periosteum or fascia), free autologous grafts (bone, cartilage, fat, fascia) or alloplastic grafts (hydroxyapatite, silicon, synthetic bones) [1].

The study aim is to evaluate the efficacy of meatotympanoplasty with the use of the auto osteomatrix forte graft (AOMF) associated with temporal fascia and mastoid obliteration with pediculated musculoperiosteal flap in patients after total tympanomastoid dissection (ETMT) in comparison to patients after revision surgery of the eardrum cavity.

Material and methods

To determine the effectiveness of the use of autogenous bone grafts with AOMF osteoinductive properties in reconstruction surgery after ETMT the prospective cohort study was conducted which included 2 batches of patients:

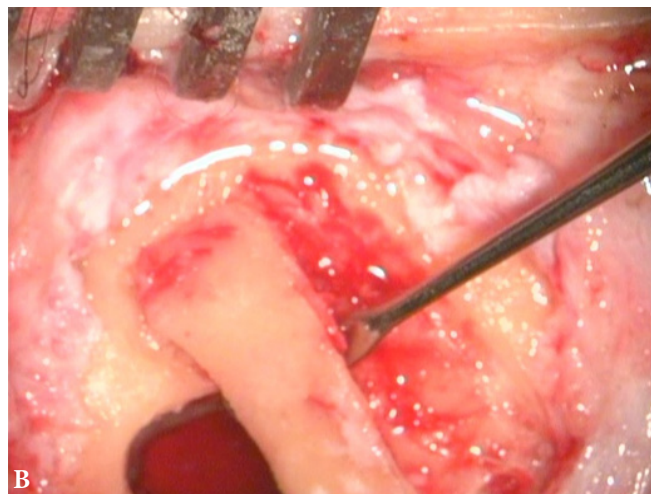
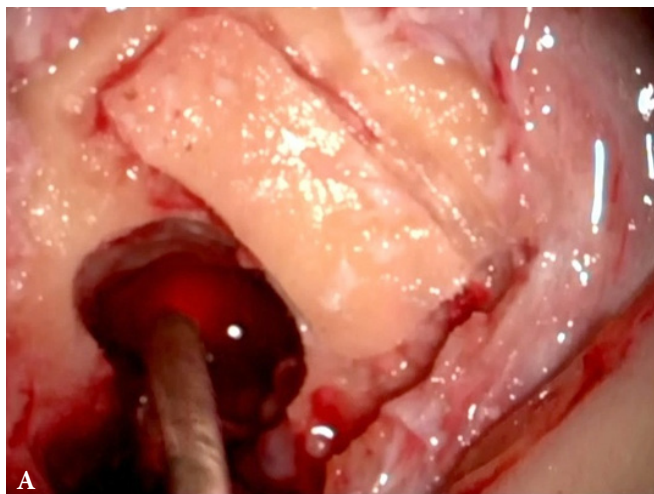


Fig. 1. A, B – sampling of the fragment from the cortical layer of mastoid apophysis.

- Group of patients with ETMT and reconstruction by means of the elaborated method included 58 patients: 28 (48.3%) women and 30 (51.7%) men with mean age of 41.83 ± 1.2 years (from 24 up to 60 years old) – the baseline lot (LB);
- Group of patients with revision surgery of the evoidation cavity and reconstruction by means of the elaborated method constituted 59 patients: 30 (50.8%) women and 29 (49.2%) men with mean age of 40.44 ± 1.3 years (from 18 up to 61 years old) – control group (LM).

From the study were excluded: patients with malignant ear cancer, patients with congenital disorders, patients that were not fully investigated preoperatively or postoperatively according to the study protocol, patients that did not attend the medical check-ups on the schedule, patients that refused to participate in the study or abandoned it.

All patients were treated at the Department of Otorhinolaryngology of the Republican Clinical Hospital in Chişinau, during 2005-2014.

We applied meatotympanoplasty with the use of auto osteomatrix forte graft associated with temporal fascia and mastoid obstruction with pediculated musculoperiosteal flap. The first variant is used in patients that were not previously operated by OMCS. Firstly the mastoid plane is opened within the limits of the Chipault triangle. The rectangular bone fragment with the dimensions of 1.5x2.5 cm and the thickness of 1 cm (fig. 1 A, B) is cut from the cortical layer. After that typical ETMT is performed (fig. 2). When EAC postero-superior wall is removed, 2 fine crests are cut into their upper and lower sides. EAC plastic surgery of the skin is not performed. The postoperative cavity is treated with Mirocel or with mesh gauzes with antibacterial ointment. The plaque remains opened during 3-5 days (time required to prepare the OMF autograft from the bone fragment of the cortical layer, extemporary prepared). Daily, on the postoperative cavity are performed measures for rehabilitation and removal of pathological secretions with microscopic revision. For this are applied dressings, swab-

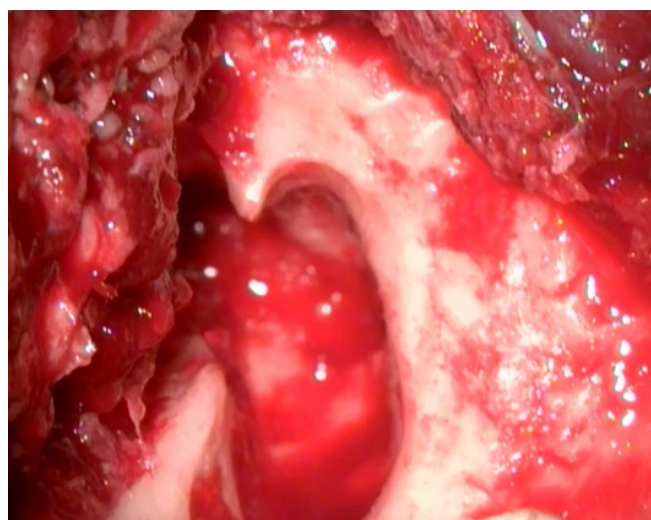


Fig. 2. Evoidation cavity.
Mastoid cavity after radical mastoidectomy.

bing with Mirocel, or treatment with mesh gauzes with antibacterial ointment. The reconstruction stage is performed on the 4th up to 6th day (depending on the preparation of the OMF autograft). The prepared autografts have sufficient elasticity and strength to provide the shape and position required to model the EAC posterior wall. In addition, it offers the possibility of bonding the fascicular graft to reconstruct the eardrum. On the margins of OMF grafts, longitudinal incisions of 1.5-2 mm are made. After attaching the fascicular graft, the EAC postero-superior wall is reconstructed. The bonding of OMF grafts is achieved by using the upper and lower ridges prepared during the rehabilitation stage (fig. 3). In the mastoid cavity is introduced a 5 mm diameter policlorvinil perforated drainage tube and the mastoid cavity is obliterated by placing the pediculated musculoperiosteal flap taken from the retroauricular area (fig. 4). EAC is swabbed with Mirocel or treated with mesh gauzes with antibacterial ointment. Plaque is sutured layer by layer.

The second variant is used in patients with ETMT antecedents and with MUO. Until the revision of the evoidation

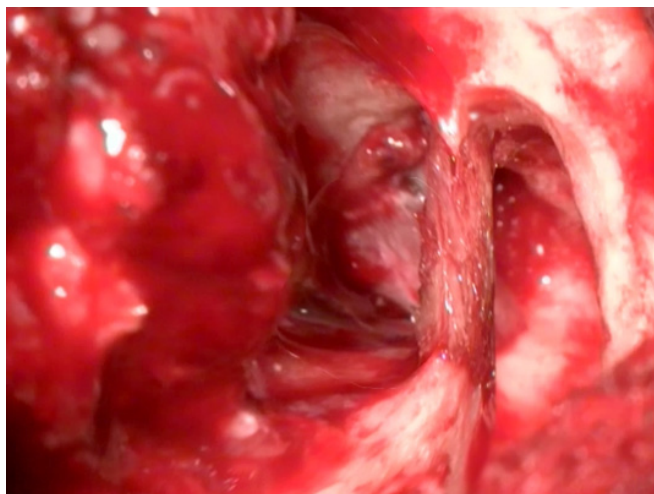


Fig. 3. Reconstruction of the postero-superior wall of the external auditory canal with the osteomatrix forte graft.

cavity, a bone fragment from the cortical layer is cut to prepare the OMF autograft. After revision, the mastoid cavity is swabbed with Mirocel or treated with mesh gauzes with antibacterial ointment. The plaque remains opened during 3-5 days (the time required to prepare the OMF autograft). Daily, on the postoperative cavity are performed procedures for rehabilitation and removal of pathological secretions with microscopic revision. For this are applied dressings, swabbing with Mirocel, or treatment with mesh gauzes with antibacterial ointment. The reconstruction stage is performed on 4th up to 6th day (depending on the preparation of the OMF autograft). The bonding of the OMF graft and mastoid obliteration is similar to the first variant. Plaque is sutured layer by layer. EAC is treated swabbed with Mirocel or mesh gauzes with antibacterial ointment.

To achieve the study objectives, patients underwent a complex clinical and paraclinical examination program according to pre-established research designs (at the onset of the study and in dynamics at 1, 6, and 12 months postoperatively). In the study were applied the following methods of investigation: clinical, functional, instrumental, imagistic, and microbiologic.

Patient examination protocol included: (1) history of the disease taking into consideration the duration and severity of the symptoms (otorrhea, hearing loss, tinnitus, dizziness, otalgia, cephalgia) and previous surgical procedures, (2) otomicroscopic and /or otoendoscopic examination, (3) complete audiological evaluation (audiometry, instrumental audiometry with diapason, Liminal pure-tone audiometry, acoustic impedancemetry) (4), vestibular function test, (5) temporal bone imaging examination by high resolution computerized tomography, life quality assessment by applying the Chronic Ear Survey.

Primary data processing was performed with the help of "Statistical Package for the Social Sciences" program, version 20.0 for Windows (SPSS, Inc., Chicago, IL, 2011) using descriptive and inferential statistics. The X^2 method was used with Yates correlation or Fisher's exact method to compare discrete variables, unifactorial variance analysis

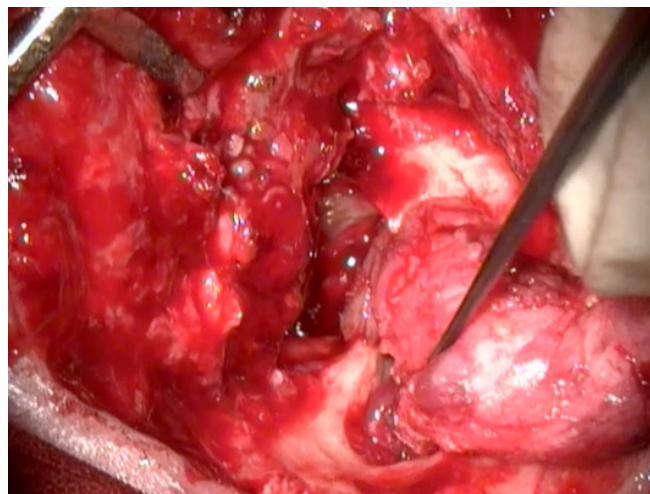


Fig. 4. Mastoid obliteration with pediculated musculo-periosteal flap.

with the application of post-hoc analysis test, the difference between the mean values in the study batches, correlation analysis to determine the relationship between variables, power and direction.

Results

Comparative examination of patients from LB and LM groups did not reveal significant statistic differences according to: age ($40.44 \pm 1,3$ years and $41.83 \pm 1,2$ years, respectively; $p > 0.05$), gender (50.8% and 48.3% women, $p > 0,05$; 49.2% and 51.7% men, $p > 0.05$), living environment (52.5% and 56.9% rural area, $p > 0.05$; 47.5% and 43.1% urban area, $p > 0.05$), rate of unengaged people (8.5% and 13.8%, respectively; $p > 0.05$), smoking (37.3% and 46.6%, respectively; $p > 0.05$) and alcohol consumption (28.8% and 39.7%, respectively; $p > 0.05$).

During the preoperative examination, patients from LB group frequently complained of headaches (94.8% and 78.0%, $p < 0.05$), otalgia (94.8% and 78.0%, $p < 0.05$) and tinnitus, 1% and 90.8%, $p < 0.01$). Patients' general state was similar in both study groups. General state of moderate severity constituted 71.2% in LM patients and 81.0% in LB patients ($p > 0.05$).

Hearing test revealed reduced and similar incidence of EAC narrowing in patients from both study groups: 8.5% of LM patients and 6.9% of LB patients ($p > 0.05$). Although pathological eliminations were identified in all patients in both groups, in LB patients were revealed frequent statistically significant pathological eliminations with fetid odor (49.2% and 100.0%, $p < 0.001$), and in LM – odorless pathological eliminations without fetid odor (50.8% and 0%, $p < 0.001$).

During the objective exam, the postero-superior wall was absent statistically significantly more frequently in LM patients (100.0% and 0%, $p < 0.001$) was normal (0% and 89.7%, $p < 0.001$) and protruded (0% 10.3%, $p < 0.05$) more frequently in LB. the evoidation cavity was recorded only in LM patients. The tympanic membrane (TM) was presented

with perforation and localization in par sensing and pars flaccida in all patients from both study groups.

Granulations were present in all patients from both study groups. Polyps (22.0% and 43.1%, $p < 0.05$) and cholesteatoma (39.0% and 100.0%, $p < 0.001$) presented statistically significant incidence in LB patients.

Hearing test revealed: mean value of voice perception on whistling (1.95 ± 0.08 m and 1.18 ± 0.04 m, $p < 0.001$), mean voice perception during speech ($4.24 \pm 0,09$ m and 3.37 ± 0.07 m, $p < 0.001$), an average decrease of air conduction duration ($49.41 \pm 1.1\%$ and $34.14 \pm 0.8\%$, $p < 0.001$) and an average decrease in bone conduction ($84.41 \pm 1.0\%$ and $60.69 \pm 0.6\%$, $p < 0.001$) significantly higher in LM.

Thus, during the preoperative examination, patients from LB group presented more statistically significant incidence of otorrhea with fetid odor, polyps and cholesteatoma. Patients from LM group presented pathological elimination without fetid odor, and statistically significantly higher audiometry tone values.

One month postoperatively, the majority of complaints in patients from both study groups were significantly reduced. Although, all patients complained of hearing loss in both study groups, patients from LB group complained of more pronounced statistically significant hearing loss (86.4% and 98.3%, $p < 0.05$), and patients from LM group complained more frequently of moderate hearing loss (13,6% and 1.7%, $p < 0.05$). The general condition was similar in patients from both study groups.

Hearing test revealed statistically significantly higher incidence of moderate otorrhea (22.0% and 54.4%, $p < 0.001$) and mild otorrhea (67.8% and 40.4%, $p < 0.01$) was more rare in LB patients. The objective examination revealed normal postero-superior wall incidence. Perforated and absent integral MT was similar. Cholesteatoma, granulations and adhesions were not found in patients from both study groups. The eudation cavity was closed without pathologies in all patients from both study groups.

Hearing test revealed: mean value of voice perception on whistling ($1.96 \pm 0,09$ m and $2.88 \pm 0,05$ m, $p < 0.001$), average voice perception during speech ($4.34 \pm 0,1$ m and 4.98 ± 0.02 m, $p < 0.001$), mean loss of air conduction duration ($44.58 \pm 1.7\%$ and $54.83 \pm 0.7\%$, $p < 0.001$) and mean loss of osseous conduction duration ($77.29 \pm 1.5\%$ and $88.97 \pm 1.5\%$, $p < 0.001$) presented higher statistically significant values in LB patients.

Thus, 1 month postoperatively, patients from LM group complained more frequently of moderate hearing loss and patients in LB group – of pronounced hearing loss. The objective examination revealed more frequent moderate forms of otorrhea, and otorrhea in insignificant amount was statistically significantly less rare in LB patients. Improvement of hearing function presented higher statistically significant values in patients from LB group.

Six months postoperatively, the complaints frequency continued to decline. The complaints frequency and patients' general condition were similar in both study groups.

The general condition of the majority of patients was satisfactory.

The hearing test did not reveal statistically significant differences in the incidence and characteristics of pathological eliminations. The eudation cavity was closed without pathologies in all patients from both study groups.

Hearing test revealed: average voice perception on whispering ($2.42 \pm 0,1$ m and 3.45 ± 0.09 m, $p < 0.001$), average voice perception during speech ($4.60 \pm 0,1$ m and 5.95 ± 0.04 m, $p < 0.001$), mean value of air conduction loss ($58.47 \pm 0.6\%$ and $65.69 \pm 1.5\%$, $p < 0.001$) and the mean value of osseous conduction loss ($87.29 \pm 0.9\%$ and $92.76 \pm 0.3\%$, $p < 0.001$) were statistically significantly higher in patients from LB group.

Thus, 6 months postoperatively, the complaints frequency continued to reduce, and their incidence was the same in both study groups. The objective examination did not reveal statistically significant differences in the frequency and characteristics of pathological eliminations, postero-superior wall, MT, and pathology of the cavity was not found in patients in both study groups. The hearing test showed statistically significantly higher improvement in LB patients.

Although 12 months postoperatively, hypoacusis was reported in all patients from both subgroups of study, insignificant hearing loss was more common in patients from LB group (11.9% and 41.4%, $p < 0.001$), acute hypoacusis (22.0% and 0%, $p < 0.001$) – was statistically significantly more frequent in LM patients. The general condition was satisfactory in the majority of patients from both study groups.

The hearing test did not reveal a narrowing of the EAC and did not reveal statistically significant differences in the incidence and characteristics of the otorrhea and the MT state. The condition of the cavity was shown to be closed and without pathological changes in all patients from both study groups.

The hearing test revealed the average voice perception on whispering (3.32 ± 0.1 m and 3.74 ± 0.09 m, $p < 0.01$) and the mean value of air conduction loss ($62.71 \pm 1.7\%$ and $67.24 \pm 1.2\%$, $p < 0.05$) were statistically significantly higher in LB patients.

Thus, 12 months postoperatively, hearing loss was present in all patients in both subgroups of study. Insignificant hearing loss was more common in LB patients, and significant hearing loss was statistically significantly more frequent in LM patients. The mean value of voice perception on whispering and the mean value of air conduction loss were statistically significantly higher in LB group.

Discussion

The management of open mastoid cavity has two options: conservative and revision surgery with correction (surgery for elimination of mastoidectomy adverse effects) [4].

The procedure for the revision surgery of the eudation cavity includes the complete elimination of the disease and methods for the prevention of recurrent diseases. It also includes the reconstruction of EAC posterior wall

with meatoplasty, mastoid obliteration procedures, reconstruction of the tympanic membrane (tympanoplasty), reconstruction of the ossicular chain (ossiculoplasty), and meatoplasty [3].

Mercke suggested an innovative procedure in which the EAC posterior wall is temporarily removed, in order to avoid the disadvantages and combine certain features of CWD mastoidectomy. This procedure facilitated the complete removal of the impairment. Subsequently, it is followed by the reconstruction using autologous grafts (bone, cartilage) or alloplastic grafts (HA cement, ionomeric glass cement, titanium plates). This technique, called the canal wall reconstruction, with a single step for the removal of cholesteatoma and reconstruction of the EAC wall, had long acceptable results [5, 6].

Many techniques and materials for grafting (autologous, allogeneic, heterologous or synthetic biocompatible) have been used in the reconstruction of the posterior wall of EAC and mastoid obliteration, but none of these proved to be ideal for obliteration. Patient's tissues are considered to be selective materials in reconstruction [2, 7, 8, 9].

In our study, we compared the efficacy of meatotympanoplasty with the use of AOMF autograft associated with temporal fascia and mastoid dislocation with pediculated musculoperiosteal flap in 58 patients after ETMT and in 59 patients after revision surgery of the eardrum cavity. The patient batches were similar depending on age, gender, living environment, rate of unemployed people, smoking and alcohol consumption.

Overall, the dynamic evaluation found more significant improvement in LB patients in comparison to LM patients. These results coincide with the specialized literature data. Kronenberg and co-authors reported the results of a retrospective case study of 49 consecutive patients (31 children and 18 adults) with the reconstruction of the EAC posterior wall with autologous bone paste and obliteration of the mastoid cavity with tympanomeatal flap. After an average 28 months follow-up, 30 primary operated patients achieved impermeable ears in 85.7% of cases, dry ears in 90% of cases, intact MT in 93.3% of cases, and recurrent cholesteatoma in 10.0% of cases, compared to 64.7%, 73.7%, 73.7% and 15.8%, respectively, in 19 patients with secondary intervention for the revision of the cavity [11].

A significant complaints reduction (headache, otalgia, nausea, dizziness, and general weakness) was determined in patients from both study groups, 1 month postoperatively. Although all patients had hearing loss in both groups, there was statistically significant increase of mild and moderate hypoacusis and statistically significant reduction of acute hypoacusis. However, the modification rate was higher in patients from LB group. Tinnitus and otorrhea were significantly statistically reduced after 6 months postoperatively. Although at the objective structured primary examination the general condition was more severe, the improvement rate was higher in LB patients.

The hearing test revealed, in patients from both study groups, similar incidence of: narrowed EAC correction,

otorrhea reduction, disappearance of adhesions, granulations and cholesteatoma, 1 month postoperatively. The examination of the eardrum cavity found, 1 month postoperatively, a closed cavity in all patients from both study groups. 1 month postoperatively almost all pathologies of eardrum cavity were eradicated, in all patients from both study groups. Exception presented desquamation of the epidermis and mucositis that significantly statistically decreased 1 month and 6 months postoperatively and completely disappeared after 12 months postoperatively in patients from LM group.

Patients from both study groups showed a statistically significant increase of voice perception on whistling and speech and duration of airway and bone conductions. But the growth rate was also higher in LB group.

In both study groups the tuning fork samples revealed mixed hypoacusis in all patients. Vestibular apparatus examination revealed a statistically significant improvement. Subjective examination using the Likert - CES scale found a statistically significant life quality improvement. Statistically significantly increased the subscale score of activity limitation / restriction, symptom subscale score, medical resource utilization subscale score, and total score. However, the rate of life quality improvement was higher in LM patients.

Few authors studied the benefits of mastoid obliteration with the reconstruction of the external auditory bone canal, in particular the improvement of life quality after this procedure. A recent observational retrospective study was conducted to determine whether the obliteration of the mastoid cavity with autologous cranial bone graft after CWD mastoidectomy improves the life quality. Primary obliteration was performed in 46 patients and secondary obliteration in 12 patients. The Glasgow Benefit Inventory questionnaire was used to estimate the life quality. The overall score and subscale scores improved significantly. These results were similar to our study data. The authors concluded that the mastoid cavity obliteration with the reconstruction of the EAC posterior wall with an autologous cranial graft provides a significant benefit to life quality for both patients after primary and secondary interventions [14].

Thus, meatotympanoplasty with the use of auto osteo-matrix forte autograft associated with temporal fascia and pediculated musculoperiosteal flap is a feasible and safe technique for eradicating the pathology of the middle ear and mastoid cavity. Our preliminary results indicate good overall results for the stability of the external auditory canal and MT, the preservation and / or improvement of hearing and cholesteatoma.

Similar results have been reported in many publications in the specialized literature. Mokbel and Khafagy presented a prospective case study of 100 adult patients (55 males and 45 females) aged between 17-55 years with chronic unilateral otitis media with or without cholesteatoma, without mastoidectomy antecedents, with 12 months minimum follow-up period. The authors carried out CWD mastoidectomy, extensive meatoplasty, anterior and inferi-

or canalplasty, tympanoplasty, obliteration with bone paste covered by musculoperiosteal flap based on three pedicles (anterior, lower and upper). The flap and the exposed bone were covered with temporal fascia and skin grafts to accelerate epithelialization and to obtain a dry cavity. The reconstruction of the osseous chain was not performed. Twelve months postoperatively, 78% of patients had a completely dry cavity, 16% had intermittent otorrhea and 6%- persistent otorrhea [10].

Mobashir and co-authors reported the results of the study performed on 31 patients (24 men and 7 women) with mean age 26.7 years (15 to 36 years old) with primary acquired cholesteatoma. The postoperative follow-up constituted 15.3 months. The surgical technique included complete cortical mastoidectomy, extended posterior tympanometry, removal of the posterior bone wall of the EAC, dissection and eradication of cholesteatoma, reposition of the EAC wall segment in the anatomical area, ossiculoplasty (in 26 patients), reconstruction of the atical lateral wall with autologous bone paste. Postoperatively, all patients presented a completely healed outer ear canal of almost normal size, shape and contour. The posterior wall was stable and the bone paste turned into a consistent newbone with the texture and integrity of a normal bone canal. None of the patients showed residual perforation of MT, otorrhea, myringitis or prosthesis extrusion [6].

Ghiasi, in a prospective longitudinal study with 28 months average follow-up, evaluated 56 ears of 48 patients with chronic cholecystectomy. After CWD mastoidectomy, mixed obliteration of mastoid cavity with autologous bone paste was performed. The bone graft was covered with a posterior section of the temporal fascia and Pavla flap. Seventeen (30%) ears were treated by revision surgery. Approximately 82% of the ears had a very small, dry, healthy mastoid cavity, 13% of ears – occasional otorrhea, 5% of ears – granulation tissue, 12.5% of ears – residual cholesteatoma and 7% of ears – wound infection [13].

Ramsey and co-authors presented a retrospective clinical study of 60 consecutive surgical interventions at 59 patients with active OMC aged between 4-84 years (mean age of 39 years old), including 53 (88%) ears with cholesteatoma and 7 (12%) ears with granulation tissue without cholesteatoma. All patients underwent CWD mastoidectomy with simultaneous thymoplasty. In order to obliterate the mastoid cavity, the lower pediculated postauricular periosteal-pericranial flap was used in combination with autologous bone paste. Anterior and lower canalplasty and extended meatoplasty were performed. The follow-up period constituted of 12-80 months (on average 32 months). Forty (67%) of the procedures were primary and 20 (33%) were revision procedures. During all procedures, 54 (90%) patients passed successfully the infection control, 6 (10%) patients had repeated otorrhea. There were no cases of residual or recurrent cholesteatoma [15].

Roberson and co-authors reviewed 62 ears of 57 patients (25 women and 32 males) after CWD mastoidectomy or revision of the problematic mastoid cavity. At the same

time, 33 patients underwent secondary surgery for ossicular reconstruction of 36 ears. Patients were subjected to mastoid and epithelium obliteration with autogenous cranial bone paste reconstruction, covered with temporal fascia. Transplantation of autogenous cranial bones led to osteoneogenesis causing complete obliteration of epitympanic and mastoid areas with the maintenance of the mesotympanic space. Evaluation of long-term outcomes (mean period 18.5 months) found: complete bone obliteration in 95.2% of cases, complete resolution of symptoms in 90% of cases, significant reduction in the frequency and severity of symptoms in 10% of cases, and assessment of air-bone gap ≤ 20 dB in 60% of cases. In 95% of patients Eustachio tube functioned properly. None of the patients required a revision surgery [7].

Beutner and co-authors presented a number of cases with 18 patients with the mean age – 46.3-years. These patients previously underwent CWD mastoidectomy and revision CWD mastoidectomy by obliteration with autologous bone paste, covered with cartilage plates, meatoplasty and MT reconstruction with thin cartilage slices. The average follow-up period was 6 years. None of the patients had residual or recurrent cholesteatoma, did not report symptoms similar to preoperative symptoms (otorrhea, dizziness), and all patients had dry ears with complete epithelialization [12].

Thus, in order to overcome the problem of oversized mastoid cavity, reconstruction of the EAC posterior wall with immediate mastoid obliteration or revision intervention is performed. Several autologous materials (cartilage, bone paste, local pediculated flaps of soft tissue) or synthetic biocompatible (bone cement, HA granules, bioactive glass) have been used to reduce the size of the cavity. The use of the autologous bone contributes to the creation of the new bone, reduces the risk of infection, resorption and subsequent degradation. It contributes to bone graft survival and a lower risk of subsequent repair of the reconstruction compared to heterologous materials. The use of the autologous cortical bone to reconstruct the posterior wall of the EAC has advantages: it is autologous, immediately available and economical, does not develop an inflammatory reaction to a foreign body and improves the life quality.

Conclusions

1. Dynamic assessment found a more significant improvement of complaints and general condition of patients after ETMT and reconstruction by the elaborated method, in comparison to patients with revision surgery of the evadation and reconstruction cavity by the elaborated method.

2. Improvement of anatomical outcomes (low, clean and dry cavity) and functional outcomes (auditory function, vestibular function and life quality) was statistically significantly earlier, more stable and with higher rate in patients from the control group.

3. Use of the autologous bone for the reconstruction of the EAC posterior wall has advantages. It is an autologist;

is immediately available in both primary surgery and revision surgery; is economical; does not develop inflammatory response to the body; contributes to new bone creation; reduces the risk of infections, resorption and subsequent degradation; contributes to the survival of the graft, restores the almost normal anatomy of EAC; improves the life quality.

References

1. Alves R, Cabral Junior F, Fonseca A, et al. Mastoid obliteration with autologous bone in mastoidectomy canal wall down surgery: a literature overview. *Int Arch Otorhinolaryngol.* 2016;20(1):76-83.
2. Virk J, Patel N. Primary mastoid reconstruction with Sofradex®-soaked autologous bone pâté: is there a sensorineural hearing effect? *Clin Otolaryngol.* 2017;42(3):758-61.
3. Nadol JB. Revision mastoidectomy. *Otolaryngol Clin North Am.* 2006;39(4):723-40.
4. Black B. Mastoidectomy elimination. *Laryngoscope.* 1995;105(12 Pt 2 Suppl 76):1-30.
5. Roux A, Bakhos D, Lescanne E, et al. Canal wall reconstruction in cholesteatoma surgeries: rate of residual. *Eur Arch Otorhinolaryngol.* 2015;272(10):2791-7.
6. Mobashir MK, Basha WM, Mohamed AE, et al. Posterior canal wall reposition for management of cholesteatoma: Technique and results. *Auris Nasus Larynx.* 2018;45(2):254-60.
7. Roberson JB, Mason TP, Stidham KR. Mastoid obliteration: autogenous cranial bone pate reconstruction. *Otol Neurotol.* 2003;24(2):132-40.
8. Leatherman BD, Dornhoffer JL. The use of demineralized bone matrix for mastoid cavity obliteration. *Otol Neurotol.* 2004;25(1):22-6.
9. Sayed RH. One-stage reconstruction in management of extensive cholesteatoma. *IFOS Int Congr Series.* 2003;1240:121-31.
10. Mokbel KM, Khafagy YW. Single flap with three pedicles, bone paté and split-thickness skin graft for immediate mastoid obliteration after canal wall down mastoidectomy. *Eur Arch Otorhinolaryngol.* 2012;269(9):2037-41.
11. Kronenberg J, Shapira Y, Migirov L. Mastoidectomy reconstruction of the posterior wall and obliteration (MAPRO): preliminary results. *Acta Otolaryngol.* 2012;132(4):400-3.
12. Beutner D, Helmstaedter V, Stumpf R, et al. Impact of partial mastoid obliteration on caloric vestibular function in canal wall down mastoidectomy. *Otol Neurotol.* 2010;31(9):1399-403.
13. Ghiasi S. Mastoid cavity obliteration with combined palva flap and bone pâté. *Iran J Otorhinol.* 2015;27(78):23-8.
14. Kurien G, Greeff K, Gooma N, et al. Mastoidectomy and mastoid obliteration with autologous bone graft: a quality of life study. *J Otolaryngol Head Neck Surg.* 2013;42:49.
15. Ramsey MJ, Merchant SN, McKenna MJ. Postauricular periosteal-pericranial flap for mastoid obliteration and canal wall down tympanomastoidectomy. *Otol Neurotol.* 2004;25(6):873-8.

