

Diagnosis and modern medical-surgical tactics in treatment of biliary atresia in children

^{*1,2}Gheorghe Gincu, ^{1,2,3}Eva Gudumac, ¹Nina Braniște, ¹Ina Revenco, ¹Doina Haidarli, ¹Oleg Samciuc

¹Natalia Gheorghiu Department of Pediatric Surgery, Orthopedics and Anesthesiology

²Natalia Gheorghiu Scientific Center of Pediatric Surgery, ³Laboratory of Surgical Infections in Children

Nicolae Testemitanu State University of Medicine and Pharmacy, Chisinau, the Republic of Moldova

Authors' ORCID iDs, academic degrees and contributions are available at the end of the article

*Corresponding author: gheorghe.gincu@usmf.md

Manuscript received August 10, 2020; revised manuscript September 25, 2020; published online October 05, 2020

Abstract

Background: Biliary atresia (BA) is a serious pediatric condition that tends to progress to cirrhosis, liver failure, and death within a short time. It is the result of a continuous inflammatory, sclerosing, destructive process in the biliary tract and the most common indication for liver transplantation.

Material and methods: The study included 46 patients up to 1 year of age hospitalized with cholestasis syndrome in IMSP IM and C, during the years 2014-2019. The basic methods in the diagnosis of BA were the biochemical examination, FGDS, USG doppler duplex color of the biliary system before and after the meal intake, MRI with cholangiography, dynamic hepatobiliary scintigraphy.

Results: Following the analysis of clinical and paraclinical results, surgical pathology was excluded in 25 patients, the diagnosis of BA was established in 11 cases. 6 patients with BA underwent Kasai surgical intervention, a primary liver transplant was performed in 3 cases, and 2 patients died before the surgery.

Conclusions: Portoenteroanastomosis (Kasai operation) performed as early as possible (up to 60 days postnatal) considerably increases life expectancy. The embryonic form of BA is a severe condition that is indicated for the initial liver transplant. The prognosis of untreated biliary atresia is unfavorable, leading to the death of most children in the first 2 years of life due to liver failure. In decompensated late-diagnosed cases, liver transplantation remains the only treatment option.

Key words: biliary atresia, Kasai, transplant, portoenteroanastomosis.

Cite this article

Gincu G, Gudumac E, Braniște N, Revenco I, Haidarli D, Samciuc O. Diagnosis and modern medical-surgical tactics in the treatment of biliary atresia in children. *Mold Med J.* 2020;63(6):25-32. doi: 10.5281/zenodo.4028373.

Introduction

Biliary atresia (BA) is defined as a progressive inflammatory, fibrotic, destructive-sclerosing process, continuous, which is complicated by endoluminal obliteration of the bile ducts both intra and extrahepatic [1]. Complicated with destructive cholangitis, it partially or totally affects the biliary excretory system, and leads to continuous fibrosis of the biliary system, resulting in numerical reduction of the intrahepatic bile ducts with stenosis of the entire biliary excretory system, ending with biliary cirrhosis [1]. The pathology is determined by a pathogenetic, multifactorial complex that initiates inflammation, fibrosis, sclerosis and bile duct obliteration. Based on the etiopathogenetic evolution, BA is not the agenesis of the biliary system, but the continuation of the destructive processes conceived in both, embryonic and fetal periods [1, 2].

Despite the detailed etiopathogenetic argumentation, some authors currently support the theory of biliary atresia as an acquired notion. The justification for this theory is supported by statistical results that indicate that 35-40% of patients have normal meconium stool at birth, and more than 50% have colic stools at birth, and in the short postna-

tal period, being met periodicity of colic and acholic stools [1, 2].

The diagnostic differentiation in a short time creates difficulties and imposes an interdisciplinary activity in order to exclude neonatal hepatitis, metabolic, hematological, genetic disorders, etc., which can be easily confused with BA. The surgery on the background of the above-mentioned pathologies, considerably aggravates the child's condition and has an unfavorable prognosis [1, 3].

Histologically, it is demonstrated that in most cases the intrahepatic bile ducts are numerically diminished and the lack of the lumen is appreciated with the transformation of the bile ducts into connective tissue cords. In the specialized literature are described cases when in the fibrous cord the premature lumen of the bile ducts is appreciated. BA may be present as an isolated abnormality or in combination with other birth defects [1]. Fibrosis obliteration of the biliary system is directly proportional to the patient's age, this finding raise major problems in the diagnostic differentiation from a histological point of view, with neonatal hepatitis. Multiple classifications based on the anatomy of these fibrous biliary ducts have been carried out. It was found that most often the extrahepatic ductal system is obliterated, and

in 20% of cases the gallbladder, cystic duct, choledochus remain permeable. Children with biliary atresia are usually born at term with a weight within the norm [1, 3].

Morbidity accounts for 28-30% of all newborns with cholestasis, the incidence being from 1:8000 to 1:18000 live newborns, most often with sporadic occurrence in the absence of a positive family history [4]. In the eastern countries, such as Japan, China, Korea, Vietnam, Laos, etc., the disease is found in about 1:8000 children [5, 6]. The highest incidence was recorded in Taiwan 1:3000. More common in females, the ratio being 1.3:1 [6].

Annually in the USA there are over 400 cases of biliary atresia, mostly extrahepatic, with an incidence of 1:14000. It is found in Europe with an incidence of 1:16000 live births [6]. Annually in the Republic of Moldova 2-3 children are born with biliary atresia having an incidence for the years 2014-2019 of 1:13000. In 2014, in Moldova, according to the statistics of the Republic of Moldova, 5 children were born with biliary atresia, the given frequency being inexplicable.

Material and methods

The clinical study was carried out at *Natalia Gheorghiu* Scientific Center of Pediatric Surgery on a group of 46 patients up to 1 year of age hospitalized with cholestasis syndrome during the years 2014-2019. The basic methods in diagnosing BA were the clinical manifestations, scalocolurometry, biochemical examination, VGDS, USG doppler duplex color of the biliary system before and after the meals, cholangiographic MRI, dynamic hepatobiliary scintigraphy, and liver biopsy.

Results

Following the analysis of clinical and paraclinical results, surgical pathology was excluded in 25 patients, the diagnosis of BA was established in 11 patients, 6 girls and 5 boys (fig. 1, 2).

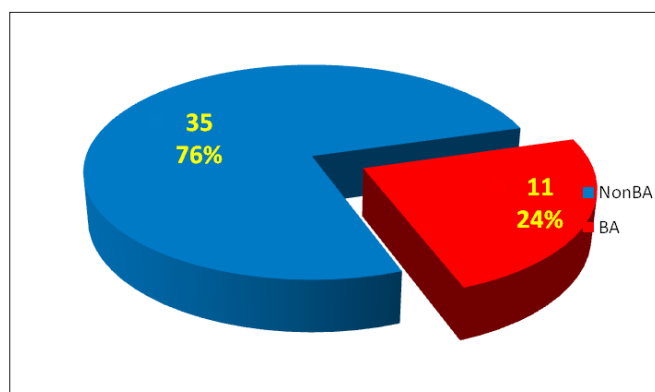


Fig. 1. Incidence of BA for patients with cholestasis

6 patients with BA underwent Kasai surgery, in 3 patients a primary liver transplant was performed, and 2 patients died before surgery.

In eight children there was a meconium stool, in 3 children postnatal there was an acholic stool. Subsequently,

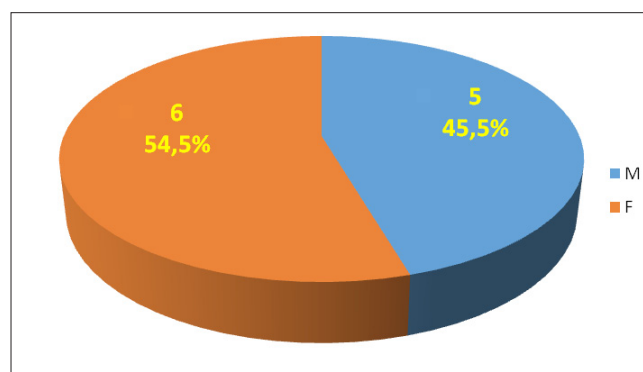


Fig. 2. Gender prevalence in children with BA

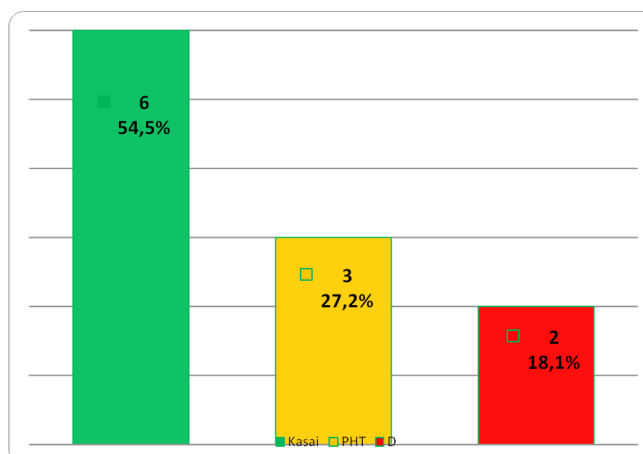


Fig. 3. Type of treatment for patients with BA

all children experienced symptoms no less important than acholic stools and hyperchromic urine. Eight children were born at term, one child at 34 weeks, 2 at 36 weeks. Body weight at birth ranged from 2500 g to 3800 g.

BA was established according to the following results, the primary sign for diagnosis confirmation was prolonged to cholestatic jaundice, persistent in the first weeks of life, being present in 100% of examined patients. Neonatal jaundice was reported in two children (4.3%).

The initial objective examination revealed mild hepatomegaly with dynamic liver enlargement and pronounced splenomegaly, pruritus, coagulopathy and hemorrhagic syndrome manifested by frequent petechiae and bruising. Ascites and pronounced vascular pattern on the abdominal wall was assessed in the late stage of the disease or in a general decompensated state. Palpation of the liver revealed induration with a rounded edge; splenomegaly was assessed in the case of intrahepatic portal hypertension (PH).

Scalocolurometry was performed in all patients for at least 14 days and repeated as needed. Initially, all patients had an acholic stool, in 4 patients there was a change in the yellow color for 2-3 defecations, with subsequent installation of acholic stool. In 3 patients the acholic stool was followed by the presence of black stools, which indicate an association of complications and the presence of coagulopathy.

Special attention was drawn to the laboratory findings

to the fractions of bilirubin, mainly to direct bilirubin, which in cases of BA was considerably increased, showing values from 180-420 $\mu\text{mol/l}$, persistent after conservative treatment, and regressing only after the Kasai successful intervention. It should be noted that the prevalence of direct bilirubin is predominantly characteristic in the early stages of the pathology, whereas in case of hepatocellular involvement the increased direct bilirubin is not so obvious compared to indirect bilirubin. Moreover, sometimes indirect bilirubin may prevail, which requires careful analysis for diagnostic differentiation. In addition to increased bilirubin, elevated levels of transaminases, GGTP, increased alkaline phosphatase, lactate dehydrogenase, cholesterol, amylase, beta-lipoprotein, phospholipids, 5 nucleotidase, and decreased indices of prothrombin, fibrinogen, disorder of the synthesis function of albumin and total proteins with an increased coagulation time were reported.

It is important to mention that in case of BA, the above-mentioned indices show a slight decrease following the infusion treatment, though these do not return to normal values, which is an important fact in the diagnostic differentiation. All patients were also tested for viral liver markers (HBs antigen, anti HBs antigen, HBcor, anti HCV, anti HBV, anti HDV), assessment of antibody levels of IgG, IgM classes to viral damage (papilloma virus, cytomegalovirus, ebstein-bar, rotavirus, type 3 RNA reovirus, human herpes virus type 6, shingles virus), alpha 1 antitrypsin (deficiency of which is indication for liver transplantation). CMV was recorded in 8 patients with BA. No other viral damage was reported.

Pre- and post-feeding abdominal ultrasound investigation was indicated in all patients. The examination was performed during pre-feeding, 4 hours after the last feeding and 40-50 min post-feeding. Gallbladder aplasia was diagnosed in 7 patients and dysfunctional gallbladder with anatomical location and extrahepatic bile ducts with a fibrous band appearance was found in 4 patients. It should be noted that intra- and extra-hepatic bile duct dilation was not recorded in any patient with BA.

Polysplenia was diagnosed in 2 children and congenital heart failure in 3 children. More information on liver parenchyma and the installation of intrahepatic PH was revealed by the doppler ultrasound examination, where 3 patients reported severe changes in the liver parenchyma-biliary cirrhosis with the installation of intrahepatic PH were observed.

Videogastroduodenoscopy (VGDS) was performed to visualize the Vater papilla, describe the duodenal mucosa, assess the bile in the duodenum, as well as to provide a differential diagnosis. The presence of bile in the upper digestive tract was not detected in all patients with BA. It should be mentioned that the duodenal jaundice mucosa can be confused with the presence of bile in the duodenum, which considerably transcends the medical-surgical tactics.

This study did not include the retrograde cholangiopancreatography, being mainly based on USG, MRI and scintigraphy that show a much lower harmful impact. We would like to mention that percutaneous cholangiography is an in-

vasive method and it is not recommended unless dilatations of the biliary tree are present.

Cholangiographic MRI was performed in all children with BA, which allowed the study of both intra- and extra-hepatic bile ducts. The examination performed in 8 children showed obvious changes of the gallbladder, of which in 2 children the intrahepatic location of the aplastic gallbladder was assessed. The virtual reconstruction of the biliary tree completed the previous examinations and played a decisive role in the differentiation of the diagnosis and the appreciation of the medical-surgical tactics. At the same time, we would like to mention that as a result of the investigation we could not assess with certainty the biliary atresia and the degree of parenchymal damage, which indicates the need to establish the diagnosis in the context of correlating to all clinical and paraclinical examinations.

Dynamic liver scintigraphy with Tc-99m isotopes (technetium 99m) was performed in a patient at whom the accumulation of the pharmaceuticals within the liver and the lack of communication of the biliary tract with the duodenum was eloquently visualized. The presence of radio-nuclide in the intestine confirms ductal permeability and excludes biliary atresia. Failure to visualize the tracer in the intestinal lumen more than 3-4 hours after administration, especially with phenobarbital, suggested a biliary obstruction caused by biliary atresia. At the same time it should be mentioned that in premature infants with a body weight of less than 2000 g and on a full parenteral diet, the excretion of the pharmaceutical substances in the duodenum may be absent, and does not allow us to differentiate the diagnosis. It should be mentioned that the dynamic scintigraphy of the liver is superior to contrast examinations but due to a prolonged general anesthesia (3 hours) it complicated the investigation in newborns. To improve radioactive uptake, 5 mg/kg phenobarbital should be administered daily for 5 days prior to scintigraphy.

Transcutaneous hepatic puncture under ultrasound guidance was performed preoperatively in 6 children, in all cases there was a numerical decrease of the bile ducts with structural destruction and sclerosis of the bile duct, and transformation of the bile ducts into connective tissue cords. In persistent jaundice, percutaneous liver biopsy did not allow confirmation of BA, by identifying liver fibrosis with bile duct proliferation, the presence of biliary plugs in the bile ducts in the liver triads; biliary stasis in canals and cells; edema and fibrosis in the hepatic triads; swelling, vacuolation and desquamation of the bile duct epithelium; inflammatory cellular infiltration; gigantocellular transformation of liver cells. The presence of biliary thrombi in the lumen of the interlobular bile ducts or of the primary ducts and the neoductular proliferation in the peripheral portal spaces indicate a certain occurrence of BA, which helped us to make a differential diagnostic.

Following the systematization of clinical, paraclinical and histological findings, the embryonic form of BA was established in 4 children and the perinatal form was found in 7 children (fig. 4).

Two children with embryonic form died during a pre-

transplant, one child was diagnosed with BA syndromatic type (Alagille syndrome), the other 10 children presented a nonsyndromatic type (fig. 5).

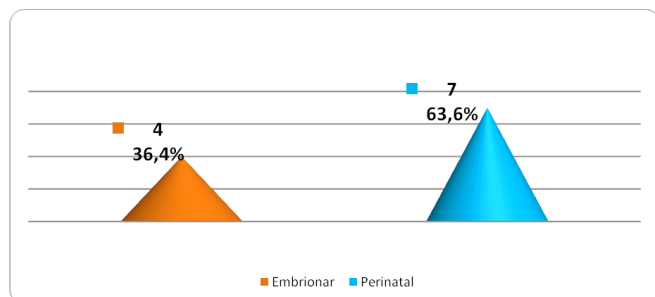


Fig. 4. Etiology prevalence for BA

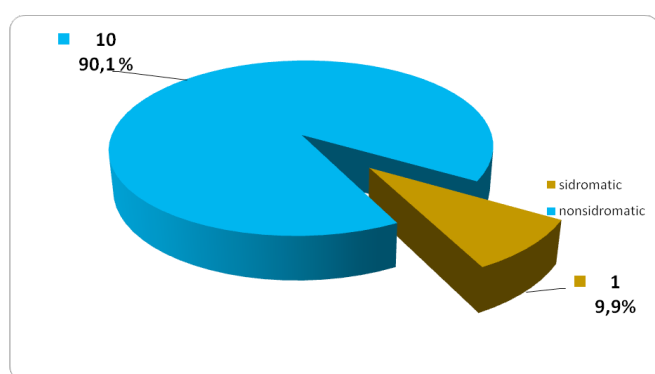


Fig. 5. Types of BA described within the study

An embryo-shaped child was initially subjected to liver transplantation and subsequently died at 6 months after transplant, and an embryonic-shaped child survived after transplant.

Two children were initially diagnosed with intracranial haemorrhage; 1 child was treated conservatively with subsequent Kasai surgery, the other child underwent surgery and initial liver transplantation.

Preoperative management. General preoperative measures included parenteral administration of fat-soluble vitamins A, D, K, E; medium chain triglycerides as a source of fat (Lipofundin, SMOFlipid, etc.), desensitizers to alleviate skin itching. Vitamin K (1-2 mg / Kg / day) was administered 3 days preoperatively. Oral feeding was ceased 12 hours preoperatively. For the preparation of the intestine = oral metronidazole, 10 mg / kg per day in two doses was administered, as well as the evacuation clyster (Carbo erbo glycerol bambini) was applied. The patients were administered broad-spectrum antibiotics preoperatively and intraoperatively.

Treatment. The medical-surgical approach was aimed to restore the bile duct, by implementing two tactics: the Kasai surgical procedure and liver transplantation.

There are currently known over 6 BA classifications .

The medical-surgical tactics was assessed according to the classification of the Japanese Society of Pediatric Surgery which includes the following variants of atresia:

Type 1 – choledochal duct atresia

Type 2 – (a, b)

- 2a – atresia of the common hepatic duct

- 2b – atresia of the choledochus, hepatic duct, cystic duct and gallbladder with preservation of anastomoses, ducts in the hepatic hilum

Type 3 – atresia of the choledochal duct, hepatic duct and bile ducts of the hepatic hilum (without preservation of the anastomoses of the ducts in the hepatic hilum), in combination with atrophy of the gallbladder, without biliary content in the lumen.

All children from our study were diagnosed with type 3 BA according to the Japanese classification. It should be mentioned that it is very difficult to assess the level of biliary atresia preoperatively, and only intraoperative cholangiography can suggest the true effect of bile ducts, which determines the type of biliodigestive anastomosis.

Portoenterostomy (Kasai surgery) was performed in 6 patients. The surgery began with an extensive laparotomy approach, selected in each case. Other concomitant malformations were initially ruled out. Subsequently, suturing and resection of the sickle ligament was performed in order to mobilize the liver and visualize the operating field. For demonstrative confirmation of the diagnosis, intraoperative cholangiography and thin-needle biopsy of the liver parenchyma, segment 6, 7, 8, and marginal biopsy were performed. Confirmation of BA by intraoperative cholangiography was followed by retrograde cholecystectomy with preparation of fibrous cords in the liver gate and preparation of ductal plaque (fig. 6).

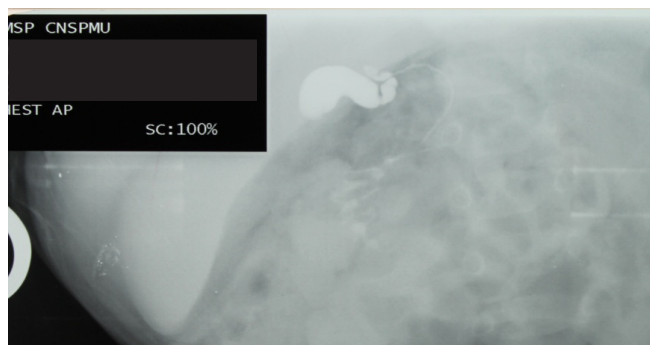


Fig. 6 . Intraoperator cholangiography

The left and right branch of the hepatic artery and the bifurcation of the portal vein served as the anatomical orientation of the ductal plaque boundaries . Safety loops were applied to the right and left hepatic arteries in order to provide a broader view of the ductal plaque and prevent bleeding in case of an operating accident (fig. 7).

The preparation of the fibrous callus was performed by applying a fixator on the fibrous tissue and two other loops (fixators) on the hepatic arteries. It is important to mention that hemostasis by electrocoagulation was never used in the preparation of the ductal plaque.

The preparation of the hepatic arteries by the fibrous tissue was performed until their branching into the hepatic tissue, which represented the reference plan for the dissection of the ductal plaque.

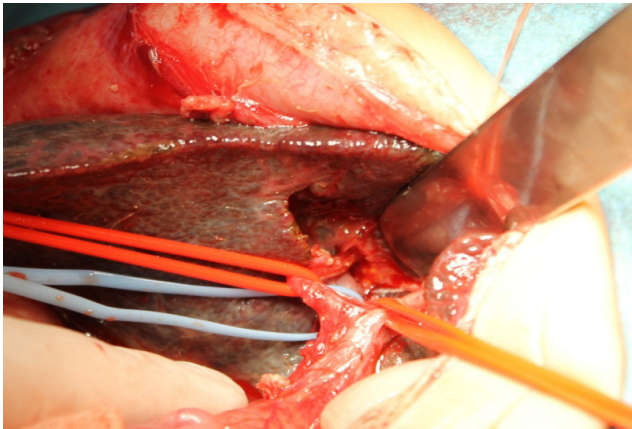


Fig. 7. Ductal plaque preparation

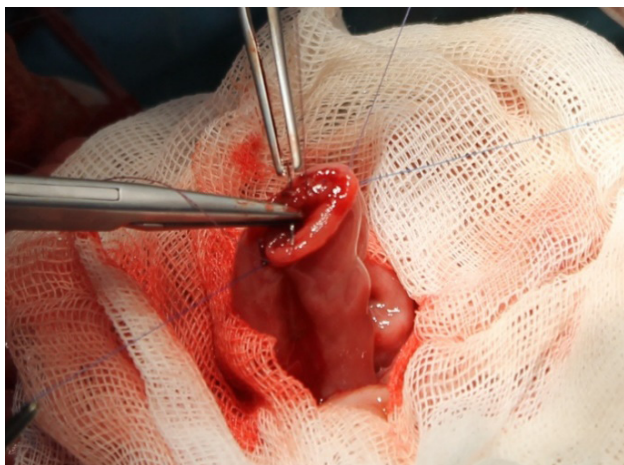
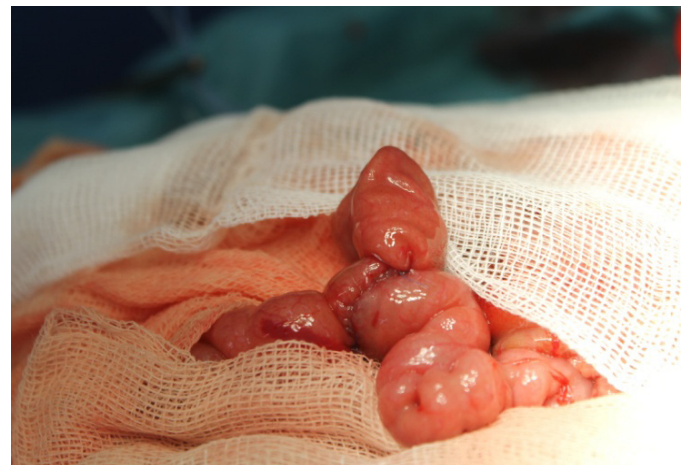

Fig. 8. Termino-lateral anastomosis formation



The success of the procedure was determined by the presence of microscopic permeability of the bile ducts. The 1st step finished by applying a buffer with 0.9% warm NaCl to the liver hilum, after an early irrigation. In 2 patients, the bile was removed with the naked eye, in which the Kasai procedure might be successful at 2-2.5 years.

The jejunum, with its proximal section 20 cm from the Treitz ligament, was used to restore the integrity of the biliary system and digestive tract and to prepare a Y-shaped Roux loop (fig 8).

The distal edge of the jejunum was closed by an inverted ligature. Subsequently, the termino-lateral jejunostomy was performed at 40-50 cm distance from the inverted edge of the distal jejunum ensuring intestinal continuity; the Roux loop was sutured cranially with the ileum at an angle of 6-8 cm from the anastomosis, which in our view facilitates evacuation of the gall and prevented the reflux from the ileum into the Roux loop. No anti-reflux valves on the Roux loop were applied.

Portoenterostomy was initiated with the application of continuous and interrupted absorbable sutures 6-0 (prolen, PDS, polyglatil, maxon) with the application of two fixatives to the corner of the posterior lip, subsequently the posterior lip was fixed with uninterrupted suture, whereas the

anterior lip was fixed with interrupted sutures with the subsequent formation of a jejunal lumen (fig. 9).

Every second suture was made in the dorsal wall of the open jejunum, ensuring the widest possible anastomosis with the complete inclusion of the sectioned fibrous surface.

Postoperatively, early feeding was encouraged due to the stimulation of bile secretion and the favorable effect on liver function. Choleric therapy with ursodeoxycholic acid (20-30 mg / kg daily in 2 doses) was indicated throughout the postoperative year. Phenobarbital was indicated at a dose of 5-10 mg/kg daily, for 30 days, in order to provide a prolonged activation of the microsomal enzymes of the hepatocyte endoplasmic reticulum.

Nasogastric drainage was performed until the restoration of intestinal function, which commonly lasted on avera-

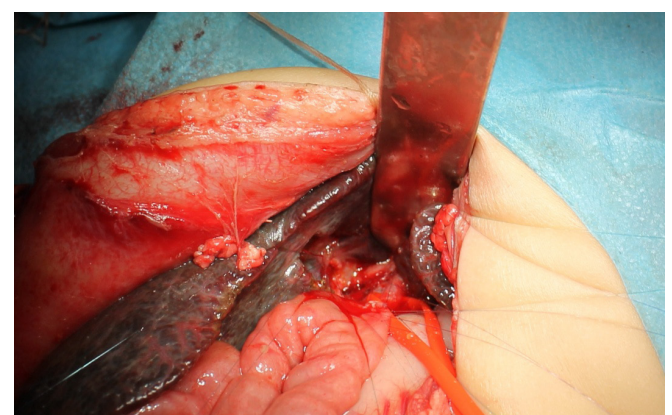


Fig. 9. Portoenteroanastomosis formation
(Posterior lip, prolen 6-0)

ge for 48 hours. Intravenous antibiotics were administered during the enteral feeding, being continued with long-term administration of oral antibiotics. Anti-inflammatory drugs were given for 21 days postoperatively. Homeostasis monitoring, general blood analysis, coagulogram, blood biochemistry and urinalysis were performed daily until the homeostasis stabilized, then once a week.

In the postoperative period, adequate drainage of the bile ducts was obtained in 4 patients. The postoperative

period for one patient was complicated by sclerosing cholangitis and hepatic impairment. Adequate biliary drainage was not obtained in two patients, thus 3 patients required liver transplantation at 6 months, 8 months and 9 months postoperatively.

Two patients were late diagnosed – at 4.5-5 months and one patient with BA embryonic form underwent initial liver transplantation. Two patients died after liver transplantation.

Two patients who were late diagnosed and hospitalized in an extremely serious condition died preoperatively.

Discussion

Embryological development of the biliary system begins in the 4th week of the hepatic diverticulum of the anterior primitive intestine [7]. Subsequently, the differentiation of the cranial and caudal components takes place, namely: the proximal extrahepatic ducts and most of the intrahepatic biliary system develop from the cranial segment, and the gallbladder, cystic duct and choledochus from the caudal one [8].

Although bile duct atresia is often associated with other congenital abnormalities, suggesting prenatal pathogenesis, the presence of progressive inflammatory bile duct lesions in children with isolated biliary atresia suggests perinatal exposure to a harmful factor [9].

The combination of biliary atresia with other congenital anomalies is fully demonstrated, with rates ranging from 10 to 50%. The most commonly reported cardiac abnormalities, persistence of the oval foramen, persistence of the arterial duct, ventricular septal defect, splenic and gastrointestinal abnormalities have been reported [10].

Each newborn-infant with cholestatic jaundice should be considered a patient with biliary atresia until the etiology is established [11]. To date, there is no true test that would differentiate between neonatal hepatitis (intrahepatic cholestasis) and biliary atresia [12].

In the neonatal period on the 3rd day, unconjugated hyperbilirubinemia has a physiological character (physiological jaundice). 2-15% of newborns retain this feature after 2 weeks postnatal and are defined by prolonged physiological jaundice (14-24 days), and only 0.2-0.4% are present with mechanical jaundice, without liver cholestasis or other disorders that would disrupt bile flow [12, 13]. Paradoxically, initially the most important indicator in the diagnosis of biliary atresia in a child with conjugated hyperbilirubinemia is the general lack of clear symptoms and signs of hepatocellular destruction [14].

Changes in scaloculometry after administration of the needle test. Ursodeoxycholic allows us to differentiate the diagnostic of BA from other liver pathologies complicated by cholestasis syndrome [15].

At the age of 3 weeks in children with BA, bile excretion is completely absent, which can be easily confirmed in VGDS. The resumption of biliary transit in case of a successful Kasai intervention is recorded for up to 30 days, and liver function is restored for several years [16]. The accelerated dynamics of hepatocellular destruction is complicated by biliary liver cirrhosis, intrahepatic PH, ascites,

esophageal varices with upper digestive hemorrhage [17]. Malabsorption of fat-soluble vitamins contributes to the development of anemia, malnutrition, weight and psycho-emotional retardation, rickets, xanthoma of the palms and knees, neuromuscular disorders [18].

Differential diagnosis. BA is a complicated and long-lasting process, due to the presence of a whole range of inflammatory, infectious, metabolic, genetic, syndromic, parasitic, specific pathologies, etc., which require a differential diagnosis [19, 20]. It is also necessary to differentiate the diagnosis with a series of very rare surgical pathologies, such as obstructive choledochal malformations, spontaneous perforation of the bile duct and hyperdense bile syndrome, congenital choledochal cyst, congenital liver fibrosis, etc. [19].

Therefore, ultrasonography and cholangiopancreatography are used, which highlight the common bile duct with a considerably dilated diameter (usually > 5 mm) or congenital choledochal cyst with considerable modification of the excretory shaft [2].

Spontaneous biliary perforation is manifested by ultrasound and by the presence of a small amount of fluid in the peritoneal cavity, as well as the presence of an echogenic mass at the transverse fissure of the liver [20].

Viscous bile syndrome usually occurs in premature infants. Ultrasound examination reveals a dilation of the bile duct, which contains hyperdense bile. In these cases, percutaneous cholangiography is performed and sometimes surgery to release the bile ducts from the obstruction [21]. The differential diagnosis is also made in various jaundice syndromes, such as: drug damage to the liver, congenital transport disorders (Crigler-Najar, Rotor, Dubin-Jonson, galactosemia, tyrosinemia, alpha-1-antitrypsin deficiency), neonatal hepatitis with giant cells, cytomegalovirus hepatitis and cystic fibrosis. Jaundice that persists during 30 days postnatally with the prevalence of conjugated bilirubin, 90% of cases are diagnosed as bile duct atresia. Jaundice due to hepatitis in the newborn is very difficult to differentiate [21, 22].

Liver biopsy, viral serology, and sweat testing are also performed for differential diagnosis. A diagnostic problem is biliary hypoplasia characteristic of Alagille syndrome, which can be misdiagnosed [22, 23].

The clinical features, such as specific facial expression, systolic murmur on the pulmonary artery (AP stenosis), spinal pathology or ophthalmic system may develop in patients with Alagille syndrome (cholestatic liver failure), but not in patients with extrahepatic bile duct atresia [23].

In biliary atresia the only solution is surgical treatment, general preoperative measures include parenteral administration of fat-soluble vitamins A, D, K, E; medium chain triglycerides as a source of fat (Lipofundin, SMOFlipid, etc.), desensitizers to alleviate skin itching [24]. Vitamin K (1-2 mg / Kg / day) is administered 3 days preoperatively. Oral feeding is stopped for 8 hours preoperatively [24].

Kasai surgery is the treatment of choice for extrahepatic biliary atresia becoming the surgical standard in extrahepatic biliary atresia, which was first performed in 1957 [25]. Kasai surgery is recommended in the first 90 days postnatal and only in extrahepatic forms of BA [26, 27].

The survival rate over 10 years after the Kasai procedure is 40-46% and continues to increase. Despite successful results worldwide, only 20-30% of patients survive until the age of 20 or more without a transplant [27].

The success of the Kasai procedure depends on the early diagnosis of BA, the application of portoenterostomy up to a maximum of 90 days postnatal, strict adherence to the surgical technique, prevention of complications and adequate postoperative monitoring [28].

Portoenterostomy should anticipate irreversible sclerosis of the intrahepatic bile ducts. Obtaining an obvious biliary flow of over 10mg of bilirubin per day can be appreciated as a success of surgical treatment [28, 29].

The rapid decrease of cholestatic syndrome with the return of biochemical indices within the norm in the first 6 months postoperatively indicates a long-term survival, while the presence of jaundice up to 1 year with maintenance of hepatocellular destruction, suggests the need for a planned liver transplantation. A successful intervention might be assessed by the appearance of the stool in 2 weeks postoperatively, at 6 months the total bilirubin does not exceed 50 mmol / l [29].

Many surgeons support the opinion of the initial liver transplant in children with biliary atresia, which would exclude the long-term risk for the evaluation of Kasai surgery. Others propose an initial liver transplant, only in those patients in whom the diagnosis of biliary atresia was established more than 120 days after birth, or in those with unfavorable histological changes. Currently, the opinion of the initial Kasai intervention is mainly supported in the surgical world, the liver transplant being an approach in cases of inefficiency of portoenterostomy [30].

The success of the treatment depends on several factors, of paramount importance being the age at which the Kasai operation was performed. Another key to success is performing the operation in the first 100 days, after which liver decompensation develops. However, it is difficult to estimate and predict treatment outcomes even in the first 40 days. Thus, the high rate of complications means that a large number of patients require a revision of the portoenterostomy [30].

The prognosis of untreated biliary atresia is unfavorable, leading to the death of most children in the first 2 years of life due to liver failure. The Kasai procedure, although not definitive in all patients, increases life expectancy considerably [31]. Survival at 5 years in patients without liver transplantation is approximately 30%. Thus, children with biliary atresia, in addition to the benefits of hepatoportoenteroanastomosis, also have a certain degree of residual liver failure, often with indications for liver transplantation. 50% of children aged 5 years with normal biochemical indications develop esophageal varices, and require endoscopic ligation, whereas 15% of them develop hemorrhages by varicose rash despite the drug and endoscopic treatment. Biliary cirrhosis subsequently occurs in 10% of patients with normalized serum bilirubin, and liver transplantation is indicated. The survival rate after Kasai surgery over 10 years in children with normal clinical-paraclinical indices does not exceed 10% [32, 33].

The success of the Kasai procedure depends on several factors: the age at which the surgery was performed, the exact dissection and transection of the liver hilum, the severity of the liver pathology, the postoperative treatment performed, and the occurrence of postoperative complications, especially cholangitis [33, 34].

The maintainance of acholic stools in the postoperative period and discontinued postoperative biliary excretion indicate an unfavorable prognosis. Death usually occurs within 1 year. The surgery performed after the age of 90 days significantly influences the unfavorable prognosis due to the progression of the sclerosing-destructive process of the bile duct and advanced hepatocellular destruction [35].

Patients who did not resist primary biliary drainage (15-30%), develop progressive liver failure, the optimal treatment being liver transplantation [36].

Conclusions

1. Biliary atresia is the most common cause of extrahepatic obstructive jaundice in newborns and is the most common indication for liver transplantation in children.

2. The embryonic form of BA is a severe condition that is indicated for the initial liver transplant. In this form, Kasai surgery is not effective and creates impediments to liver transplantation.

3. Biliary atresia is a serious pediatric condition that tends to develop into cirrhosis, liver failure and death.

4. Portoenteroanastomosis (Kasai surgery) performed as early as possible (up to 60 days postnatal) significantly increases the success of surgery.

5. The success of the Kasai procedure depends on several factors: the age at which the surgery was performed, the exact dissection and transection of the liver hilum, the severity of the liver pathology, and the occurrence of postoperative complications, especially cholangitis.

6. Liver transplantation remains the only treatment option in decompensated and late-diagnosed cases (over 120 days), as well as in those showing complications in the postoperative period resulting in liver failure.

7. The prognosis of untreated biliary atresia is unfavorable resulting in the death of most children in the first 2 years of life due to liver failure.

References

1. Chardot C. Biliary atresia. *Orphanet J Rare Dis.* 2006 Jul 26;1:28. doi: 10.1186/1750-1172-1-28.
2. Kelly DA, Davenport M. Current management of biliary atresia. *Arch Dis Child.* 2007;92(12):1132-1135. doi: 10.1136/adc.2006.101451.
3. Fischler B, Haglund B, Hjern A. A population-based study on the incidence and possible pre- and perinatal etiologic risk factors of biliary atresia. *J Pediatr.* 2002;141(2):217-222. doi: 10.1067/mpd.2002.126001.
4. Tiao MM, Tsai SS, Kuo HW, Chen CL, Yang CY. Epidemiological features of biliary atresia in Taiwan, a national study 1996-2003. *J Gastroenterol Hepatol.* 2008 Jan;23(1):62-6. doi: 10.1111/j.1440-1746.2007.05114.x.
5. Wada H, Muraji T, Yokoi A, Okamoto T, Sato S, Takamizawa S, Tsugawa J, Nishijima E. Insignificant seasonal and geographical variation in incidence of biliary atresia in Japan: a regional survey of over 20 years. *J Pediatr Surg.* 2007 Dec;42(12):2090-2. doi: 10.1016/j.jpedsurg.2007.08.035.
6. Moyer V, Freese DK, Whittington PF, et al. Guideline for the evaluation of cholestatic jaundice in infants: recommendations of the North American

- Society for Pediatric Gastroenterology, Hepatology and Nutrition. *J Pediatr Gastroenterol Nutr.* 2004;39(2):115-128. doi: 10.1097/00005176-200408000-00001.
7. Emerick KM, Whittington PF. Neonatal liver disease. *Pediatr Ann.* 2006;35(4):280-286. doi: 10.3928/0090-4481-20060401-13.
 8. Nwomeh BC, Caniano DA, Hogan M. Definitive exclusion of biliary atresia in infants with cholestatic jaundice: the role of percutaneous cholecysto-cholangiography. *Pediatric Surgery International.* 2007;23(9):845-849. doi: 10.1007/s00383-007-1938-2.
 9. Chardot C, Carton M, Spire-Bendelac N, et al. Is the Kasai operation still indicated in children older than 3 months diagnosed with biliary atresia? *J Pediatr.* 2001;138(2):224-228. doi: 10.1067/mpd.2001.111276.
 10. Razumovskii Alu, Ratnikov SA, Degtiareva AV, Kulicova NV. [Advantages of mini-access for Kasai surgery in children with biliary atresia]. [*Pirogov J Surg.*]. 2019;(3):48-59. doi: 10.17116/hirurgia201903148. Russian.
 11. Razumovskii Alu, Ratnikov SA. [Modern approaches to the surgical treatment of biliary atresia]. [*Russ J Pediatr Surg Anesth Intensive Care.*]. 2018;8(3):100-111. doi: 10.30946/2219-4061-2018-8-3-100-111. Russian.
 12. Hotineanu V, Ferdohleb A. Strategia chirurgicală în leziunile biliare post-operatorii și stricturile biliare benigne [Surgical strategy in postoperative biliary lesions and benign biliary strictures]. Chisinau: Lexon-Prim; 2016. 148 p. ISBN 978-9975-4072-7-4. Romanian.
 13. Alagille D. Extrahepatic biliary atresia. *Hepatology.* 1984;4(1 Suppl):7S-10S. doi: 10.1002/hep.1840040704.
 14. Chardot C, Carton M, Spire-Bendelac N, Le Pommelet C, Golmard JL, Auvert B. Prognosis of biliary atresia in the era of liver transplantation: French national study from 1986 to 1996. *Hepatology.* 1999;30(3):606-611. doi: 10.1002/hep.510300330.
 15. Chardot C, Serinet MO. Prognosis of biliary atresia: What can be further improved? *Journal Pediatr.* 2006;148(4):432-435. doi: 10.1016/j.jpeds.2006.01.049.
 16. Hung PY, Chen CC, Chen WJ, et al. Long-term prognosis of patients with biliary atresia: a 25 year summary. *J Pediatr Gastroenterol Nutr.* 2006;42(2):190-195. doi: 10.1097/01.mpg.0000189339.92891.64.
 17. Bezerra JA, Wells RG, Mack CL, Karpen SJ, Hoofnagle JH, Doo E, Sokol RJ. Biliary atresia: clinical and research challenges for the twenty-first century. *Hepatology.* 2018 Sep;68(3):1163-1173. doi: 10.1002/hep.29905.
 18. LeeVan E, Matsuoka L, Cao S, Groshen S, Alexopoulos S. Biliary-enteric drainage vs primary liver transplant as initial treatment for children with biliary atresia. *JAMA Surg.* 2019 Jan 01;154(1):26-32. doi: 10.1001/jamasurg.2018.3180.
 19. Moraru E, Aprodu SG, Nedelcu D, Hanganu E, Lupu G, Popovici P. Atrezia de căi biliare – management clinic și chirurgical (prezentare de caz) [Biliary atresia – clinical and surgical management (case study)]. *Pediatru.ro (MedicHub Media).* 2018 Apr;49. doi: 10.26416/Pedi.49.1.2018.1574. Romanian.
 20. Santos JL, Carvalho E, Bezerra JA. Advances in biliary atresia: from patient care to research. *Braz J Med Biol Res.* 2010;43(6):522-7. doi: 10.1590/S0100-879X2010007500035.
 21. Davenport M, Caponcelli E, Livesey E, Hadzic N, Howard E. Surgical outcome in biliary atresia: etiology affects the influence of age at surgery. *Ann Surg.* 2008;247:694-698. doi: 10.1097/SLA.0b013e3181638627.
 22. Davit-Spraul A, Baussan C, Hermeziu B, Bernard O, Jacquemin E. CFC1 gene involvement in biliary atresia with polysplenia syndrome. *J Pediatr Gastroenterol Nutr.* 2008;46(1):111-112. doi: 10.1097/01.mpg.0000304465.60788.f4.
 23. Spada M, Riva S, Maggioro G, Cintonio D, Gridelli B. Pediatric liver transplantation. *World J Gastroenterol.* 2009 Feb 14;15(6):648-674. doi: 10.3748/wjg.15.648. 24. Wehrman A, Waisbourd-Zinman O, Wells RG. Recent advances in understanding biliary atresia. *F1000Res.* 2019;8:F1000 Faculty Rev-218. doi: 10.12688/f1000research.16732.1.
 25. Shneider BL, Magee JC, Karpen SJ, et al. Total serum bilirubin within 3 months of hepatoporoenterostomy predicts short-term outcomes in biliary atresia. *J Pediatr.* 2016;170:211-7.e1-2. doi: 10.1016/j.jpeds.2015.11.058.
 26. Harpavat S, Garcia-Prats JA, Shneider BL. Newborn Bilirubin Screening for Biliary Atresia. *N Engl J Med.* 2016;375(6):605-6. doi: 10.1056/NEJMc1601230.
 27. Kim WR, Lake JR, Smith JM, et al. OPTN/SRTR 2016 Annual Data Report: Liver. *Am J Transplant.* 2018;18 Suppl 1:172-253. doi: 10.1111/ajt.14559
 28. Andrade WC, Silva MM, Tannuri ACA, Santos MM, Gibelli NEM, Tannuri U. Current management of biliary atresia based on 35 years of experience at a single center. *Clinics (Sao Paulo).* 2018;73:e289. doi: 10.6061/clinics/2018/e289.
 29. Chakhunashvili K, Pavlenishvili I, Kakabadeza M, Kordzaia D, Chakhunashvili D, Kakabadze. Biliary atresia: current concepts and future prospects (review). *Georgian Med News.* 2016;(255):104-11.
 30. Mack CL, Sokol RJ. Unraveling the pathogenesis and etiology of biliary atresia. *Pediatr Res.* 2005;57(5 Pt 2):87-94. doi: 10.1203/01.PDR.0000159569.57354.47.
 31. Zallen GS, Bliss DW, Curran TJ, Harrison MW, Silen ML. Biliary Atresia. *Pediatr Rev.* 2006;27(7):243-248. doi: 10.1542/pir.27-7-243.
 32. Ramachandran P, Safwan M, Reddy MS, Rela M. Recent trends in the diagnosis and management of biliary atresia in developing countries. *Indian Pediatr.* 2015;52(10):871-879. doi: 10.1007/s13312-015-0735-6.
 33. Kianifar HR, Tehrani S, Shojaei P, Adinehpour Z, Sadeghi R, Kakhki VR, et al. Accuracy of hepatobiliary scintigraphy for differentiation of neonatal hepatitis from biliary atresia: systematic review and meta-analysis of the literature. *Pediatr Radiol.* 2013;43(8):905-19. doi: 10.1007/s00247-013-2623-3.
 34. Inoue Y, Kato Y, Tamura T, Kobayashi H, Ichikawa S, Lane GJ, et al. Prognostic implications of bile lakes after surgery for biliary atresia. *J Pediatr Surg.* 2008;43(12):2165-8. doi: 10.1016/j.jpedsurg.2008.08.039.
 35. Bezerra JA, Spino C, Magee JC, Shneider BL, Rosenthal P, Wang KS, et al. Use of corticosteroids after hepatoporoenterostomy for bile drainage in infants with biliary atresia: The START randomized clinical trial. *JAMA.* 2014;311(17):1750-9. doi: 10.1001/jama.2014.2623.
 36. Neto B, Borges-Dias M, Trindade E, Estevão-Costa J, Campos JM. Biliary atresia – clinical series. *GE Port J Gastroenterol.* 2018;25:68-73. doi: 10.1159/000480708.

Authors' ORCID iDs and academic degrees

Gheorghe Gincu, MD, Ph, Associate Professor – <https://orcid.org/0000-0003-4350-5423>.
 Eva Gudumac, MD, PhD, Academician, Professor – <https://orcid.org/0000-0001-8474-4338>.
 Nina Braniște, MD – <https://orcid.org/0000-0001-7482-5214>.
 Ina Revenco, MD, PhD – <https://orcid.org/0000-0003-4976-0863>.
 Doina Haidarli, MD, PhD – <https://orcid.org/0000-0001-8604-4669>.
 Oleg Samciuc, MD – <https://orcid.org/0000-0003-1003-9657>.

Authors' contribution: GG drafted the first manuscript, NB acquired and interpreted the data, IR acquired and interpreted the data, DH acquired and interpreted the data, OS interpreted the data, EG designed the trial and revised the manuscript critically. All the authors revised and approved the final version of the manuscript.

Funding: The study was supported by Institute of Mother and Child and *Nicolae Testemitanu* State University of Medicine and Pharmacy. The authors are independent and take responsibility for the integrity of the data and accuracy of the data analysis.

Ethics approval and consent to participate: The research was approved by the Research Ethic Board of *Nicolae Testemitanu* State University of Medicine and Pharmacy (protocol No 55 of June 18, 2015).

Conflict of Interests: The authors have no conflict of interests to declare.