

## PERCUTANEOUS NEEDLE FASCIOTOMY IN DUPUYTREN CONTRACTURE

Elvira Fortuna, Alina Stoian, Viorica Mihailuța, Dana Cebotari, Daniela Popa, Grigore Verega

Clinica Chirurgie Plastică, Estetică și Microchirurgie Reconstructivă, Catedra Ortopedie și Traumatologie, IMSP USMF „Nicolae Testemițanu”, Chișinău, Republica Moldova.

### Introduction

Dupuytren's disease is a slowly progressive disorder, which affects the palmar fascia, that become tight and shortened and conduct to irreversible flexion posture of the fingers, that leads to hand deformity.. Percutaneous needle aponeurotomy is minimally invasive needle technique for Dupuytren contractures, with perfect short term results and fast recovery period, with no loss of function and with few complications.

### Keywords

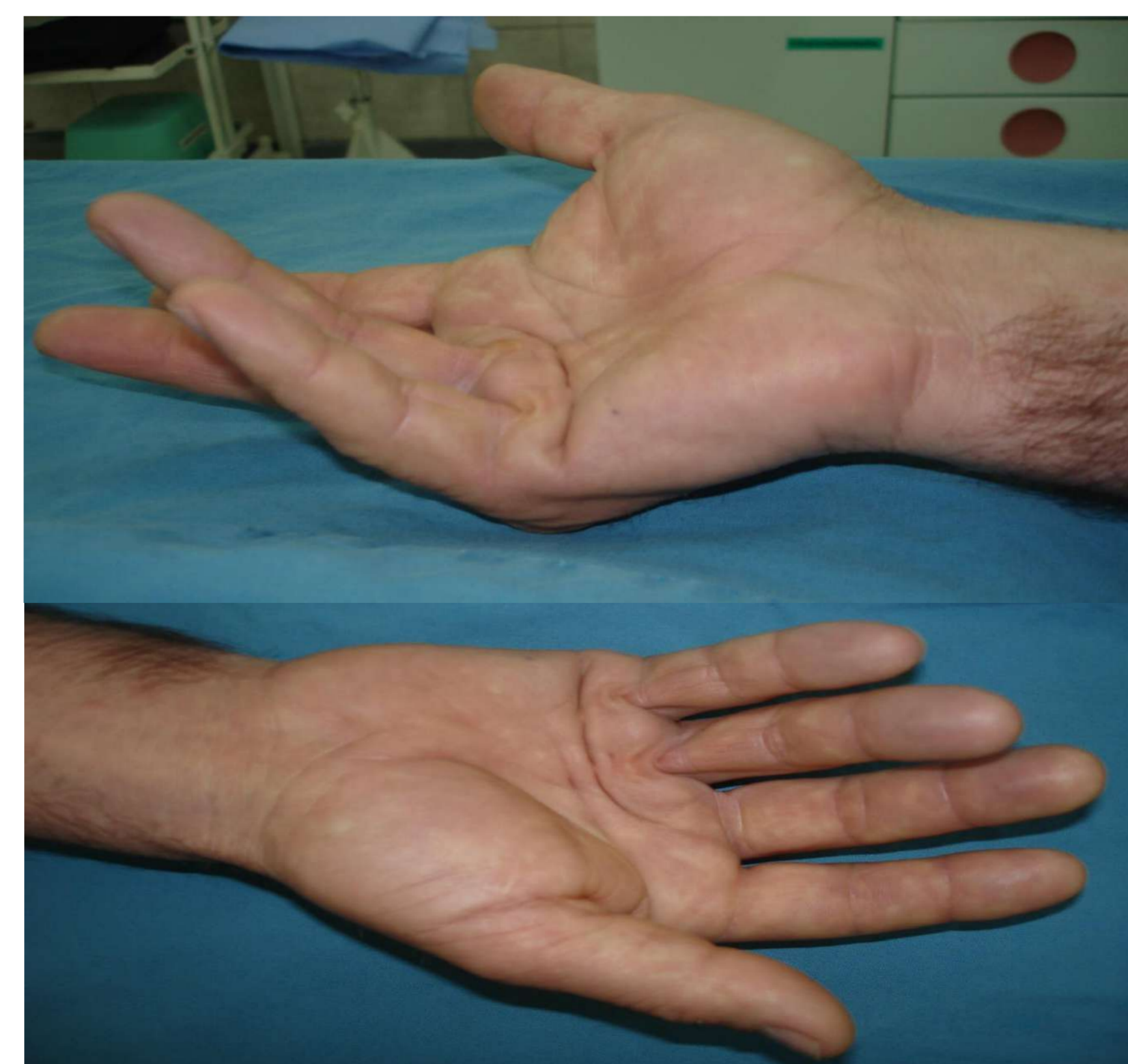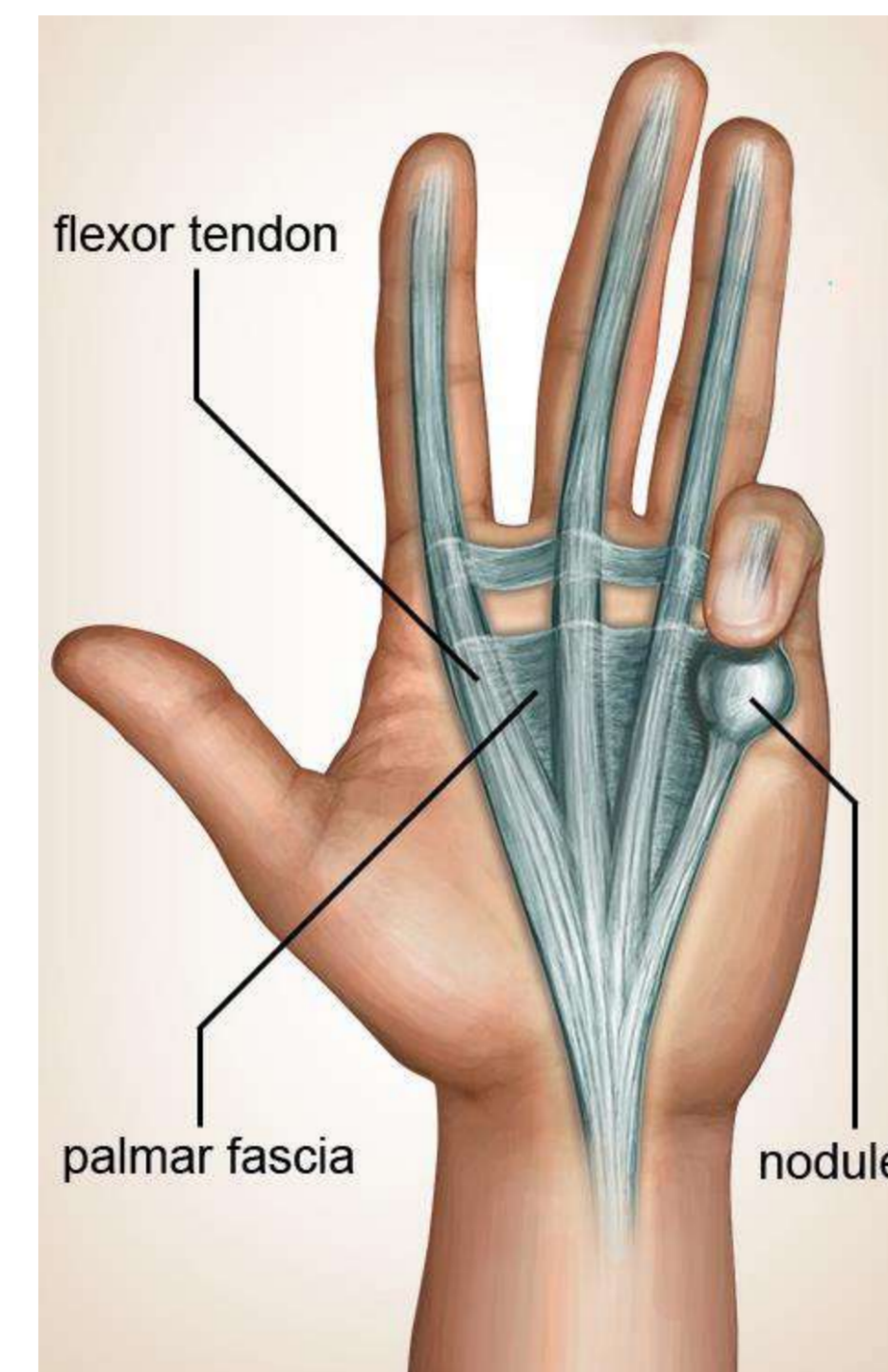
Dupuytren's contracture, percutaneous needle fasciotomy, mini-invasive treatment.

### Purpose

To present our clinical case and to show that percutaneous needle fasciotomy is an alternative and safe method for solving cases which need a fast recovery, without extensive interventions, with a good functional results.

### Material and methods

It was performed percutaneous needle fasciotomy to a 60-year-old male patient, being sectioned the pathologically modified palmar aponeurosis, to remove vicious finger position. The method consisted of multiple punctures at the palmar level, through which were sectioned the bridles, with the tip of the needle.



### Results

Patient supports trauma with a farm walk-behind tractor, resulting a leg's bone open fracture Gustilo-Anderson III "C". He supported 5 reconstructive surgeries and had to use the crutches during all that period of time. This leads, after 3 years, to appearance of Dupuytren's contracture at the right hand, (IV-Vth fingers), which significantly disrupt the use of crutches.

There was a need to find a suitable solution, for a minimally invasive treatment, with a quick and efficient recovery, and the best option was percutaneous needle fasciotomy.

Postoperative, it was obtained a full extension of fingers and a good functional result, without no skin deffect. 10 days after, the patient starts walking with crutches without no difficulty.

### Conclusions

Percutaneous needle fasciotomy is a minimally invasive treatment option for Dupuytren's contracture in the metacarpophalangeal and proximal interphalangeal joints , that requires a fast rehabilitation and allows to improve hand's function without bleeding incisions and distinguishes acceptable function and aesthetical aspect.

