

MORPHOLOGY AND VARIABILITY OF THE PAROTID PLEXUS

Babuci Angela¹, Catereniuc Ilia¹, Zorina Zinovia¹, Botnari Tatiana¹,
Lehtman Sofia², Strisca Stanislav², Nastas Liliana²

¹Department of anatomy and clinical anatomy

Nicolae Testemitanu State University of Medicine and Pharmacy, Republic of Moldova

²Department of oral and maxillofacial surgery and oral implantology „*Arsenie Guțan*”;

Nicolae Testemitanu State University of Medicine and Pharmacy, Republic of Moldova

angela.babuci@usmf.md

Abstract

Background. Modern medicine cannot be imagine without usage of high technology devices that have become an indispensable part of many medical examination methods. Nevertheless, anatomical dissection of human cadavers should not be neglected. Considering the high incidence of the facial nerve impairments, we decided to refresh the knowledge about the extracranial branching of the VIIth cranial nerve applying anatomical dissection on human cadavers.

Aim. The purpose of the study was to reveal the morphological specific features of the parotid plexus branching and types of connections among those branches that would definitely be useful in facial surgery.

Material and methods. The study was carried out on 55 cadaveric semiheads that previously had been fixed in 10% formalin solution: 39 male and 16 female semiheads; 29 of those samples were left (21 male/8 female) and 26 right side semiheads (18 male/8 female). A unilateral dissection was made on 23 semiheads and 32 semiheads were bilaterally dissected. Some samples were marked out with black paper for better contrast. All the dissected anatomical samples were photographed and the obtained data were statistically processed.

Results. The classic division of the facial nerve trunk into two primary branches: the temporofacial and cervicofacial one was detected in 39 cases (70,9%), in 15 cases (27,3 %) a diffuse type of the trunk division was detected and in 1 case there was a double trunk (1,8%). The following secondary divisions of the parotid plexus branches were highlighted: 1TB in 20 cases, 2 TB in 30 cases and 3 TB in 5 cases; 1 ZB in 5 cases, 2 ZB in 44 cases and 3 ZB in 6 cases; 2 BB in 9 cases, 3 BB in 13 cases, 4 BB in 16 cases, 5 BB in 14 cases, 6 BB in 2 cases and 8 BB in 1 case; 1 MMB in 45 cases, 2 MMB in 8 cases and 3 MMB in 2 cases; 1 CB in 42 cases, 2 CB in 10 cases and single cases of 3 CB, 4 CB and 6 CB respectively.

Conclusions. One of the main characteristic feature of the parotid plexus branches, both in males and females was the wide range of individual variability.

Key words: parotid plexus, facial nerve, branches, connections.

Introduction

Historical development of the *Homo sapiens* is imaginable without articulated speech, but the body language and especially facial expression, even in the 21st century, plays a significant role in human communication. A modern man spends a lot of time and money for his education, but at the same time, the people are very much concerned about their physical aspect. We believe that along with genetic, physical and psychical activity of a personality, his physiognomy depends a lot on anatomical structures and their relationships within the human body. Taking into consideration that anatomical dissection is the easiest way to prove variations of the human body neurovascular structures the purpose of this paper was to bring in some new facts about the extracranial segment of the facial nerve. Considering the impact of the facial nerve impairments on the human life quality, we tried to mark out the variations of the parotid plexus branches and to emphasize some specific features of that plexus.

Material and methods

Our study was carried out at the Department of anatomy and clinical anatomy of *Nicolae Testemitanu* State University of Medicine and Pharmacy of the Republic of Moldova. The project was approved by the Ethics Committee of the University according to the international requirements regarding research on human subjects (cadavers). As morphologists, we used the description of the

dissected samples and a retrospective analysis of the obtained data was done. In the current study 55 adult cadaveric semiheads have been dissected. The bilateral pattern of dissection was applied on 32 semiheads and unilateral dissection on 23 semiheads from the total number of samples. The cadaveric material was fixed in 10% formalin solution and the classic anatomical dissection was applied. Taking into consideration that in facial surgery there is a high risk of iatrogenic lesions of the peripheral branches of the facial nerve, we applied both the anterograde and retrograde dissection in order to find the most safety way of surgical intervention. In the majority of cases – 47 (87,3 %) the incision of the skin was started from the midsagittal plane of the forehead, continuing on the face around the eye, nose and lips up to the midline of the chin and preparation of the skin was continued up to the auricle of the ear and then the facial nerve trunk was identified. In other 7 cases (12,7 %) the incision of the skin was made in front and around the auricle towards the anterior midsagittal plane. It should be mentioned that only in 8 cases of the total prepared semiheads the retrograde dissection was applied. A range of bony and soft landmarks were used for the facial nerve trunk identification. The posterior belly of the digastric muscle, tragus and anterior margin of the auricular lobule were the most suitable soft tissue landmarks for us. The styloid and mastoid processes, the angle and posterior edge of the mandibular ramus, Borle's triangle [1, 2, 3, 4] were used as bony landmarks, that in our opinion, are more reliable for surgical access to the facial nerve trunk. In the anterograde dissection after the facial trunk identification, we continued preparation along the primary, secondary and gradually along all the other divisions until the terminal twigs. All the anatomical samples were photographed and the obtained data were statistically processed.

Results and discussion

Among the most common exogenous and endogenous factors that can cause facial paralysis are the viral and bacterial infections, head traumas, somatic diseases and metabolic disorders, parotid cancer, inflammatory diseases of the middle ear, iatrogenic injures in maxillofacial and aesthetic surgery [5, 6, 7, 8]. The facial nerve is involved in pathology of many cranial nerves, but mainly in vestibular schwannomas.

Preparation of the facial nerve on cadaveric material previously fixed in formalin solution gave the investigator a possibility to experiment various ways of access to the facial nerve trunk and to detect the most suitable landmarks for easy and safety way of facial trunk identification.

In the current study, on its exit from the *Fallopian* canal, the facial nerve trunk was divided into two primary branches the temporofacial and cervicofacial one in 39 cases (70,9 %), in other 15 cases (27,3 %) there was a diffuse type of facial trunk division and in a single case (1,8%) a double trunk was detected (figure 1). The primary branches give off a range of secondary divisions that in turn gave off the tertiary and terminal ones.

The following secondary divisions of the parotid plexus branches were distinguished: 1TB in 20 cases, 2 TB in 30 cases and 3 TB in 5 cases; 1 ZB in 5 cases, 2 ZB in 44 cases and 3 ZB in 6 cases; 2 BB in 9 cases, 3 BB in 13 cases, 4 BB in 16 cases, 5 BB in 14 cases, 6 BB in 2 cases and 8 BB in 1 case; 1 MMB in 45 cases, 2 MMB in 8 cases and 3 MMB in 2 cases; 1 CB in 42 cases, 2 CB in 10 cases and single cases of 3 CB, 4 CB and 6 CB respectively.

It should be mentioned that the number of secondary divisions varied from 1 to 8 branches. The highest number of divisions was characteristic of the buccal branches, and the lowest number was encountered for the temporal and zygomatic ones. We were surprised by a case of multiple divisions of the cervical branch identified in a female with 6 cervical branches on the left side and 4 cervical branches on the right side of the neck. The variation of secondary divisions of the parotid plexus branches is shown in figure 2.

According to our observations, the divisions of the extracranial part of the facial nerve varied much more in comparison with the known classified 6 types [9]. During dissection, we have identified some new types of divisions of the extracranial part of the facial nerve, named by us intermedi-

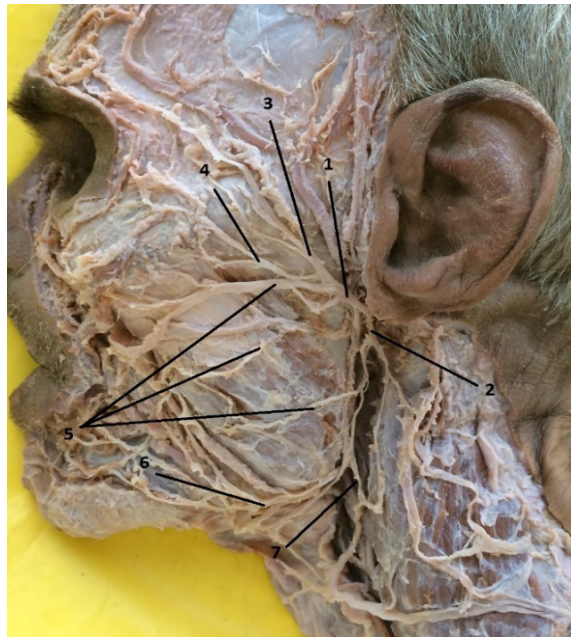

Figure 1. Extracranial branching of the facial nerve.

1 – temporofacial division; 2 – cervicofacial division; 3 – temporal branches; 4 – zygomatic branches; 5 – buccal branches, 6 – marginal mandibular branch; 7 – cervical branch.

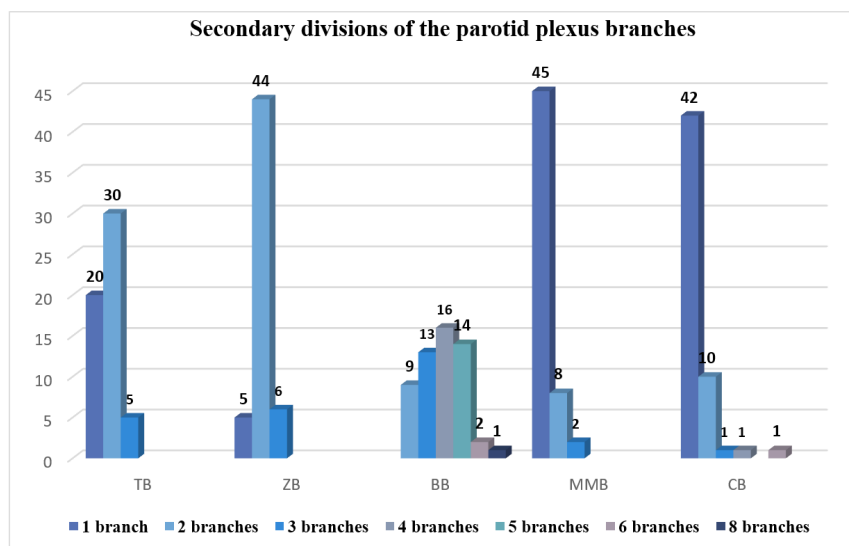


Figure 2. Variation of number of the parotid plexus branches.

* TB – temporal branches; ZB – zygomatic branches; BB – buccal branches; MMB – marginal mandibular branch; CB – cervical branch.

ate types [10]. In 2019 Martínez et al. proposed to review the classification of the types of the facial nerve extracranial branching and they extended the number of types up to 12 patterns [11].

The anatomical and topographical features of the parotid plexus branches increase its susceptibility to injuries in head traumas and to iatrogenic lesions in facial surgery. According to Yokoyama et al [12] the “facial nerve stretching during surgery has a significant serious effect on postoperative facial palsy” and removing the mastoid process in parotid ablation might be applied as a solution way for functional preservation of the facial nerve.

Considering our expertise in facial nerve dissection the most safety way for motor branches preservation is the anterograde dissection of the extracranial segment of the facial nerve. Anyway, there still is a high risk of iatrogenic injuries due to multiple variations of connections and branching of the parotid plexus.

Variations of the divisions were not the only individual features of the parotid plexus branches, as there was emphasized a variation of connections in the same individuals at the same time. In our study a range of variations of the shape and mode of motor branches connections from small loops to wide ones, triangular, oval and plexiform connections were identified among the parotid plexus branches [13].

A surgeon cannot predict the real course and divisions of the facial nerve due to high variation of the motor branches of the parotid plexus, but being aware of possible variations he can avoid some of those injures.

Taking into consideration the small number of temporal, marginal mandibular and cervical branches a surgeon should be aware about iatrogenic injures and postoperative complications when dissecting those divisions of the facial nerve.

The reconstructive surgery of the facial nerve is the only hope for some patients to improve their life quality and as soon as it is not a routine procedure any new details about facial nerve divisions, connections and topographic specific features might be useful for facial surgeons.

Conclusions

A high range of numerical variations of its branches and shapes of their connections that finally result in variability of the facial nerve branching types is a significant characteristic feature of the extracranial segment of the facial nerve. Taking into consideration the fact that there barely could be find out two similar divisions of the parotid plexus branches on the both sides in a single individual, we concluded that individual variability is a significant characteristic feature of the extracranial part of the facial nerve. Considering the high level of variability of the parotid plexus branches, we would recommend the facial surgeons to use the anterograde preparation of the extracranial branches of the facial nerve and to be aware of high risk of iatrogenic injures when using the retrograde dissection.

References

1. Davies J.C., Agur A. M. R., Fattah A.Y. Anatomic landmarks for localisation of the branches of the facial nerve. *OA Anatomy* 1 (4):33, 2013.
2. Saylam C., Ucerler H., Orhan M., Ozek C. Anatomic landmarks of the buccal branches of the facial nerve. *Surg Radiology Anat.* 28 (5):462-7, 2006.
3. Paul Sabini, Ivan Wayne et al. Anatomical Guides to Precisely Localize the Frontal Branch of the Facial Nerve. *Arch Facial Plast Surg.* 5:150-152, 2003.
4. Rajiv M. Borle, Anendd Jadhav, Nitin Bhola, Pawan Hingnikar, Prafulla Gaikwad. Borle's triangle: A reliable anatomical landmark for ease of identification of facial nerve trunk during parotidectomy. *Journal of Oral Biology and Craniofacial Research.* Vol. 9 (1), p. 33-36, 2019.
5. Kirici I, Kilic C, Kazkayasi M. Topographic anatomy of the peripheral branches of the facial nerve. *Journal of Experimental and Integrative Medicine* 1(3): 201-204, 2011.
6. Volk GF, Pantel M, Guntinas-Lichius O. Modern concepts in facial nerve reconstruction. *Head & Face Medicine* 6 (1):25, 2010.
7. Daniel C. Baker., John Conley. Avoiding Facial Nerve Injures in Rhytidectomy. *Plast Reconstr Surg.* 64:781-785, 1979.
8. Gosain AK, Matloub HS. Surgical management of the facial nerve in craniofacial traumas and long-standing facial paralysis: cadaver study and clinical presentation. *J Craniomaxillofacial Trauma.* 5(1):29-37, 1999.
9. Bergman R. A., Afifi A. K, Miyauchi R. Illustrated Encyclopedia of Human Anatomic Variation: Opus III: Nervous System Variations in Branching of Facial Nerve. /<http://www.anatomyatlases.org/>
10. Babuci A. Types of extracranial branching of the facial nerve. *Moldovan Medical Journal.* 2019;62(1):41-44, DOI: 10.5281/zenodo.2590015 UDC:611.831.7
11. Martínez Pascual P, Marañillo E, Vázquez T, Simon de Blas C, Lasso JM, Sañudo JR. Extracranial Course of the Facial Nerve Revisited. *Anat Rec (Hoboken).* 2019;302(4):599-608. doi:10.1002/ar.23825.
12. Yokoyama et al.: Impact of removing mastoid process for advanced parotid cancer on facial nerve identification, preservation and reconstruction. *Head & Face Medicine.* 10:6, 2014.
13. Babuci A. Variante de conexiune ale ramurilor plexului parotid: studiu pe cadavre/Variations of connections of the parotid plexus branches: a cadaveric study. În: *Moldovan Journal of Health Sciences.* 2015, 3 (5), p. 21-16. ISSN 2345-1467.