

## RESEARCH STUDIES

### The treatment of donor areas in patients with burns using preparations based on azo compounds

V. Babiuc

Department of Traumatology and Orthopaedics

Nicolae Testemitsanu State University of Medicine and Pharmacy, Chisinau, the Republic of Moldova

Corresponding author: babiucv@yahoo.fr. Manuscript received March 08, 2015; accepted September 03, 2015

#### Abstract

**Background:** The purpose of this work is to develop a new method of treatment of the skin donor areas without using a gauze dressing and, at the same time, isolating the affected area to prevent the infections and reduce to minimum the pain-causing factor.

**Material and methods:** For this purpose, there have been conducted studies using the preparations based on azo compounds as such azo compounds have the azo-group (-N = N-) in their molecular structure and have the property to react with the proteins forming azoproteins which further transform into a condensed substance. On the surface of skin they transformed into a membrane that covers tightly the area and isolates it from the environment. The studies were conducted in 222 patients with 1548 donor areas. Among them, 84 patients were children under the age of 14 and 138 adults.

**Results:** The results obtained have shown that the preparations based on azo compounds by entering into reaction with the proteins, contained in the wound, absorb all the discharges from the wound, become film rapidly, cement the microflora, avoiding its action, and fix onto the wound, isolating it from the surrounding environment.

**Conclusions:** 1. The preparations based on azo compounds are of great importance for the treatment of donor areas. 2. The membrane formed on the surface of the wound completely isolates the wound from the surrounding environment. 3. Following the application of the preparations based on azo compounds the pain reduces and this is extremely important for the treatment of burnt children, for whom the common treatment is affective.

**Key words:** preparations based on azo compounds, azoproteins, microflora, pain-causing factor.

#### Introduction

It is well known that the basic skin layer represents the source of epithelisation of the donor area. But, in case of any complications such as the action of microflora or resulting from the surgical technique, the epithelisation of the donor area is slow and extended. The dressing applied on the donor area causes much pain every time when changed and it is unendurable, especially for children. Therewith, we bear considerable costs for the dressing material.

The purpose of this work was to replace the gauze dressing with another type of dressing that would close tightly the wound, isolate the wound from the surrounding environment, block the action of microflora and exclude the pain.

With this in view, we used the preparations based on azo compounds for the treatment of donor areas.

#### Material and methods

Azo compounds are chemical substances included in the group of dyes having the azo group (-N = N-) in their molecular structure. They have the property to react with the proteins forming azoproteins which in turn quickly contract into a compact state.

The treatment was performed on 1548 donor areas of 222 patients (tab.1).

#### Results and discussions

In 7 (3.2%) cases out of the total number of patients complications appeared on the donor areas. The main cause of such complications was the fact that the patients had shower and washed off a part of preparation from the donor area.

After removing the skin graft, a gauze layer is applied on the surface of the donor area serving as a framing for the membrane formation on this surface. The azo compound 5% solution is then applied to the entire surface of the donor area using the forceps with a pad (fig. 1, 2).

The membrane on the surface of the donor area becomes firm, compact and well-fixed on the wound during 16-24 hours, depending on the temperature of the surrounding environment. The optimal temperature for membrane formation is 26°. The formed membrane causes no discomfort to the patient. In such conditions, children play and have a normal behaviour. The membrane formed on the surface of the donor area is firm and has a grey colour (fig. 3).

On the 9<sup>th</sup>-12<sup>th</sup> day after the surgery, when the surface of the donor area is epithelised, a layer of Vaseline is applied (fig. 4).

On the second day, the membrane is easily removed with a forceps (fig. 5). It becomes elastic due to the ointment action.

Knowing the length of time when the donor area epithelises, depending on the thickness of the graft, we can easily schedule the day of the membrane removal. In our

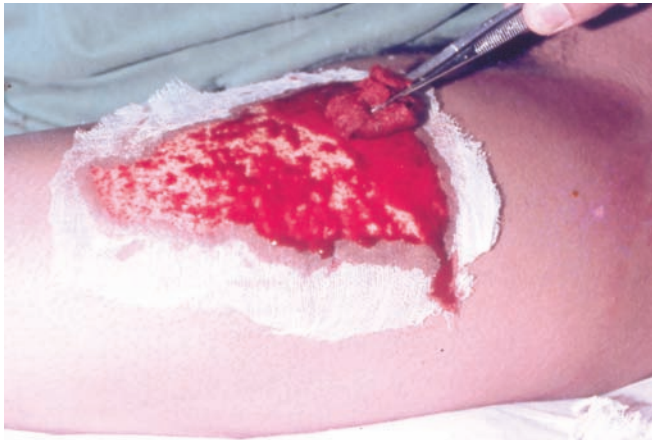

Fig. 1. Application of the azo compound solution.

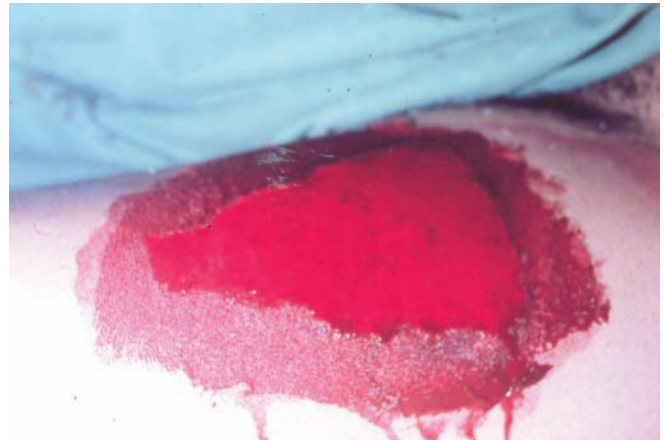


Fig. 2. Image of the complete coverage of the donor area.

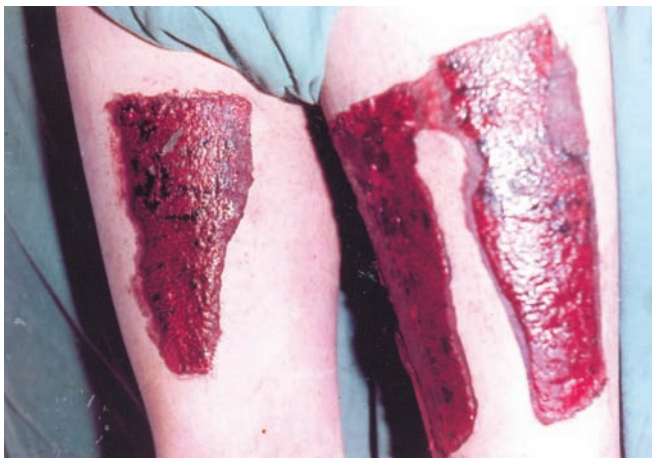

Fig. 3. The azo compound membrane on the surface of the donor area.

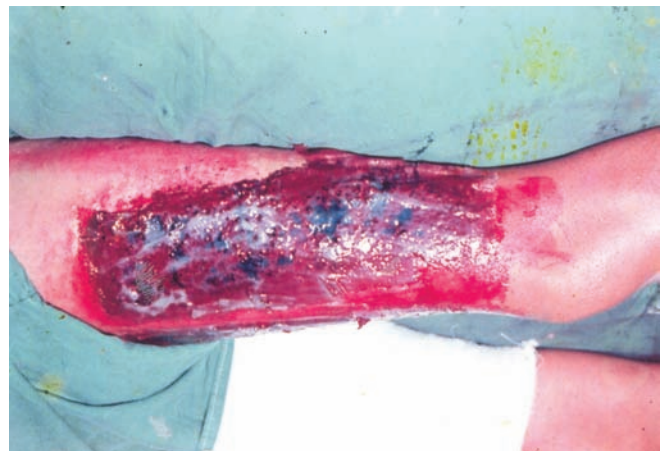

Fig. 4. Membrane surface covered with Vaseline.

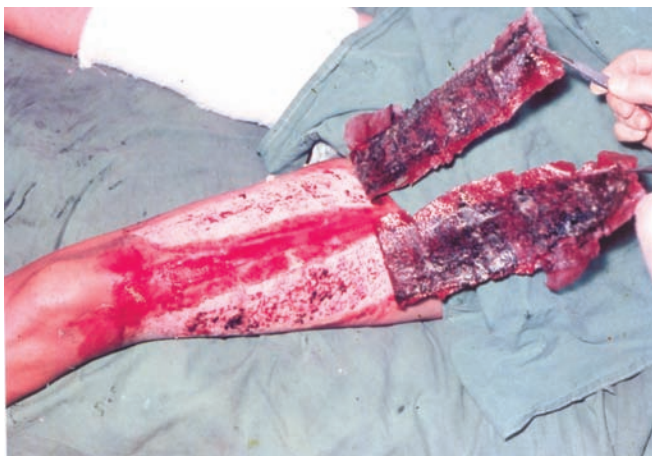

Fig. 5. Membrane removal.

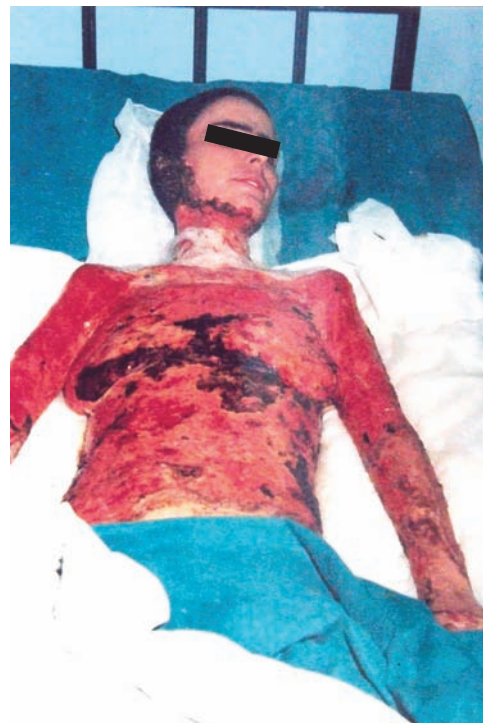

Fig. 6. The patient Maria P. on the 8<sup>th</sup> day after the trauma.

Table 1

## Results of the treatment of donor areas using preparations based on azo compounds

Affected surface	No. of patients	No. of surgeries	No. of donor areas	Mean epithelisation time	No. of donor areas with complication
up to 5% >	39	39	87	9	-
6-15	87	89	348	11	-
16-25	47	78	468	13	-
26-35	22	48	240	13	2 0.8%
36-45	11	34	217	15	3 (1.4%)
46-60	13	20	116	14	1 0.9%
60 and > %	3	15	72	15	1 1.3%
	222	323	1548	13	7 (3.2%)/(0.4%)

Note: 3.2% - as related to the number of patients, 0.4% - as related to the number of donor areas.

observations, 151 (68,4%) patients had been removed the membrane on the 9<sup>th</sup>-11<sup>th</sup> day after the surgery and only 71 (31,6%) patients had been removed the membrane after the 15<sup>th</sup> day after the surgery.

#### Example

The patient Maria P., 26 years old, medical record no. 373923, was admitted with I-II-IIIAB and IV degree burns on the face, neck, thorax, and abdomen and on the upper limbs. The affected surface constituted 46% of the body surface (IIIB-IV – 35%). The first stage of skin plasty was performed on the 15<sup>th</sup> day after the trauma, after 7 days – the second and, soon, the third stage of skin plasty were performed. She was discharged 59 days after the trauma (fig. 6).

The membrane formed on the surface of the donor area reduces the plasmorhea, reduces the pain to minimum and makes it possible to reduce the time interval between the surgeries. It also offers the possibility not to apply the dressing on the donor area of the patient during the treatment.

This method offers a great advantage for the treatment of burnt children.

#### Conclusions

1. Azo compounds have a very important role in the treatment of donor areas.
2. Using azo compounds in burns treatment of donor areas allows avoiding pain.

3. Preparations based on azo compounds used for the treatment of donor areas block the action of microflora in the wound.

4. Preparations based on azo compounds have a great advantage for the treatment of donor areas of the children.

#### References

1. Artruson G. The pathophysiology of severe thermal injury. *J. Burn Care Rehabil.* 1985;6:129-146.
2. Ateasov N. Sistema aktivnogo khirurgicheskogo lechenia tyazholykh bolnykh. Gorki, 1972.
3. Babiuc Alex. Tratatamentul local al arsurilor cu preparate azocomplexe. *Anale științifice ale USMF „N. Testemițanu”*, 2002;138.
4. Babiuc Victor. Le traitement des brûlés par azo-conjonctions. 8<sup>ème</sup> Congres de LAOLF, Bucharest, 2002;140.
5. Babiuc V, Marin I. Problemy profilaktiki ozhogov u detey. Aktualnye problemy zdavookhraneniya. Tez. dokl. Chișinău, 1986;II:134-136.
6. Carvajal H. Parks H. Burn in children. Year book medical publishers. Inc. Chicago, London: Boca Raton, 1987.
7. Kogan I. Khimia krasiteley. Izd. 3. M., 1956.
8. Davis J. Physiological Responses to Burning Injury. London: Academic Press, 1982.
9. Ereny J, Renaud F. Manuel de bactériologie clinique. Paris: Elsevier, 1992;11.
10. Hugo F, Carvajal M, Parks H. Burns in children. Chicago, London: Boca Raton, 1987.
11. Mhahar P, Padiglione AA, Clteland H, et al. Pseudomonas aeruginosa bacteremia in burns patients. *Burns.* 2010;36(8):1228-1233.
12. Orlov A. Ojogovaya infektsiya. L., 1973.
13. Tsollinger G. Khimia krasiteley. M., 1960;134.