

DOINA ȚURCAN, NATALIA UȘURELU, DANIELA BLĂNIȚĂ, VICTORIA SACARĂ

A RARE MITOCHONDRIAL DISORDER: LEIGH SYNDROME – A CASE REPORT

Institute of Mother and Child

REZUMAT

O TULBURARE MITOCHONDRIALĂ RARĂ: SINDROMUL LEIGH – PREZENTARE DE CAZ CLINIC

Cuvinte-cheie: sindromul Leigh; ADN mitocondrial; boală mitocondrială.

Introducere. Maladiile mitocondriale sunt un grup clinic eterogen de tulburări care apar ca urmare a disfuncției lanțului respirator mitocondrial. Sindromul Leigh este o tulburare neurodegenerativă progresivă, care afectează 1 din 40.000 de nou-născuți. Din punct de vedere genetic, modificările sau mutațiile complexului enzimatic respirator mitocondrial sau ale complexului piruvat dehidrogenază sunt responsabile pentru dezvoltarea sindromului Leigh.

Scopul acestui studiu este de a raporta o maladie mitocondrială neurodegenerativă rară la un copil cu convulsii, hipotonie, ataxie și retard psihomotor.

Materiale și metode. Raportăm un caz al unui băiețel de 20 luni, născut la termen la un cuplu sănătos neconsanguin. Pacientul a prezentat convulsii generalizate, hipotonie, tremor, ataxie, slăbiciune generală și oboseală, dificultăți de hrănire și întârziere psihomotorie.

Rezultate. În conformitate cu tabloul clinic al pacientului, a fost suspectată o eroare innăscută de metabolism. Lactatul din sânge, LDH și CK-MB au fost semnificativ crescute. Constatările imagistice au fost sugestive pentru o tulburare neurodegenerativă progresivă, caracteristice pentru encefalopatie mitocondrială. Analiza genetică a relevat mutația m.3243A>G în gena *TL1* a genomului mitocondrial.

Discuții. Caracteristicile sindromului Leigh sunt leziunile simetrice în ganglionii bazali sau la nivelul trunchiului cerebral vizualizate la IRM și o evoluție clinică caracterizată de deteriorarea rapidă a funcțiilor cognitive și motorii.

Concluzii. Apariția semnalelor bilaterale simetrice hiperintense a imaginii IRM în regim T2 care implică mai mulți nuclei/structuri ale trunchiului cerebral la un copil cu probleme neurologice ar trebui să determine clinicianul să ia în considerare sindromul Leigh și să efectueze investigații suplimentare, cum ar fi determinarea lactatului seric și, dacă este posibil, analiza genetică.

SUMMARY

A RARE MITOCHONDRIAL DISORDER: LEIGH SYNDROME – A CASE REPORT

Keywords: Leigh syndrome; mitochondrial DNA; mitochondrial disease.

Introduction. Mitochondrial diseases are a clinically heterogeneous group of disorders that arise as a result of dysfunction of the mitochondrial respiratory chain. Leigh syndrome is a progressive neurodegenerative disorder, affecting 1 in 40,000 live births. Genetically, alterations or mutations of the mitochondrial respiratory enzyme complex or pyruvate dehydrogenase complex are believed to be responsible for the development of Leigh syndrome.

The aim of this study is to report a rare progressive neurodegenerative, mitochondrial disorder in a child with seizures, hypotonia, ataxia and psychomotor delay.

Material and methods. We report on a case of a 20 months old boy, born from non-consanguineous, healthy parents. The patient presented with generalized seizures, hypotonia, tremor, ataxia, general weakness and fatigue, feeding difficulty and psychomotor retardation.

Results. According to the patient's clinical picture, an inborn error of metabolism was suspected. Blood lactate, LDH and CK-MB were markedly elevated. The imaging findings suggested a progressive neurodegenerative disorder with

the possibility of a mitochondrial encephalopathy. Genetic analysis revealed the m.3243A>G mutation in the *TL1* gene of the mitochondrial genome.

Discussions. Hallmarks of Leigh disease are symmetrical lesions in the basal ganglia or brain stem on MRI, and a clinical course with rapid deterioration of cognitive and motor functions.

Conclusions. Bilateral symmetric T2 prolongation involving multiple brainstem nuclei/structures in a child with neurological problems should prompt the clinician to consider Leigh syndrome and conduct further investigations such as measurement of blood lactate, and if possible, genetic analysis.

РЕЗЮМЕ

РЕДКОЕ МИТОХОНДРИАЛЬНОЕ ЗАБОЛЕВАНИЕ: СИНДРОМ ЛЕЯ – ОПИСАНИЕ КЛИНИЧЕСКОГО СЛУЧАЯ

Ключевые слова: Синдром Лея; митохондриальная ДНК; митохондриальное заболевание.

Введение: Митохондриальные заболевания – это клинически неоднородная группа нарушений, возникающих в результате дисфункции митохондриальной дыхательной цепи. Синдром Лея – прогрессирующее нейродегенеративное заболевание, которым страдает 1 из 40.000 новорожденных. Генетически, изменения или мутации комплекса митохондриальных респираторных ферментов или комплекса пируватдегидрогеназы ответственны за развитие синдрома Лея.

Цель исследования – сообщить о редком прогрессирующем нейродегенеративном митохондриальном нарушении у ребенка с судорогами, гипотонией, атаксией и задержкой психомоторного развития.

Материалы и методы: мы сообщаем о клиническом случае пациента в возрасте 20 месяцев, рожденном в некровнородственном браке здоровых родителей. У пациента жалобы на генерализованные судороги, гипотонию, тремор, атаксию, общую слабость и утомляемость, трудности с кормлением и задержку психомоторного развития.

Результаты: В соответствии с клинической картиной пациента было подозрение на врожденное нарушение обмена веществ. Лактат в крови, ЛДГ и СК-МВ были заметно повышены. Результаты томографии свидетельствуют о прогрессирующем нейродегенеративном заболевании с возможностью митохондриальной энцефалопатии. Генетический анализ выявил мутацию m.3243A>G в гене *TL1* митохондриального генома.

Обсуждения: Признаками болезни Лея являются симметричные поражения базальных ганглиев или ствола мозга на МРТ и клиническое течение с быстрым ухудшением когнитивных и двигательных функций.

Заключение: Двустороннее симметричное повышение интенсивности сигнала на T2 с участием нескольких ядер / структур ствола мозга у ребенка с неврологическими проблемами должно побудить клинициста рассмотреть вопрос о синдроме Лея и провести дальнейшие исследования, такие как измерение концентрации лактата в крови и, если возможно, генетический анализ.

Introduction. Mitochondria are ubiquitous cellular organelles, except in erythrocytes, and are crucial integrators of intermediary metabolism in various cellular metabolic pathways, including oxidative phosphorylation, fatty acid oxidation, Krebs cycle, urea cycle, gluconeogenesis and ketogenesis [1]. Mitochondria also have an important role in other important cellular processes, including (non-shivering) thermogenesis [2], amino acid metabolism, lipid metabolism [3], biosynthesis of haem and iron-sulfur clusters [4], calcium homeostasis [5] and apoptosis [6]. The pathophysiology of mitochondrial diseases is complex and involves genetic mutations in mitochondrial DNA (mtDNA) and nuclear DNA (nDNA). This complex genetics means that mitochondrial diseases can have

any pattern of inheritance, including autosomal and X-linked inheritance for nDNA mutations and maternal inheritance for mtDNA mutations. Rare sporadic cases due to de novo mutations have also been noted. In patients with mtDNA mutations, inheritance and clinical presentation are further complicated by the presence of multiple mtDNA genomes in an individual cell, which can often lead to a mixture of mutated and wild-type genomes, called heteroplasmy [1]. In general, the proportion of mitochondrial genomes that harbor a pathogenic variant directly correlates with disease severity [7]. Many healthy individuals have low levels of pathogenic variants accumulate in some tissues with age, although if a pathogenic variant reaches a certain threshold heteroplasmy level that may vary greatly

by tissue energy demand, phenotypic symptoms may develop over time [8]. Clinical manifestations may range from isolated organ involvement with onset late in life to onset of severe multisystem problems in the newborn period leading to early death [9].

Mitochondrial disease manifestations are notoriously heterogeneous, with involvement of potentially any organ system at any age. The prevalence of all forms of childhood-onset (<16 years of age) mitochondrial diseases has been estimated to range from 5 to 15 cases per 100,000 individuals [1]. In adults, the prevalence of mitochondrial diseases caused by mutations in mtDNA is estimated at 9.6 cases per 100,000 individuals and the prevalence of mitochondrial diseases caused by mutations in nDNA is 2.9 cases per 100,000 individuals [10].

Leigh syndrome (also called Leigh disease or subacute necrotizing encephalomyelopathy) is a rare inherited neurometabolic disorder and affects the central nervous system. Genetically, alterations or mutations of the mitochondrial respiratory enzyme complex or pyruvate dehydrogenase complex are believed to be responsible for the development of Leigh syndrome [11]. This mitochondrial encephalopathy mostly occurs in infancy and early childhood, affecting around 1 per 40,000 newborns [12]. It is characterized by hyperlactacidemia and necrotizing lesions that are symmetrically distributed in the basal ganglia and brain stem and cause a rapid decline in cognitive and motor functions. Affected children usually present with a series of neurological symptoms that include growth retardation, ataxia, dystonia, seizures, hypotonia, vision loss, and in some cases, apnea [13]. Onset of disease is very early and follows a rapidly progressive course with most children succumbing before they reach the age of 3 years [14].

Typical neuroimaging reveals symmetrical hyperintensity in T2-weighted images in magnetic resonance imaging (MRI) in basal ganglia and/or brainstem with a lactate peak in affected areas in spectroscopy. In addition, cerebral white matter, thalamus, spinal cord and cerebellum may be affected as well. The neurons of higher energy demand in dysfunctional stock of ATP trigger a stress cascade culminating in gliosis and vacuolization of neuronal tissue over time [15].

Diagnosis of Leigh syndrome can be challenging. As far as the overall investigation it includes clinical records, family history, physical examination, biochemical evaluation in body fluid samples (lactate, pyruvate, glucose, blood gas profile, amino acids profile in blood/spinal fluid and organic acids in urine), specific muscular tissue analysis (assessment of mitochondrial respiratory chain complexes) and ideally genetic identification of the responsible variant. As biochemical approach is not always elucidative or safe, genetic evaluation has become an eligible initial step in investigation especially if a pattern of signs and/or symptoms is found suggesting a specific condition or complex/complexes deficiency.

The prognosis of LS is reserved and despite ongoing trials

and progress, there is no curative treatment available, only towards supporting symptoms and avoiding metabolic crisis [16]. There is no cure for mitochondrial disease for Leigh syndrome, and a genetic diagnosis is therefore crucial for genetic counselling and recurrence risk calculation, and can impact on the clinical management of affected patients.

The aim of this study is to report a rare progressive neurodegenerative, mitochondrial disorder in a child with seizures, hypotonia, ataxia and psychomotor delay.

Materials and Methods. We report on a case of a 20 months old boy, born at term weighing 3030 g from non-consanguineous, healthy parents. The patient developed normally till 17 months old when he began to present generalized seizures. Initially, the patient responded well to valproate. Two months later the convulsive crises reappeared partially with a tremor, ataxia, general weakness and fatigue, feeding difficulty, psychomotor delay (does not sit, not walk, not speak). At the moment of the evaluation, he presented poor body weight (8 kg), hepatomegaly (+2 cm), macroglossia (hypothyroidism was excluded), short stature and anemia.

He had no family history of any genetic or neurological disorder. Leigh syndrome was suspected based on clinical course and brain images.

Results. According to the patient's clinical picture, an inborn error of metabolism was suspected and the first-line investigations used in this case indicated elevated lactate in blood [2.2-2.4 mmol/L; ref. val. 0,72,1 mmol/L], hyperaminoaciduria, high level of LDH [743 UI; ref. val. 135-225 UI] and CK-MB [38 UI; ref. val. <24 UI]. Amino acid analysis was performed in the blood and urine and a high level of alanine [594 μ mol/L; ref. val. <450 μ mol/L] and deviant Ala/Lys ratio [3.44, abnormal if >3] was determined. CK and serum transaminases levels were within normal range. The EKG showed irregular sinus rhythm.

The secondary line of investigations performed in case of inborn error of metabolism using electroencephalography (EEG) revealed dysfunction in cortical structures and low convulsive threshold. The results of the electromyography (EMG) showed reduced widespread of muscle and peripheral nerves.

Magnetic resonance imaging (MRI) results revealed suggestive signs for a neurodegenerative process. MRI results showed symmetrical foci of cytotoxic edema at the level of thalamus, mesencephalon (substantia nigra), brainstem, medullary tegmentum and cerebellar hemispheres (periventricular) and medulla oblongata (fig. 1).

The cerebral cortex and the white matter of the hemispheres had normal signal characteristics, without pathological changes. Magnetic resonance imaging tractography determined signs of myelin sheath damage to the fibers of the middle cerebellar pedicle, mainly on

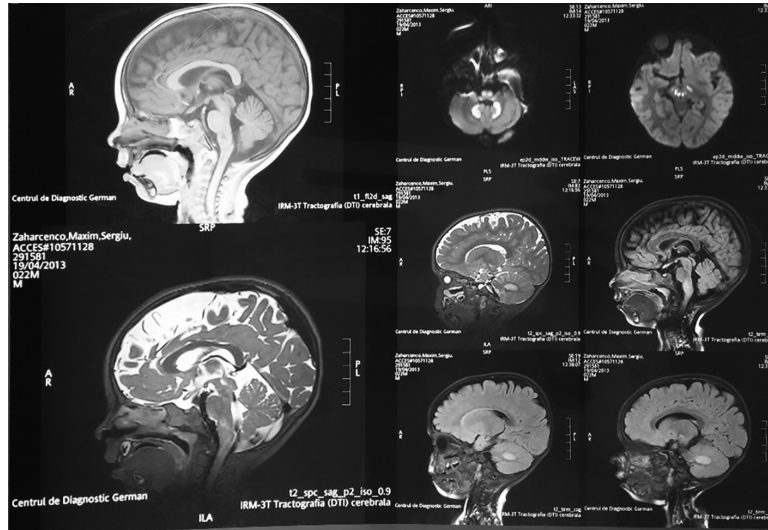


Figure 1. MRI findings of Leigh syndrome – symmetrical hyperintensity in T2-weighted images in thalamus, mesencephalon, brainstem, medullary tegmentum and cerebellar hemispheres (periventricular) and medulla oblongata

the left and at the level of the corticospinal tract in the projection of the mesencephalon.

Genetic analysis was performed using High Resolution Melting (HRM). High resolution melt (HRM) analysis is a technique that measures the disassociation of double-stranded DNA at high temperature resolution, and permits the analysis of genetic variations in PCR

amplicons [17]. HRM experiments generate DNA melt curve profiles that are both specific and sensitive enough to distinguish nucleic acid species based on small sequence differences, enabling mutation scanning. Genetic analysis performed using the HRM technique revealed the presence of point mutation m.3243A>G in the *TL1* gene of the mitochondrial genome (fig. 2).

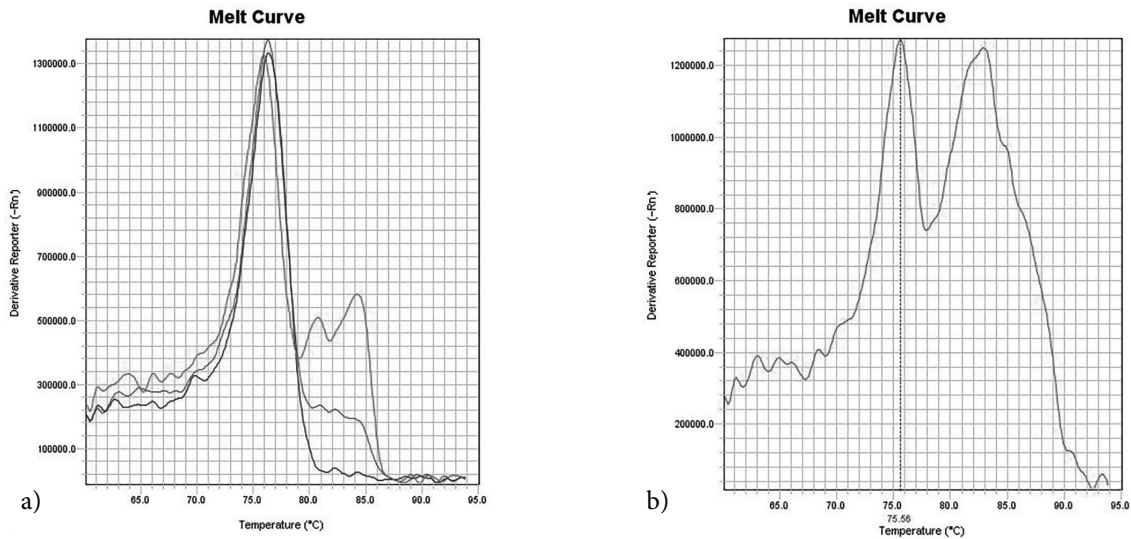


Figure 2. a) Melting curve of amplicon-based controls for m.3243A>G mutation. b) Melting curve of the patient's DNA for m.3243A>G mutation

Discussions. Leigh Syndrome, also termed as subacute necrotizing encephalopathy is a rare, inherited progressive neurodegenerative disorder with characteristic pathological features usually presenting in infancy or early childhood. Clinically, Leigh syndrome is characterized by psychomotor delay or regression, muscular hypotonia, brainstem signs (especially strabismus, nystagmus and swallowing difficulties), ataxia, pyramidal signs, respiratory

insufficiency, lactate acidemia and acute deterioration following common infections. Affected children usually become symptomatic within the first year of life with feeding difficulties, vomiting and failure to thrive. Death usually occurs within a few years after onset of symptoms, typically from progressive respiratory failure [18]. Hallmarks of the disease are symmetrical lesions in the basal ganglia or brain stem on MRI, and a clinical

course with rapid deterioration of cognitive and motor functions. Specific treatment for the Leigh syndrome is not available and available therapeutic options are limited. Symptomatic treatment is usually given to improve the ATP production and to lower the lactate levels.

This child presented to us with seizures, tremor, general weakness and psychomotor retardation. These symptoms pointed towards a neurodegenerative disorder. Examination revealed delayed development, hypotonia and ataxia, all of which are recognized features of Leigh syndrome. Blood lactate, LDH and CK-MB were markedly elevated. The imaging findings suggested a progressive neurodegenerative disorder with the possibility of a mitochondrial encephalopathy. This is consistent with the neuro-radiological findings in previous reports of Leigh Syndrome [19]. Enzymology, histology and functional fibroblast ATP synthesis rate were not performed due to the paucity of facilities and financial constraints.

Conclusions. The diagnosis of Leigh's disease should be considered in appropriate clinical and laboratory settings whenever symmetrical hypodensities are encountered in the putamina and midbrain on CT and further investigated with MRI. Our experience suggested that bilateral symmetric T2 prolongation involving multiple brainstem nuclei/structures in a child with neurological problems should prompt the clinician to consider Leigh syndrome and conduct further investigations such as measurement of blood lactate, and if possible, genetic analysis.

BIBLIOGRAPHY

1. G. S. Gorman *et al.*, "Mitochondrial diseases," *Nat. Rev. Dis. Prim.*, 2016, doi: 10.1038/nrdp.2016.80.
2. S. Gambert and D. Ricquier, "Mitochondrial thermogenesis and obesity," *Current Opinion in Clinical Nutrition and Metabolic Care*. 2007, doi: 10.1097/MCO.0b013e3282f0b69d.
3. J. A. Mayr, "Lipid metabolism in mitochondrial membranes," *J. Inherit. Metab. Dis.*, 2015, doi: 10.1007/s10545-014-9748-x.
4. J. J. Braymer and R. Lill, "Iron-sulfur cluster biogenesis and trafficking in mitochondria," *Journal of Biological Chemistry*. 2017, doi: 10.1074/jbc.R117.787101.
5. S. Romero-Garcia and H. Prado-Garcia, "Mitochondrial calcium: Transport and modulation of cellular processes in homeostasis and cancer (Review)," *International Journal of Oncology*. 2019, doi: 10.3892/ijo.2019.4696.
6. J. Lopez and S. W. G. Tait, "Mitochondrial apoptosis: Killing cancer using the enemy within," *British Journal of Cancer*. 2015, doi: 10.1038/bjc.2015.85.
7. H. Zhang, S. P. Burr, and P. F. Chinnery, "The mitochondrial DNA genetic bottleneck: Inheritance and beyond," *Essays in Biochemistry*. 2018, doi: 10.1042/EBC20170096.
8. E. M. McCormick, Z. Zolkipli-Cunningham, and M. J. Falk, "Mitochondrial disease genetics update: Recent insights into the molecular diagnosis and expanding phenotype of primary mitochondrial disease," *Current Opinion in Pediatrics*. 2018, doi: 10.1097/MOP.0000000000000686.
9. C. C. Muraresku, E. M. McCormick, and M. J. Falk, "Mitochondrial Disease: Advances in Clinical Diagnosis, Management, Therapeutic Development, and Preventative Strategies," *Curr. Genet. Med. Rep.*, 2018, doi: 10.1007/s40142-018-0138-9.
10. G. S. Gorman *et al.*, "Prevalence of nuclear and mitochondrial DNA mutations related to adult mitochondrial disease," *Ann. Neurol.*, 2015, doi: 10.1002/ana.24362.
11. X. Chang, Y. Wu, J. Zhou, H. Meng, W. Zhang, and J. Guo, "A meta-analysis and systematic review of Leigh syndrome: clinical manifestations, respiratory chain enzyme complex deficiency, and gene mutations," *Medicine (Baltimore)*, 2020, doi: 10.1097/MD.00000000000018634.
12. N. Darin, A. Oldfors, A. R. Moslemi, E. Holme, and M. Tulinius, "The incidence of mitochondrial encephalomyopathies in childhood: Clinical features and morphological, biochemical, and DNA abnormalities," *Ann. Neurol.*, 2001, doi: 10.1002/ana.75.
13. L. Chen *et al.*, "Management of Leigh syndrome: Current status and new insights," *Clinical Genetics*. 2018, doi: 10.1111/cge.13139.
14. N. J. Lake, M. J. Bird, P. Isohanni, and A. Paetau, "Leigh Syndrome: Neuropathology and Pathogenesis," *Journal of Neuropathology and Experimental Neurology*. 2015, doi: 10.1097/NEN.0000000000000195.
15. F. Baertling *et al.*, "The many faces of paediatric mitochondrial disease on neuroimaging," *Child's Nervous System*. 2016, doi: 10.1007/s00381-016-3190-3.
16. M. B. Schubert and L. Vilarinho, "Molecular basis of Leigh syndrome: A current look," *Orphanet Journal of Rare Diseases*. 2020, doi: 10.1186/s13023-020-1297-9.
17. M. Tamburro and G. Ripabelli, "High resolution melting as a rapid, reliable, accurate and cost-effective emerging tool for genotyping pathogenic bacteria and enhancing molecular epidemiological surveillance: A comprehensive review of the literature," *Ann. di Ig.*, 2017, doi: 10.7416/ai.2017.2153.
18. F. Baertling *et al.*, "A guide to diagnosis and treatment of Leigh syndrome," *Journal of Neurology, Neurosurgery and Psychiatry*. 2014, doi: 10.1136/jnnp-2012-304426.
19. M. Gerards, S. C. E. H. Sallevelt, and H. J. M. Smeets, "Leigh syndrome: Resolving the clinical and genetic heterogeneity paves the way for treatment options," *Molecular Genetics and Metabolism*. 2016, doi: 10.1016/j.ymgme.2015.12.004.