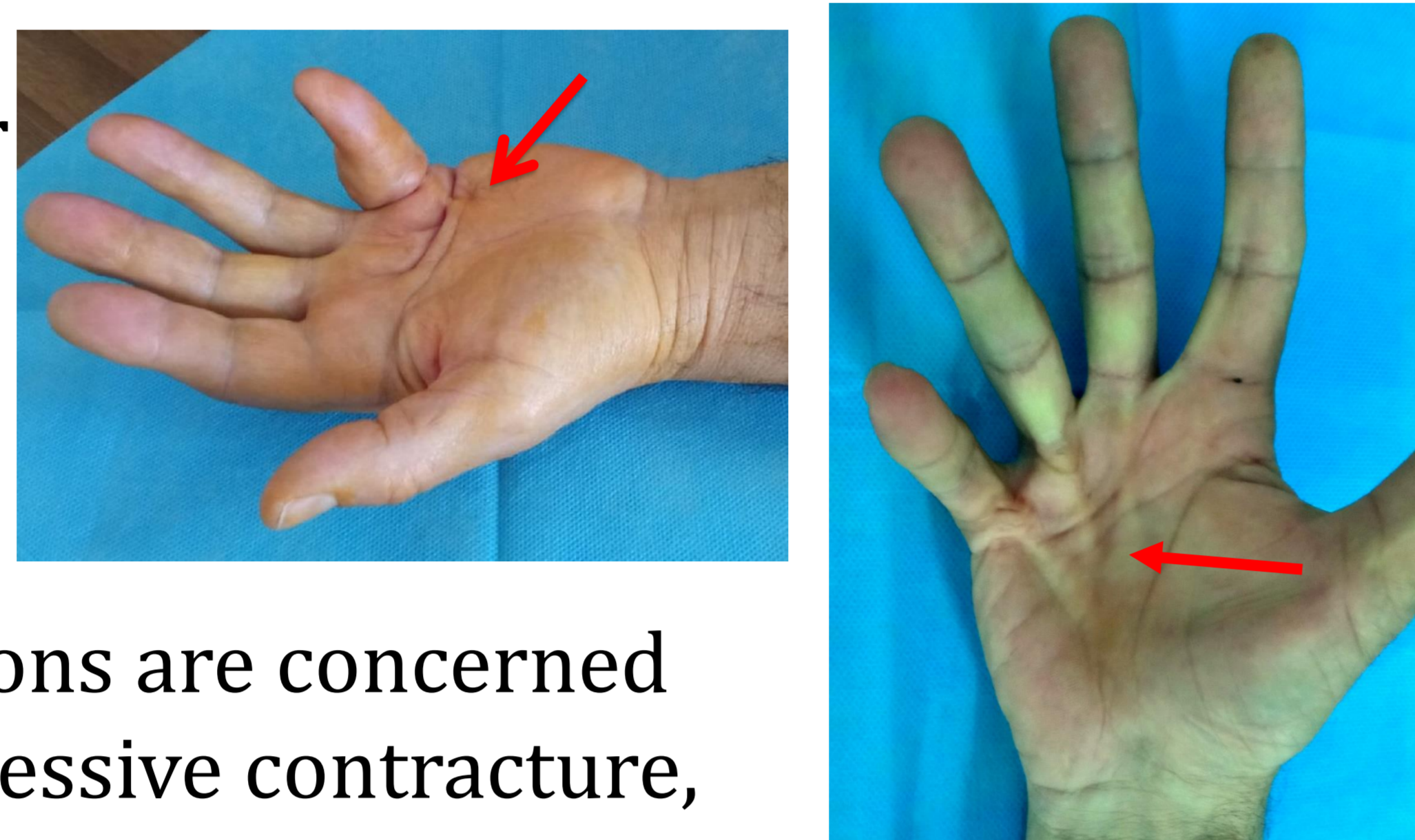


DUPUYTREN'S DISEASE – TREATMENT PARTICULARITIES

Elvira Fortuna, Alina Stoian, Viorica Mihailuța, Dumitru Buzu, Grigore Verega

Clinic of Plastic, Aesthetic Surgery and Reconstructive Microsurgery, Department of Orthopedics and Traumatology, SUMPh "Nicolae Testemitanu", Chisinau, Republic of Moldova.

Introduction. Dupuytren's contracture affects the palmar and digital fascia, leading to irreversible hand deformity. This disease increasingly plays a major role in the pathologies that plastic surgeons are concerned with. So, being a slowly progressive contracture, the treatment tactic remains decisive.



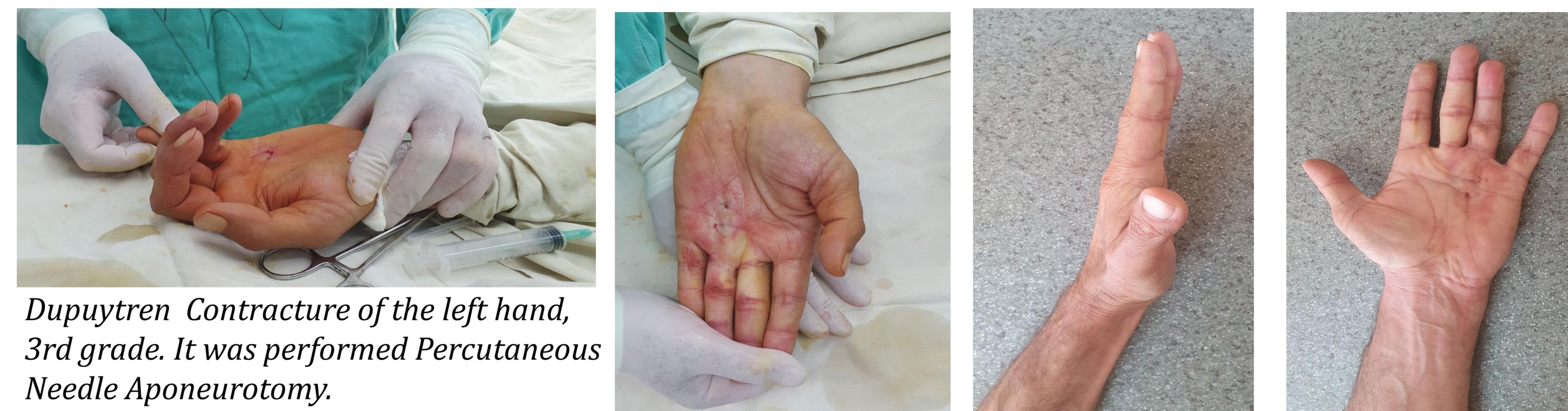Keywords. Dupuytren's disease, autodermoplasty, percutaneous needle fasciotomy, subtotal fasciectomy.

Purpose. Highlighting the peculiarities of surgical treatment in Dupuytren's disease and dilemmas faced by the surgeon, depending on the stage of the disease, to obtain a good function of the upper limb, avoiding complications and recurrences.

Material and methods. In the Clinic of Plastic, Aesthetic Surgery and Reconstructive Microsurgery, in 2010-2021, were performed surgery on 50 patients with Dupuytren's disease – percutaneous needle fasciotomy, subtotal fasciectomy, subtotal fasciectomy with autodermoplasty.

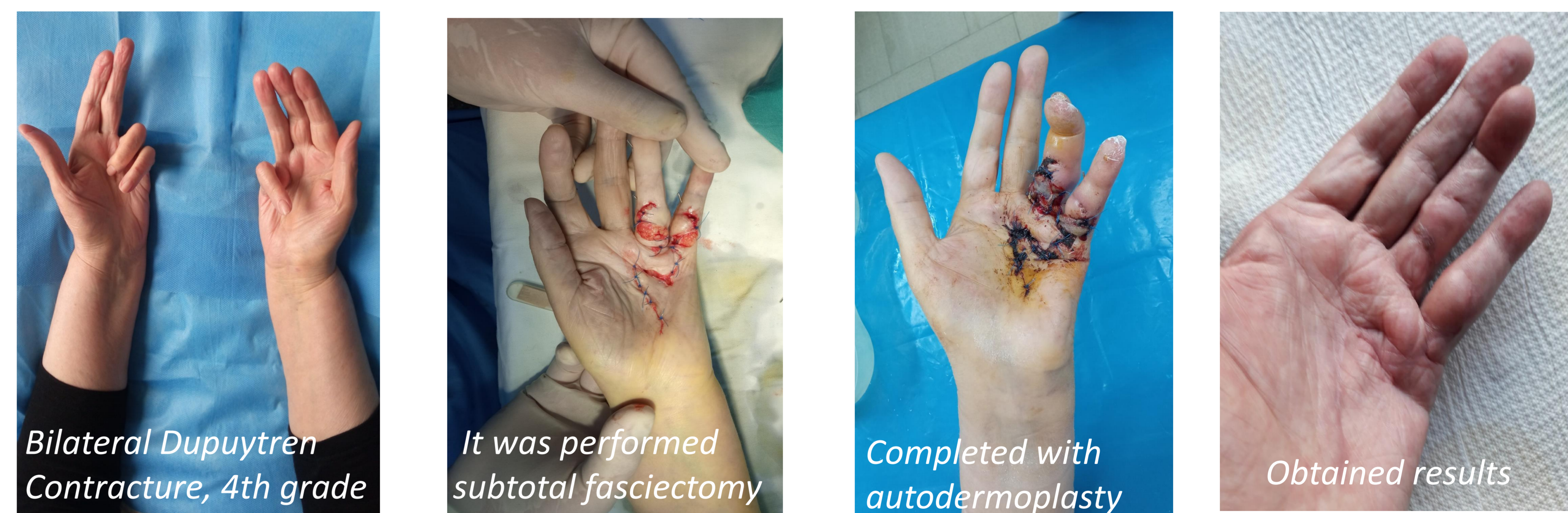
Results. Percutaneous fasciotomy is the minimally invasive method, which is applied to resolve cases that require rapid recovery, without extensive intervention. It can be performed in the initial stages of the disease (Stages I-II Tubiana).

Or can be used as the first stage of surgery, in case of advanced contractures (Stages III-IV Tubiana), which can result in skin defects.



Dupuytren Contracture of the left hand, 3rd grade. It was performed Percutaneous Needle Aponeurotomy.

Subtotal fasciectomy still remains the most common method of surgical treatment, which can be staged with autodermoplasty (in case of skin defects), with good functional results and a low number of recurrences.



Bilateral Dupuytren Contracture, 4th grade

It was performed subtotal fasciectomy

Completed with autodermoplasty

Obtained results

Conclusions. The more advanced is the stage of Dupuytren's disease and the longer is the duration of the disease, the weaker is the response to surgical treatment of the contracture and the greater is the risk of irreversible joint contracture, regardless of the choice of surgical treatment method.