

RECONSTRUCTIVE OPERATIONS OF CHILDREN WITH SERIOUS TRAUMATIC SPINE DEFORMATIONS

Shavga N.N., Shavga N.Gh.

*"Nicolae Testemitanu" State Medical and Pharmaceutical University
Chisinau, Republic of Moldova*

ABSTRACT

In Clinic of Vertebrology, Orthopedics and Traumatology of the "N.Georgiu" Scientifically - Practical Center of Children's Surgery 29 patients with spine deformations after traumatic injuries in the acute stage have been pre- and postoperatively examined with a follow-up of 1 to 5 years. Children were aged between 3 and 17 years. The main goals of surgical interventions were: elimination of the compression factor, deformation and disbalance, correction and spine stabilization. The comparative analysis of the quality of the life of patients (according to a questionnaire „EQ-5D"), before and after surgical intervention, has shown that the quality of the life of patients improved, in comparison with the preoperative period, from $12,7 \pm 0,3$ points to $7,7 \pm 0,1$. The distant results of surgical treatment were good – 85,1%, satisfactory – 11,2 % and unsatisfactory – 3,7%.

Conclusion: 1. In fresh cases of the complicated spinal - marrow trauma with mild and average degree of a neurologic symptomatology (D degree on Frenkel's scale) the preference was given to the closed, indirect decompression. At a serious neurologic symptomatology (A, B, C degree) carried out open decompression and revision of dural bag's contents; 2. Optimum method of correction the complicated spinal - marrow trauma were: forward spine release; dorsal correction and backbone fixation by a metal construction.

Key words: spine deformations; traumatic injuries; spine stabilization, children

INTRODUCTION

Traumatic spine deformations at children represent the cause that influences the main peculiarities of the spinal column: its safety and stability; initially it is manifesting by pains, statics infringements, and internals' dysfunction, subsequently it leads to severe decrease of quality of life. The choice of surgical and therapeutic options in the management of traumatic spine deformations at children is still controversial. So (for example) patients with fractures like A1 according to AO/ASIF classification don't need in surgical treatment. However, it is proved on a big clinical material [12] the fact that compression fractures like A1 with depression of forward (ventral) part of the spine on 5 mm (>5), or average more than on 3 mm at children leads to formation of kyphosis deformation. One experts recommend in urgent cases forward decompression of a spinal cord at the level of damage [2, 8, 9], but others prefer decompressing-stabilizing operations with back or back-lateral access [5, 11]. The majority of available literary references belong to studying of spine injury at adults.

Work's goal: Rising of treatment's efficiency at traumatic deformations of thoracal and lumbar spine department at children by means of development differentiated surgical tactics.

MATERIAL AND METHODS

29 patients with traumatic injuries thoracal and lumbar spine department have been pre- and

postoperatively examined with a follow-up of 1 to 5 years, in Clinic of Vertebrology, Orthopedics and Traumatology of the Scientifically - practical Center of Children's Surgery "N.Georgiu" (2008-2012). Children were aged between 3 and 17 years; they were predominantly boys – (56 %).

The evaluation included collecting of anamnesis data, clinical examination, labs and imaging (standard radiography/ with functional tests, magnetic resonance).

The type of fracture was estimated on Denis classification (1983) and AO/ASIF scale (Gertzbein S.D. 1994) extent of neurological disturbances on the scale of Frankel (1969) modified for children's age, pelvic functions JOA agrees. All patients were operating in terms from several hours to 5 weeks from the trauma moment.

Injuries of vertebrae at one level became perceptible at 21 (72,4%) patients, two and more at 8 (27,6%). The combination of spine and spinal cord injuries took place at 9 (31%) patients, damages like AIII took place at 2 patients, BI types at 2, and CIII at 5. Depth of neurological disturbances on the scale of Frankel was: A-5 (55,6%), V-2 (22,2%), S-1 (11,1%), D -1 (11,1%). Disturbances functions of pelvic organs on the scale of JOA were: 1-5(55,6) patients, 2-2 (22,2%) and 3-2(22,2%). Therapy according to the NASCIS-II protocol carried out to patients with the complicated spinal trauma from the moment of hospitalization.

The indication to operative treatment was spine instability (on F.Denis) at which there are damages of two or more backbone's colons, according to AO/

ASIF classification (Gertzbein S.D., 1994) : All-AIII (explosive fractures) – 14 (48,3%) and BI (distraction - flexion on type of "seat belts" ("seifti-belt")) – 4 (13,8%), CII-III (dislocation-fractures) – 5 (17,2%) patients. AI (compression fractures with height's depression of forward department of vertebral body more than on 5 mm ($>5^\circ$), and height's depression of average department more than on 3 mm) were observed at 6 (20,7%) patients.

The main goals of surgical interventions were: elimination of the compression factor, deformation and disbalance, correction and spine stabilization. Surgery allowed obtaining the following results:

1. Reposition (reduction) of the body of displaced vertebrae;
2. Reconstruction of forward and average spine columns;
3. Restoration of physiological spine profiles (frontal and sagittal);
4. Restoration of normal anatomy of the vertebral channel;
5. Stabilization of the spine-impellent segment.

Clinical case. Patient K., 3 years old. There is a combined trauma, the closed fracture and vertebra dislocation L1 (type C III), the bottom paraplegia (type A).

Operation: Wide laminectomy Th XII, L1, LII, vertebral channel's revision, indirect reposition; fixation by CD system.

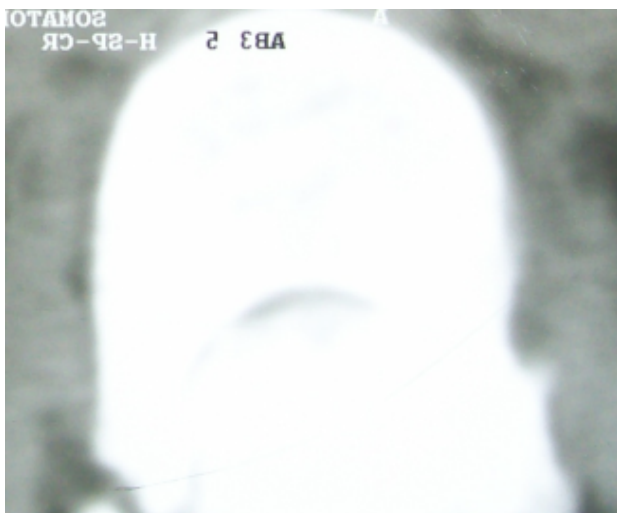


Fig 1. Before operation. L1 dislocation-fracture, symptom of a double vertebra

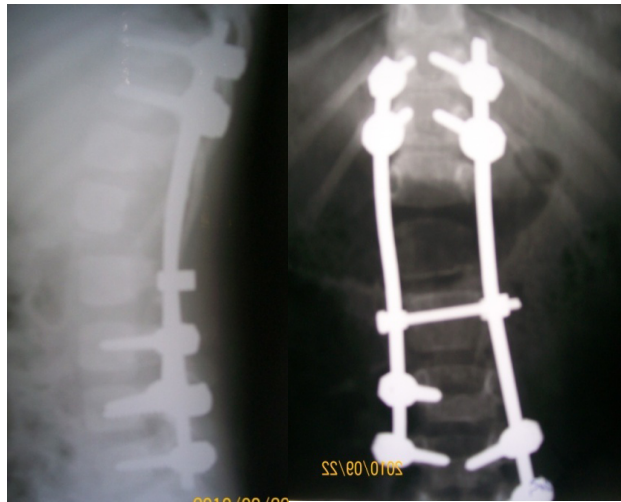


Fig. 2. After operation. In 2 years after operation neurological disturbances of type A passed to type D.

RESULTS AND DISCUSSIONS

Reposition and stabilization interventions which are combining with a partial resection of curve process of joints at seifti-belt damage were carried out for the best adaptation of back osteal structures at the reposition.

Decompressing and stabilization interventions in combination with back and lateral back autospondilodezis were carried out at patients with complicated traumas. The remote results were tracking in terms from 1 to 5 years. Local deformation (kyphosis, depression of body's height) was partially or completely eliminated. There is no negative dynamics after expeditious treatment in cases where neurological symptomatology wasn't noted. In 1 case transition of type A to type D is noted. In 8 cases of the complicated trauma there was regress of a neurological symptomatology, on 1-2 degrees on Frankel.

Questioning and medical examination in polyclinic were carried out at 28 patients. 20 patients

returned to study. Constructions are removed at 2 patients in remote period (3 years) - 1 breakage of hinge, 1 screw.

Partial loss of the reached kyphosis correction (to 20%), in cases of "short" bracing of two vertebral motive segments at 2 patients was observed. Intra-operative complications: not recognizable wrong screws carrying out (2). Early complications: sacrum decubitus (1), infection of urinary ways (1), superficial inflammation of an operational wound (1). Late complications: 3 cases of metal construction breakages, in 1 with correction loss.

For objectivity of results we used a Denis's scale (1984) for the pain and operability syndrome's assessment: at 14 (53,8%) patients - P1 degree (there is no pain), 9 (34,6%) - P2 (the infrequent weak pains which aren't demanding treatment) and at 3 (11,5%) - P3 (the average intensity, sometimes demanding applications of drugs).

CONCLUSION:

1. In fresh cases of the complicated spinal - marrow trauma with mild and average degree of a neurologic symptomatology (degree of D on Frenkel) the preference was given to the closed, indirect decompression. At a serious neurologic symptomatology (A, B, C degree) carried out open decompression and revision of dural bag's contents.

2. The early surgical intervention leads to pain syndrome's cupping, restoration of a vertebral form, elimination of the spine deformation and stabilization of the damaged segment, using *only back access*.

3. Compression fractures like A1 with depression of forward (ventral) part of the spine on 5 mm ($>5^\circ$), or average more than on 3 mm at children needs to operate for the purpose of prevention of the kyphotic deformation's formation.

REFERENCES

1. Denis F. The three columns spine and its significance in the classification of acute thoracolumbar spine injure. Spine, 1983; Vol. B: 187.
2. Denis F. Spinal stability as defined by three column spine concept in acute spinal trauma. Clin. Orthop. 1984; 189:65-70.
3. Gaines R.W. Jr. The use of pedicle-screw internal fixation for the operative treatment of spinal disorders. J. Bone Joint Surg. Am. 2000; 82-A(10):1458-76.
4. Gertzbein S.D. A comprehensive classification of thoracic and lumbar injures. Europe. Spine J. 1994; 3(4):184-201.
5. Tezercn G., Kuru I. Posterior fixation of thoracolumbar burst fracture: short-segment pedicle fixation versus longsegment instrumentation. J. Spinal Disord. Tech. 2005; 18(6):485-8.
6. Tropiano P. Functional and radiographic outcomes of thoracolumbar and lumbar burst fractures managed by closed orthopaedic reduction and casting. Spine. 2003; 28:2459-65.
7. Verlaan, J. J. Surgical treatment of traumatic fractures of thoracic and lumbar spine: a systematic review of the literature on techniques, complications and outcomes. Spine. 2004; 29: 803-14.
8. Wang, S. T. Is fusion necessary for surgical treated burst fractures of the thoracolumbar and lumbar spine? Spine. 2006; 31(23):2646-52.
9. Wu J.C., Tang C.T., Wu D.L., Tsai T.H., Chiang Y.H. Treatment of adjacent vertebral fractures following multiple-level spinal fusion. Acta Neurochir. Suppl. 2008; 101:153-5.
10. Șavga N. (jr.), Șavga N., Carlic S., Opinca V., Moraru A. Leziuni vertebrale a segmentului dorsal și lombar la copil. În: Anale științifice. Universitatea de Stat de Medicină și Farmacie „Nicolae Testemițanu” din Republica Moldova. Chișinău. 2012; Ed. XII. 5:227-32.
11. Гайдар Б.В. Хирургическое лечение пациентов с повреждениями позвоночника грудной и поясничной локализации. Хирургия позвоночника. 2004; 3:40-5.
12. Ульрих Э.В., Мушкин А.Ю. Вертебрология в терминах, цифрах, рисунках. СПб. ЭЛБИ-СПб. 2002: 187 с.