

SURGICAL INTERVENTION SPECIFICS OF RESECTION OF EXTREMITY SOFT TISSUE SARCOMAS IN CHILDREN

(Review of literature)

**Tsilenko K.S., Rumyantsev A.G., Bataev S.M., Ignatiev R.O.,
Shakhgildyan L.D., Tuzova M.N., Kononov D.M.**

Speransky Children's Clinical Hospital, Moscow, Russian Federation

The integrated approach in the treatment of soft tissue sarcomas in children and adolescents at various stages includes conservative methods and tactics of surgical removal of neoplasms.

The main tasks of the surgical stage of treatment are to remove the tumor in a single block without damaging it, to ensure maximum functionality of the affected organ and to prevent local recurrence. However, in connection with the need for radical tumor removal, significant tissue defects requiring reconstructive manipulation are often formed during surgery. Determining a sufficient resection width is an important aspect of ensuring adequate volume of surgical intervention.

According to the literature, over 300 histological types of soft tissue sarcoma have been described. These tumors are of mesodermal and less often neuroectodermal origin, and are localized in different parts of the body. The morphological classification developed by WHO experts comprises 15 types of tumor process in terms of histogenesis. According to statistics, among all bone and soft tissue tumors, malignant neoplasms in the foot and ankle region account for about 4% of cases [1]. Soft tissue sarcomas are rare tumors and in most cases are localized in the extremity region [1].

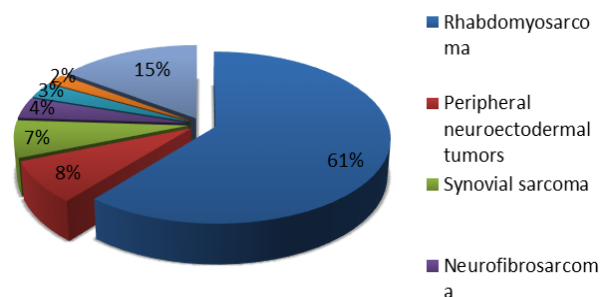
These neoplasms are represented by a heterogeneous group of malignant tumors that are created from primitive mesenchymal tissues and account for 7% of all childhood tumors [2].

According to statistics, among all bone and soft tissue tumors, malignant neoplasms in the foot and ankle region account for about 4% of cases [1]. Soft tissue sarcomas are rare tumors and in most cases are localized in the extremity region [1]. These neoplasms are represented by a heterogeneous group of malignant tumors that are created from primitive mesenchymal tissues and account for 7% of all childhood tumors [2].

Table 1. Histogenetic classification of soft tissue sarcomas

Tissue type	Tumor type
Mesenchyme	Malignant mesenchymoma
	Myxoma
Fibrous tissue	Desmoid (invasive form)
	Fibrosarcoma
Adipose tissue	Liposarcoma
Vascular tissue	Malignant hemangioendothelioma
	Malignant hemangiopericytoma
	Malignant lymphangiosarcoma
Muscle tissue	Rhabdomyosarcoma (from striated muscles)
	Leiomyosarcoma (from smooth muscles)
Synovial tissue	Synovial sarcoma
Nerve sheaths	Malignant neurinoma (schwannoma) – from neuroectodermal membranes
	Perineural fibrosarcoma – from connective tissue membranes

Diagram 1. Distribution of histological variants of soft tissue sarcomas by frequency of occurrence in children



Rhabdomyosarcoma is a tumor of the striated muscles. It is the most common soft tissue sarcoma in children aged 0 to 14 years and comprises 50% of all tumors in this age group [3]. The remaining soft tissue sarcomas in children account for approximately 3% of the total number of soft tissue sarcomas [4], and include neoplasms of: connective tissue (e.g. desmoid fibromatosis), peripheral nervous system (e.g. malignant tumors of peripheral nerve sheaths), smooth muscle (e.g. leiomyosarcoma), vascular tissue (blood and lymphatic vessels, e.g. angiosarcoma) [5].

Non-rhabdoid soft tissue sarcomas are more common in adolescents and adults [5]. Most of the information on the treatment of young patients was based on the tactics of conducting adult patients. Such soft tissue sarcomas can develop in any part of the body, but more often occur in the extremities and upper body [6-8] and are rarely localized in the brain [9]. The clinical presentation can be asymptomatic or, for example, with the involvement of nerve structures in the process, accompanied by pain syndrome. Systemic symptoms in the form of fever, weight loss, increased night sweats are practically not found [10].

From the point of view of the histological picture, rhabdomyosarcoma and Ewing sarcoma can be easily distinguished from other sarcomas. However, other soft tissue sarcomas are more difficult to differentiate. To make an accurate diagnosis, a biopsy is necessary. The use of fine needle biopsy is not desirable in view of the low informative nature of the sample. An open biopsy is crucial for the complete histological characterization of the sample, for performing immunohistochemical, cytogenetic analysis, fluorescence [11, 12], cryoconservation in biobanks, etc. Longitudinal sections are used on the extremities for surgical access, which allows to a greater extent to preserve the skin and to reduce the irradiation zone. The use of trepanobiopsy may be accompanied by the formation of a hematoma, which complicates the subsequent resection of the tumor. To plan an informative biopsy of the affected area, ultrasound diagnosis, CT, or MRT studies are needed [13]. Excisional biopsy is suitable only for small superficial neoplasms (<3 cm in diameter) and is not standard [14, 15]. Execution of excisional biopsy is associated with a greater risk of non-radical surgery. Further, on the background of chemoradiotherapy, it is difficult to distinguish scar tissue from a possible residual tumor. Therefore, in the beginning it is advisable to perform a nonexcisional biopsy, to conduct further therapy followed by a radical operation. The criteria for successful treatment are the histological form, the size and location of the neoplasm, the degree of malignancy, the presence of local and distant metastases, the stage of the disease, the response to polychemotherapy and radiation therapy. Treatment of soft tissue sarcomas is poorly effective without a surgical stage. The ability to perform complete neoplasm resection is the most

important prognostic factor for survival [16-24].

The interrelation between the resection margin and the recurrence of the disease is an important issue in oncology surgery. Despite a large number of scientific developments in this direction, at present there are no clear criteria for estimating the sufficient resection width [25].

Children with an unplanned resection of non-rhabdomyosarcoma soft tissue sarcoma need a re-excision of the postoperative cicatrix. In such patients, tumor cells are often found in scar tissue, since initially it is fairly difficult to remove a tumor radically, and unplanned resection is associated with suspected benign neoplasm and is performed without taking into account the possible malignancy of the process [26, 27]. In the research by Qureshi Y.A. et al. the retrospective analysis showed that an unplanned initial excision of soft tissue sarcoma leads to an increased risk of local recurrence, metastasis and fatal case. For tumors of a high degree of malignancy, these parameters were the highest [28]. For some types of children's nonrhabdomyosarcoma soft tissue sarcomas, the prognosis is more favorable. For example, infantile fibrosarcoma, which is most often found in infants and children under the age of 5, has a good prognosis, is sensitive to polychemotherapy, and as a rule, is resectable [4].

Children with localized unresectable forms of nonrhabdomyosarcoma soft tissue sarcoma have an unfavorable outcome. Only about one third of patients who receive therapy regain their health [29-32].

In the analysis of American and European centers, it was established that those patients, whose planned removal of soft tissue sarcoma was performed fully, have better survival rates compared to patients who underwent non-radical resection. The best results were noted in cases where radiotherapy was also performed [31]. Therefore, each patient needs an individual approach. Therapy planning should be carried out before the start of treatment [7, 33-37].

The tasks of surgical treatment of extremity soft tissue sarcomas are to remove the tumor in a single block, to prevent local recurrence, and to provide maximum functionality [38].

Over the past decades, approaches to treating sarcomas have undergone significant changes, primary amputations are increasingly being replaced by organ preservation surgeries [39]. But in cases where central vessels and nerves are involved in the tumor process, or there is severe bleeding from the tumor tissue, which can not be stopped conservatively, amputation remains the only correct treatment option [40]. When resecting soft tissue sarcomas with damage to bone structures, modern methods of prosthetics help to achieve good functional results.

Peripheral nerves, as a rule, are not involved in the tumor process or are easily isolated with preservation of the nerve sheaths. In cases where the nerve

is diseased, it is necessary to resect it altogether with the tumor in a single block. In adult patients, neural grafts often do not function, which is probably related to age, but can be successfully used in children. In complete resection of the sciatic nerve, the extremity functionality is preserved [41]. In the postoperative period, due to the risk of decubitus formation, knee orthoses should be used with caution, among other things because of the reduced sensitivity of the extremity [42].

If possible, it is necessary to avoid removing the periosteum, especially in the femur, since its excision with subsequent radiation therapy increases the risk of pathological fractures [43]. The periosteum should be resected in cases where it is likely to be involved in the tumor process. In this case, the area of bone resection is recommended to be fixated [44], however, there is no reliable data on the stabilization efficiency in this case [45, 46]. The frequency of occurrence of pathological fractures in such patients is extremely small and is associated with the dose of radiation therapy, most often they occur in the femur [47]. In some cases, bone fixation may be supplemented with a pedicled fibular graft [48].

In successful surgical treatment of patients an important point is a wide excision of the primary tumor (of the whole block without damage to the tumor, with sufficient margin of healthy tissue). Resection should be performed outside the pseudocapsule of the tumor, through normal unaffected tissue. Intraoperative damage to the tumor structure (i.e., intralesional surgery or resection) leads to an increase in the frequency of local recurrences [38].

The presence of tumor cells in the resection margin also affects the frequency of local recurrences [38, 49-55], increases the risk of distant metastases, and decreases survival rates [54, 56]. The resection margin is positive if the tumor cells are histologically determined in the edge of the tissue being resected. For intraoperative evaluation it is reasonable to use express histological diagnostics, which reduces the risk of non-radical surgery. Its technique is a removal of the tumor, followed by a small resection of surrounding tissues and their urgent histological evaluation.

In case of patients with non-radical resection, if possible, it is necessary to perform a resection with complete excision of the remaining tumor edges [57]. It is necessary to take into account the volumes of repeated surgery, the possibility of traumatizing the neurovascular structures, and also the fact that in patients with R1 resection, the frequency of local recurrences was 30% greater as compared to R0 resection, where the frequency of local recurrences was 5-10% [58, 59].

When a tumor is resected, healthy tissue should encircle the pathological area. The required thickness of the resected noninvolved tissue remains debatable. According to literature data, it is recommended to remove at least 1 cm margin from the

tumor edge or the resection margin should include a fascial barrier [52, 60]. In practice, it is not always possible to remove a tumor with a margin of 1 cm, especially when large vessels are involved in the tumor process [60]. A combination of reconstructive surgery and adjuvant radiotherapy helps to achieve good results, which is associated with a good tumor sensitivity to radiation therapy [61, 63, 64]. Tumors of high degree of malignancy are the ones most prone to local recurrence [62, 63, 64], which reasonably worsens the prognosis of the disease.

In patients with locally advanced form of extremity soft tissue sarcoma, it is advisable to use isolated chemotherapeutic perfusion. Performing this procedure with the use of alpha-tumor necrosis factor allows to preserve the extremity in 81% of cases [65].

In the study by Kandel R. et al. it was shown that the size of the surgical margin from the tumor edge does not significantly affect the overall survival of patients [39]. From the point of view of the operating surgeon, it is safer to make a sufficient margin, but in some cases the possibility of maintaining the functionality of the operated region is possible only with a microscopic margin from the tumor border that is confirmed by express histological diagnostics. Despite a large number of scientific developments, at present there are no clear criteria for assessing the sufficient width of the resection.

However, major surgery with a wide surgical margin, which is accompanied by significant defects in soft and bone tissues, is often appropriate for patients with locally advanced form of extremity soft tissue sarcoma. The use of plastic reconstructive surgery techniques, for example, closure of defects with a local advanced flap, free fasciocutaneous flap, musculocutaneous flap, osteocutaneous flap or split-skin grafts can reduce functional disorders even with large resection volumes or in cases of tumor localization in close proximity to anatomically important structures, which is accompanied by a significant improvement in the quality of life of such patients.

For plastic surgery, the defects that arise after extensive resection of the neoplasms, notably in the back and side surfaces of the foot, are of particular complexity. This is due to the anatomical features of this area and the direct participation of the foot in the movement of the body and the wearing of shoes [66-69]. One of the common options for closing such defects is the use of a local advanced flap. It is possible to use a free split-skin graft, however, during walking in the postoperative period this tissue, as a rule, does not withstand a significant load. The cosmetic result and innervation in the area of the transplanted graft are also impaired, the intraoperative interval time increases. The technique of performing a local advanced flap requires special skills which not all children's surgeons possess [70].

For resections larger than 3 cm² and without involvement of bone structures in the tumor process, it is practical to use a free fasciocutaneous or musculo-

cutaneous flap, as well as to close defects with local tissues. When bone tissue is involved in the tumor process, it is also possible to perform replacement of defects with free flaps, including osteocutaneous grafts. Defects of large sizes can be closed in several stages of reconstructive surgeries [71, 72].

The use of plastic surgery techniques to close large defects in the area of the distant neoplasm allows rapid healing of the surgical wounds and recovery of the patient in the postoperative period, provided that sufficient blood supply to the tissues is preserved, which increases the effectiveness of treatment due to the timely delivery of adjuvant radiation and/or chemotherapy.

The use of the fasciocutaneous sural flap has positively proved itself for the closure of defects in the heel and ankle area due to its plasticity and good blood supply [73-76]. The inflow of blood to this flap is due to the artery of calf, which, descending between the heads of gastrocnemius muscle, is a continuation of the popliteal artery. It is accompanied by veins and medial sural cutaneous nerve, which branches from the tibial nerve. Its formation should be started at least 5 cm proximal of the lateral malleolus, which is a favorable condition for preserving adequate anastomosis of the flap with the peroneal artery [77-79]. Mendieta et al. report on the successful recovery of sensitivity in the sural flap due to the connection of the transected nerve of the graft with the cutaneous branch of the superficial fibular nerve [80]. Tan et al. report on a series of such successful reconstructions of nerves with the preservation of the overall viability of the sural flap [81]. These works are of particular interest from the point of view of restoring the sensitivity of the flap, especially in cases of large resection volumes, and require further observation. A medial plantar flap is used to close small defects of the foot soft tissues with the preservation of innervation of the graft [82, 83].

Special attention should be paid to rotational axial pedicled flaps with the ability to rotate the graft from 90 to 180 degrees. Dong et al. reported on similar successful operations in 20 patients with extensive defects in the shin and foot area. All the flaps remained viable, the size of soft tissue defects ranged from 2 x 8 cm to 10 x 20 cm. In 12 patients the places of graft harvesting were closed with local tissues, in 8 cases a split cutaneous thigh flap was used [84]. In some cases free microvascular grafts may be used to close large volumes of resection, for example, a fasciocutaneous flap from the anterolateral surface of the thigh or from the parascapular area, as well as a flap from the latissimus dorsi with or without a cutaneous area. After taking the

flap from the anterolateral surface of the thigh, depending on the age and volume of the thigh, with a flap width of up to 10 cm, it is possible to close the defect with local tissues, whereas in case of larger grafts the defects should be closed with split-skin grafts. If it is necessary to use a free graft to close a foot defect, preference should be given to the flap from the front surface of the thigh, which is connected with a more favorable functional and cosmetic result due to the well-developed subcutaneous fat, as compared to the flap from the parascapular area. The blood supply of the parascapular fasciocutaneous flap occurs due to the branches of the arteria circumflexa scapulae emerging from the triangular space between major and minor teres muscles and the long head of the triceps muscle of arm. Depending on the age and body surface area of the child, the flap width can vary up to 12 cm wide and 25 cm long, which allows closing the defect of the donor wound with local tissues [85-87].

While using locally advanced flaps, there is a probability of spreading the tumor process to the graft harvesting area due to possible contamination of healthy tissues by tumor cells [88], however, according to the literature, such cases are isolated, and the positive effect of plastic reconstructive surgery significantly exceeds the possible risks [89]. The advantage of closing defects with local tissues is also the absence of the need for intensive postoperative control of the flap. In such cases postoperative therapy, in particular the use of anticoagulants, may be more sparing. In other situations the advancement of local flaps can be technically a more complex and risky manipulation as compared to using a free microvascular flap, the practice technique of which has become more accessible and significantly simplified thanks to modern technologies [1].

In some cases a more detailed preoperative planning of the operation with a clear assessment of the width of resection margins is necessary. The base of the defects after removal of neoplasms can be tendons and articular surfaces, which significantly worsens wound healing, leading to delayed radiation or chemotherapy. In this situation it is necessary to apply a combination of plastic reconstructive surgery methods to close the surgical defect and to prevent infection of the wound and nearby structures - tendons, bones, and muscle tissue. The use of a free microvascular flap pertains to high-tech medical care; despite the more sophisticated technique of execution, this variant of reconstruction can be considered the only correct tactic for a particular patient.

REFERENCES

1. Ring A., Kirchoff P., Goertz O. et al. Reconstruction of Soft-Tissue Defects at the Foot and Ankle after Oncological Resection. *Front. Surg.* 2016; 3:15.
2. Pappo A.S., Pratt C.B.: Soft tissue sarcomas in children. *Cancer Treat. Res.* 1997; 205:22.
3. Ries L.A., Smith M.A., Gurney J.G. et al. Cancer incidence and survival among children and adolescents: United States SEER Program 1975-1995. Bethesda, Md: National Cancer Institute, SEER Program, 1999. NIH Pub. No. 99-4649.
4. Spunt S.L., Million L., Coffin C. The nonrhabdomyosarcoma soft tissue sarcoma. *Principles and Practice of Pediatric Oncology*. 7th ed. Philadelphia, Pa: Lippincott Williams and Wilkins 2015; 827:54.
5. Weiss S.W., Goldblum J.R. General considerations. *Enzinger and Weiss's Soft Tissue Tumors*. 5th ed. St. Louis, Mo: Mosby. 2008; 1:14.
6. Dillon P., Maurer H., Jenkins J. et al. A prospective study of nonrhabdomyosarcoma soft tissue sarcomas in the pediatric age group. *J. Pediatr. Surg.* 1992; 241:4.
7. Rao B.N. Nonrhabdomyosarcoma in children: prognostic factors influencing survival. *Semin. Surg. Oncol.* 1993; 524:31.
8. Zeytoonjian T., Mankin H.J., Gebhardt M.C. et al. Distal lower extremity sarcomas: frequency of occurrence and patient survival rate. *Foot Ankle.* 2004; 325:30.
9. Benesch M., Bueren A.O., Dantonello T. et al. Primary intracranial soft tissue sarcoma in children and adolescents: a cooperative analysis of the European CWS and HIT study groups. *J Neurooncol* 2013; 337:45.
10. Weiss S.W., Goldblum J.R. Miscellaneous tumors of intermediate malignancy. *Enzinger and Weiss's Soft Tissue Tumors*. 5th ed. St. Louis, Mo: Mosby. 2008; 1093:1160.
11. Weiss S.W., Goldblum J.R. *Enzinger and Weiss's Soft Tissue Tumors*. 4th ed. St. Louis, Mo: Mosby. 2001.
12. Recommendations for the reporting of soft tissue sarcomas. *Association of Directors of Anatomic and Surgical Pathology. Mod. Pathol.* 1998; 1257:61.
13. Chowdhury T., Barnacle A., Haque S., et al. Ultrasound-guided core needle biopsy for the diagnosis of rhabdomyosarcoma in childhood. *Pediatr. Blood Cancer.* 2009; 356:60.
14. Coffin C.M., Dehner L.P., O'Shea P.A. *Pediatric Soft Tissue Tumors: A Clinical, Pathological, and Therapeutic Approach*. Baltimore, Md: Williams and Wilkins. 1997.
15. Smith L.M., Watterson J., Scott S.M. *Pediatric Soft Tissue Tumors: A Clinical, Pathological, and Therapeutic Approach*. Baltimore, Md: Williams and Wilkins. 1997; 360:71.
16. Stoeckle E., Coindre J.M., Bonvalot S. et al. Prognostic factors in retroperitoneal sarcoma: a multivariate analysis of a series of 165 patients of the French Cancer Center Federation Sarcoma Group. *Cancer.* 2001; 92:359.
17. Lewis J.J., Leung D., Woodruff J.M., Brennan M.F. Retroperitoneal soft tissue sarcoma: analysis of 500 patients treated and followed at a single institution. *Ann. Surg.* 1998; 228:355.
18. Storm F.K., Mahvi D.M. Diagnosis and management of retroperitoneal soft tissue sarcoma. *Ann. Surg.* 1991; 214:2.
19. Hassan I., Park S.Z., Donohue J.H. et al. Operative management of primary retroperitoneal sarcomas: a reappraisal of an institutional experience. *Ann. Surg.* 2004; 239:244.
20. Catton C.N., O'Sullivan B., Kotwall C. et al. Outcome and prognosis in retroperitoneal soft tissue sarcoma. *Int. J. Radiat. Oncol. Biol. Phys.* 1994; 29:1005.
21. Lehnert T., Cardona S., Hinz U. et al. Primary and locally recurrent retroperitoneal soft tissue sarcoma: local control and survival. *Eur. J. Surg. Oncol.* 2009; 35:986.
22. Anaya D.A., Lev D.C., Pollock R.E. The role of surgical margin status in retroperitoneal sarcoma. *J. Surg. Oncol.* 2008; 98:607.
23. Pierie J.P., Betensky R.A., Choudry U. et al. Outcomes in a series of 103 retroperitoneal sarcomas. *Eur J Surg Oncol* 2006; 32:1235.
24. Avances C., Mottet N., Mahatmat A. et al. Prognostic factors for first recurrence in patients with retroperitoneal sarcoma. *Urol. Oncol.* 2006; 24:94.
25. Stoeckle E., Italiano A., Stock N., Kind M., Kantor G., Coindre J.M., Bui B.N. Surgical margins in soft tissue sarcoma. *Bull. Cancer.* 2008; 95:12.
26. Chui C.H., Spunt S.L., Liu T. et al. Is reexcision in pediatric nonrhabdomyosarcoma soft tissue sarcoma necessary after an initial unplanned resection? *J. Pediatr. Surg.* 2002; 1424:9.
27. Cecchetto G., Guglielmi M., Inserra A. et al. Primary re-excision: the Italian experience in patients with localized soft-tissue sarcomas. *Pediatr. Surg. Int.* 2001; 532:4.
28. Qureshi Y.A., Huddy J.R., Miller J.D. et al. Unplanned excision of soft tissue sarcoma results in increased rates of local recurrence despite full further oncological treatment. *Ann. Surg. Oncol.* 2012; 871:7.
29. Spunt S.L., Hill D.A., Motosue A.M. et al. Clinical features and outcome of initially unresected nonmetastatic pediatric nonrhabdomyosarcoma soft tissue sarcoma. *J. Clin. Oncol.* 2002; 3225:35.
30. O'Sullivan B., Davis A.M., Turcotte R. et al. Preoperative versus postoperative radiotherapy in soft-tissue sarcoma of the limbs: a randomised trial. *Lancet.* 2002; 2235:41.
31. Ferrari A., Miceli R., Rey A. et al. Non-metastatic unresected paediatric non-rhabdomyosarcoma soft tissue sarcomas: results of a pooled analysis from United States and European groups. *Eur. J. Cancer.* 2011; 724:31.
32. Smith K.B., Indelicato D.J., Knapik J.A. et al. Definitive radiotherapy for unresectable pediatric and young adult nonrhabdomyosarcoma soft tissue sarcoma. *Pediatr. Blood Cancer.* 2011; 247:51.
33. Dillon P.W., Whalen T.V., Azizkhan R.G. et al. Neonatal soft tissue sarcomas: the influence of pathology on treatment and survival. *Children's Cancer Group Surgical Committee. J. Pediatr. Surg.* 1995; 1038:41.
34. Pappo A.S., Fontanesi J., Luo X. et al. Synovial sarcoma in children and adolescents: the St Jude Children's Research Hospital experience. *J. Clin. Oncol.* 1994; 2360:6.
35. Marcus K.C., Grier H.E., Shamberger R.C. et al. Childhood soft tissue sarcoma: a 20-year experience. *J. Pediatr.* 1997; 603:7.

36. Pratt C.B., Pappo A.S., Gieser P. et al. Role of adjuvant chemotherapy in the treatment of surgically resected pediatric nonrhabdomyosarcomatous soft tissue sarcomas: A Pediatric Oncology Group Study. *J. Clin. Oncol.* 1999; 4:1219.
37. Pratt C.B., Maurer H.M., Gieser P. et al.: Treatment of unresectable or metastatic pediatric soft tissue sarcomas with surgery, irradiation, and chemotherapy: a Pediatric Oncology Group study. *Med. Pediatr. Oncol.* 1998; 201:9.
38. Tanabe K.K., Pollock R.E., Ellis L.M. et al. Influence of surgical margins on outcome in patients with preoperatively irradiated extremity soft tissue sarcomas. *Cancer.* 1994; 73:1652.
39. Kandel R., Coakley N., Werier J. et al. Surgical margins and handling of soft-tissue sarcoma in extremities: a clinical practice guideline. *Curr. Oncol.* 2013; 20(3):247-54.
40. Steinau H.U., Steinstrasser L., Hauser J. et al. Soft tissue sarcoma. Resection and plastic reconstruction. *Orthopade.* 2012; 41(2):165-75.
41. Brooks A.D., Gold J.S., Graham D. et al. Resection of the sciatic, peroneal, or tibial nerves: assessment of functional status. *Ann. Surg. Oncol.* 2002; 9:41.
42. Ghert M.A., Davis A.M., Griffin A.M. et al. The surgical and functional outcome of limb salvage surgery with vascular reconstruction for soft tissue sarcoma of the extremity. *Ann. Surg. Oncol.* 2005; 12:1102.
43. Gortzak Y., Lockwood G.A., Mahendra A. et al. Prediction of pathologic fracture risk of the femur after combined modality treatment of soft tissue sarcoma of the thigh. *Cancer.* 2010; 116:1553.
44. Pak D., Vineberg K.A., Griffith K.A. et al. Dose-effect relationships for femoral fractures after multimodality limb-sparing therapy of soft tissue sarcomas of the proximal lower extremity. *Int. J. Radiat. Oncol. Biol. Phys.* 2012; 83:1257.
45. Cannon C.P., Ballo M.T., Zagars G.K. et al. Complications of combined modality treatment of primary lower extremity soft tissue sarcomas. *Cancer.* 2006; 107:2455.
46. Holt G.E., Griffin A.M., Pintilie M. et al. Fractures following radiotherapy and limb salvage surgery for lower extremity soft tissue sarcomas. A comparison of high dose and low dose radiotherapy. *J. Bone Joint Surg. Am.* 2005; 87:315.
47. Dickie C.I., Parent A.L., Griffin A.M. et al. Bone fractures following external beam radiotherapy and limb preservation surgery for lower extremity soft tissue sarcoma: relationship to irradiated bone length, volume, tumor location and dose. *Int. J. Radiat. Oncol. Biol. Phys.* 2009; 75:1119.
48. Duffy G.P., Wood M.B., Rock M.G., Sim F.H. Vascularized free fibular transfer combined with autografting for the management of fracture nonunions associated with radiation therapy. *J. Bone Joint Surg. Am.* 2000; 82:544.
49. Pisters P.W., Leung D.H., Woodruff J. et al. Analysis of prognostic factors in 1,041 patients with localized soft tissue sarcomas of the extremities. *J. Clin. Oncol.* 1996; 14:1679.
50. Williard W.C., Hajdu S.I., Casper E.S., Brennan M.F. Comparison of amputation with limb-sparing operations for adult soft tissue sarcoma of the extremity. *Ann. Surg.* 1992; 215:269.
51. LeVay J., O'Sullivan B., Catton C. et al. Outcome and prognostic factors in soft tissue sarcoma in the adult. *Int. J. Radiat. Oncol. Biol. Phys.* 1993; 27:1091.
52. Sadoski C., Suit H.D., Rosenberg A. et al. Preoperative radiation, surgical margins, and local control of extremity sarcomas of soft tissues. *J. Surg. Oncol.* 1993; 52:223.
53. Herbert S.H., Corn B.W., Solin L.J. et al. Limb-preserving treatment for soft tissue sarcomas of the extremities. The significance of surgical margins. *Cancer.* 1993; 72:1230.
54. Trovik C.S., Bauer H.C., Alvegård T.A. et al. Surgical margins, local recurrence and metastasis in soft tissue sarcomas: 559 surgically treated patients from the Scandinavian Sarcoma Group Register. *Eur. J. Cancer.* 2000; 36:710.
55. Zagars G.K., Ballo M.T., Pisters P.W. et al. Prognostic factors for patients with localized soft tissue sarcoma treated with conservation surgery and radiation therapy: an analysis of 1225 patients. *Cancer.* 2003; 97:2530.
56. Gronchi A., Lo Vullo S., Colombo C. et al. Extremity soft tissue sarcoma in a series of patients treated at a single institution: local control directly impacts survival. *Ann. Surg.* 2010; 251:506.
57. Verhey L.J. Comparison of three-dimensional conformal radiation therapy and intensity modulated radiation therapy systems. *Semin. Radiat. Oncol.* 1999; 9:78.
58. Pan E., Goldberg S.I., Chen Y.L., et al. Role of postoperative radiation boost for soft tissue sarcomas with positive margins following preoperative radiation and surgery. *J. Surg. Oncol.* 2014; 110:817.
59. Kepka L., Suit H.D., Goldberg S.I. et al. Results of radiation therapy performed after unplanned surgery (without reexcision) for soft tissue sarcomas. *J. Surg. Oncol.* 2005; 92:39.
60. Eilber F.R., Eckardt J. Surgical management of soft tissue sarcomas. *Semin. Oncol.* 1997; 24:526.
61. Potter B.K., Hwang P.F., Forsberg J.A. et al. Impact of margin status and local recurrence on soft-tissue sarcoma outcomes. *J. Bone Joint Surg. Am.* 2013; 95(20):1511-8.
62. Kasper B., Ouali M., van Glabbeke M. et al. Prognostic factors in adolescents and young adults (AYA) with high risk soft tissue sarcoma (STS) treated by adjuvant chemotherapy: a study based on pooled European Organisation for Research and Treatment of Cancer (EORTC) clinical trials 62771 and 62931. *Eur. J. Cancer.* 2013; 49(2):449-56.
63. Daigeler A., Harati K., Goertz O. et al. Prognostic factors and surgical tactics in patients with locally recurrent soft tissue sarcomas. *Handchir. Mikrochir. Plast. Chir.* 2015; 47(2):118-27.
64. Daigeler A., Zmarsly I., Hirsch T. et al. Long-term outcome after local recurrence of soft tissue sarcoma: a retrospective analysis of factors predictive of survival in 135 patients with locally recurrent soft tissue sarcoma. *Brit. J. Cancer.* 2014; 110(6):1456-64.
65. Deroose J.P., Grunhagen D.J., de Wilt J.H. et al. Treatment modifications in tumour necrosis factor-alpha (TNF)-based isolated limb perfusion in patients with advanced extremity soft tissue sarcomas. *Eur. J. Cancer.* 2015; 51(3):367-73.
66. Wang T., Lin J., Song D., Zheng H., Hou C., Li L., Wu Z. Anatomical basis and design of the distally based lateral dorsal cutaneous neuro-lateral plantar venofasciocutaneous flap pedicled with the lateral plantar artery perforator of the fifth metatarsal bone: a cadaveric dissection. *Surg. Radiol. Anat.* 2016; 10(7):1712-16.
67. Li L., Song D., Zheng H., Hou C., Lin J., Xie Z., Zhuang Y. Anatomical basis of the reverse lateral plantar artery perforator flap design. *Surg. Radiol. Anat.* 2015; 37:983-88.

68. Song D., Yang X., Wu Z., Li L., Wang T., Zheng H., Hou C. Anatomic basis and clinical application of the distally based medialis pedis flaps. *Surg. Radiol. Anat.* 2016; 38:213-21.
69. Wu Z., Song D., Lin J., Zheng H., Hou C., Li L., Wang T. Anatomic basis of the distally based venocutaneous flap on the medial plantar artery of the hallux with medial plantar vein and nutrient vessels: a cadaveric dissection. *Surg. Radiol. Anat.* 2015; 37:975-81.
70. Noever G., Bruser P., Kohler L. Reconstruction of heel and sole defects by free flaps. *Plast. Reconstr. Surg.* 1986; 78:345-52.
71. Hidalgo D.A., Shaw W.W. Anatomic basis of plantar flap design. *Plast. Reconstr. Surg.* 1986; 78(5):627-36.
72. Hidalgo D.A., Shaw W.W. Reconstruction of foot injuries. *Clin. Plast. Surg.* 1986; 13(4):663-80.
73. Chang S.M., Li X.H., Gu Y.D. Distally based perforator sural flaps for foot and ankle reconstruction. *World J. Orthop.* 2015; 6(3):322-30.
74. Jordan D.J., Malahias M., Hindocha S., Juma A. Flap decisions and options in soft tissue coverage of the lower limb. *Open Orthop. J.* 2014; 8:423-32.
75. Mileto D., Cotrufo S., Cuccia G., Delia G., Risitano G., Colonna M.R., et al. The distally based sural flap for lower leg reconstruction: versatility in patients with associated morbidity. *Ann. Ital. Chir.* 2007; 78(4):323-7.
76. Akhtar S, Hameed A. Versatility of the sural fasciocutaneous flap in the coverage of lower third leg and hind foot defects. *J. Plast. Reconstr. Aesthet. Surg.* 2006; 59(8):839-45. 10.1016/j.bjps.2005.12.009
77. Kneser U., Bach A.D., Polykandriotis E., Kopp J., Horch R.E. Delayed reverse sural flap for staged reconstruction of the foot and lower leg. *Plast. Reconstr. Surg.* 2005; 116(7):1910-7.
78. Ali F., Harunarashid H., Yugasmavanan K. Delayed reverse sural flap for cover of heel defect in a patient with associated vascular injury. A case report. *Indian J. Surg.* 2013; 75(Suppl 1):148-9.
79. Ali M.A., Chowdhury P., Ali M., Iftaker Ibne Z., Dev J. Distally-based sural island flap for soft tissue coverage of ankle and heel defects. *J. Coll. Phys. Surg. Pak.* 2010; 20(7):475-7.
80. Mendieta M.J., Roblero C., Vega J.C. Neurotized distally based sural flap for heel reconstruction. *J. Reconstr. Microsurg.* 2013; 29(8):501-4.
81. Tan O., Aydin O.E., Demir R., Barin E.Z., Cinal H., Algan S. Neurotized sural flap: an alternative in sensory reconstruction of the foot and ankle defects. *Microsurgery.* 2015; 35(3):183-9.
82. Bibbo C. Plantar heel reconstruction with a sensate plantar medial artery musculocutaneous pedicled island flap after wide excision of melanoma. *J. Foot Ankle Surg.* 2012; 51(4):504-8.
83. Kwan M.K., Merican A.M., Ahmad T.S. Reconstruction of the heel defect with in-step island flap. A report of four cases. *Med. J. Malaysia.* 2005; 60(Suppl C):104-7.
84. Dong K.X., Xu Y.Q., Fan X.Y., Xu L.J., Su X.X., Long H., et al. Perforator pedicled propeller flaps for soft tissue coverage of lower leg and foot defects. *Orthop. Surg.* 2014; 6(1):42-6.
85. Fischer S., Klinkenberg M., Behr B., Hirsch T., Kremer T., Hernekamp F., et al. Comparison of donor-site morbidity and satisfaction between anterolateral thigh and parascapular free flaps in the same patient. *J. Reconstr. Microsurg.* 2013; 29(8):537-44.
86. Klinkenberg M., Fischer S., Kremer T., Hernekamp F., Lehnhardt M., Daigeler A. Comparison of anterolateral thigh, lateral arm, and parascapular free flaps with regard to donor-site morbidity and aesthetic and functional outcomes. *Plast. Reconstr. Surg.* 2013; 131(2):293-302.
87. Sauerbier M., Dittler S., Kreutzer C. Microsurgical chest wall reconstruction after oncologic resections. *Semin. Plast. Surg.* 2011; 25(1):60-9.
88. Saba S.C., Shaterian A., Tokin C., Dobke M.K., Wallace A.M. The pedicled myocutaneous flap as a choice reconstructive technique for immediate adjuvant brachytherapy in sarcoma treatment. *Curr. Oncol.* 2012; 19(6):e491-5.
89. Hughes T.M., Thomas J.M. Sarcoma metastases due to iatrogenic implantation. *Eur. J. Surg. Oncol.* 2000; 26(1):50-2.