

RECONSTRUCTIVE OPERATIONS OF SERIOUS SCOLIOTIC DEFORMATION AT CHILDREN

Shavga N.N.,¹ Shavga N.Gh.²

*"Nicolae Testemitanu" State Medical and Pharmaceutical University
1Research Laboratory "Surgical infections at children"*

2Department of Pediatric Surgery, Orthopedics, Chisinau, Republic of Moldova

ABSTRACT

In Clinic of Vertebrology, Orthopedics and Traumatology of the "N.Georgiu" Scientifically-Practical Center of Children's Surgery 58 children with scoliosis ($>70^\circ$) of different etiology, have been pre- and post-operatively examined with a follow-up of 1 to 5 years. The comparative analysis of the quality of the life of patients with severe spine deformations (according to a questionnaire „EQ-5D"), before and after surgical intervention, has shown that quality of the life of patients in postoperative period essentially improved, in comparison with the preoperative period, from $12,7 \pm 0,3$ points to $7,02 \pm 0,1$. The distant results of surgical treatment were: good – 39 (68,4%), satisfactory – 12 (21,1%), unsatisfactory – 7 (12,3%). The differential election of treatment option in spine deformation management depends on the age of patient, extent of deformation, spine mobility and neurological impairment. Application of high technologies allows achieving good results in these patients.

Key words: scoliosis; spine deformations; high technologies, children

INTRODUCTION

Irrespective of etiology, spine deformations in adolescents represent the cause that influences the main peculiarities of the spinal column: its safety and stability; initially it is manifesting by pains, static's infringements, and internals' dysfunction, subsequently it leads to severe decrease of quality of the life [1, 8, 9, 11]. The choice of surgical and therapeutic options in the management of spine deformations at children is still controversial [2, 5, 6, 11].

Problems and contradictions. At the present moment at scoliotic illness' treatment, surgical tactics remains discussed in the following aspects:

- At what age is it better to operate?
- What surgical technique will be more effective?
- Whether surgical intervention at the level of zones of growth and intervertebral disks will be expedient?

Data of epidemiological research, conducted Scientifically-Practical Center of Children's Surgery by randomization method, showed that in 2011 the frequency of scoliotic illness of RM reached on 7,8% at children and teenagers (till 18 years), from which 0,26% – the deformation angle was $> 70^\circ$. They make 5,2% in structure of diseases of a locomotorium apparatus. [10].

Work's goal: rising of quality of the life of children with spine deformations, by working out of surgical treatment algorithm.

MATERIAL AND METHODS

In Clinic of Vertebrology, Orthopedics and Traumatology of the "N.Georgiu" Scientifically-Practical Center of Children's Surgery 58 children with scoliosis ($>70^\circ$) of different etiology, for correction of deformation at which was used polysegmentary constructions, have been pre- and post-operatively examined with a follow-up of 1 to 5 years (2008 – 2012). The evaluation included collecting of anamnesis data, clinical examination, labs and imaging (standard radiography/ with functional tests, magnetic resonance). Children were aged between 5 and 17 years; they were predominantly girls – 61(56 %).

Patients were parted, on 3 categories: I category – 26 patients with complete growth (14-16 years) (medium – 14,8 years) and idiopathic mobile spine deformations, curvature angle to $70-85^\circ$, coefficient of Harrington >5 ; II category – 18 patients with complete growth (14-17 years) and idiopathic rigid forms of deformation (medium – 15,9 years), curvature angle is more than $85-90^\circ$ and coefficient of Harrington < 5 ; III category – 16 patients with juvenile idiopathic and congenital deformations (5-12 years).

The main goals of surgical interventions were: elimination of deformation and disbalance correction and spine stabilization. Surgery allowed obtaining the following results: reconstruction of forward and average spine columns, restoration of physiological spine profiles (frontal and sagittal); restoration of normal anatomy of the vertebral channel; stabilization of the spine-impellent segment.

RESULTS AND DISCUSSION

Tactics of surgical interventions, depending on category was following:

The I category – 26 patients with complete body growth (14-16 years) and idiopathic plentiful spine deformations was carry out one-stage dorsal correction (Fig 1).

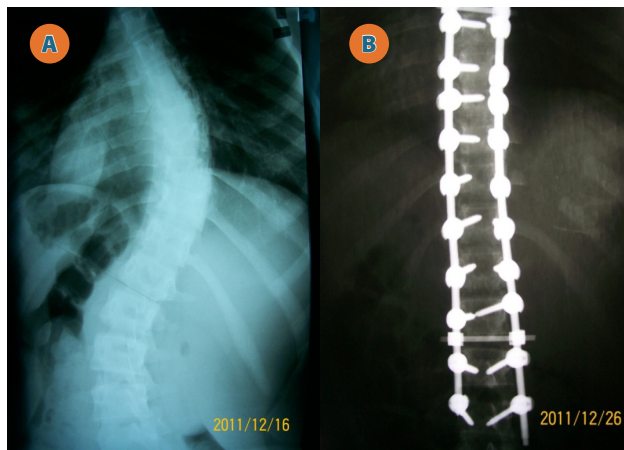


Fig 1. Before operation the angle of deformation was 70° (A) and after operation - 0°, correction of deformation is 100% (B)

The II category – 18 patients with complete body growth (14-16 years) and idiopathic rigid forms of deformation by the first stage was executed forward spine mobilization (a multilevel discectomy), the second – dorsal correction of deformation by C-D system (Fig 2.).

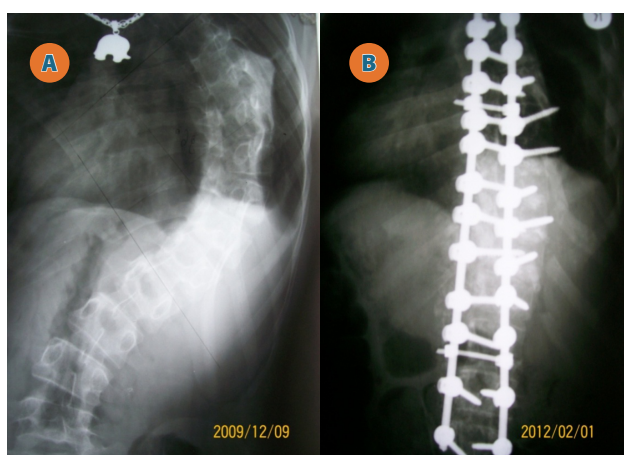


Fig 2. Before operation the angle of deformation was 127° (A) and after operation - 29°, correction of deformation is 98° (B)

The III category – 16 patients with juvenile idiopathic and congenital deformations (5-12 years) was carried out "blocking spondylosyndesis" at curvature top with the following dorsal correction by "a growing construction". In process of children growth through minimum invasive access the phased sys-

tem's distraction is carried out. One step of a distraction equals 1 cm. Intervals of stage-by-stage correction depend on age growth activity and rates of deformation advance: from 6 months to 1,5 years.

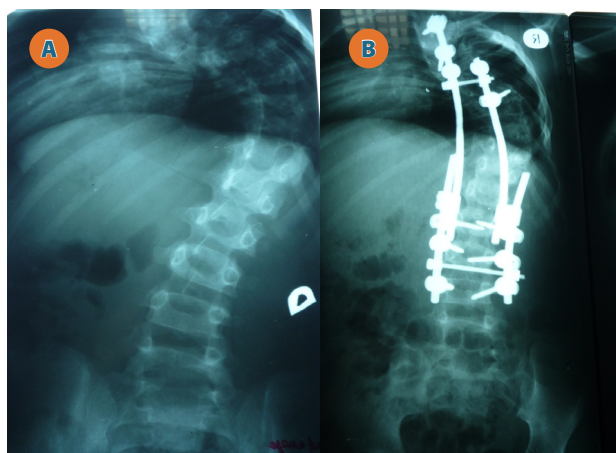


Fig 3. Before operation (A) and after operation of "blocking spondylosyndesis" at curvature top with the following dorsal correction by "a growing construction" (B)

The comparative analysis of the quality of the life of patients with severe spine deformations (according to a questionnaire „EQ-5D“), before and after surgical intervention, has shown that the quality of the life of patients in postoperative period essentially improved, in comparison with the preoperative period, from $12,7 \pm 0,3$ points to $6,7 \pm 0,1$. The distant results of surgical treatment were good: (correction > 55%) – 39 (68,4%), satisfactory (55%-40%) – 12 (21,1%), and unsatisfactory (< 40%) – 7 (12,3%). Complications took place in 9(15,8%) cases.

CONCLUSIONS:

The tactics of surgical treatment of spine deformations and further forecast depend on the type of neurological infringements and the character of bones' damages.

Optimum method of correction of difficult rigid scoliotic spine deformations were: forward spine release; dorsal correction and backbone fixation by a metal construction.

Surgical treatment of difficult juvenile scolioses began at 10-12 years old, and combined forward spine release with the following dorsal correction without posterior spine fusion execution.

In cases of congenital deformations primary operative defect's correction was carried out at children at the age of 3-7 years – "blocking spondylosyndesis" at curvature top with the following dorsal correction by "a growing construction" without posterior spine fusion execution.

Final correction of deformation, posterior spine spondylosyndesis and thoracoplasty are carried out on the end of spine growth.

REFERENCES

1. Cotrel Y., Dubousset J., Guillaumat M. New universal instrumentation in spinal surgery. *Clin. Orthopaed. Rel. Res.* 1988; 227: 10-29.
2. Jonge T., Dubousset J.F., Illes T. Sagittal plane correction in idiopathic scoliosis. *Spine.* 2002; 27(7):745-61.
3. Lenke L.G., Bridwell K.H., Baldus C. Cotrel-Dubousset instrumentation for adolescent idiopathic scoliosis. *J. Bone Jt Surg.* 1992; 74-A(7):1056-67.
4. Lenke L.G., Betz R.R., Haheer T.R., Lapp M.A. et al. Multisurgeon assessment of surgical decision-making in adolescent idiopathic scoliosis. *Spine.* 2001; 26(9):2347-53.
5. Merola A.A., Haheer T.R., Brkaric M., Panagopoulos G. et al. A multicenter study of the outcomes of the surgical treatment of idiopathic adolescent scoliosis using the SRS outcome instrument. *Spine.* 2002; 27(18):2046-51.
6. Suk S., Kim W., Lee C. Indication of proximal thoracic curve fusion in thoracic adolescent idiopathic scoliosis. *Spine.* 2000; 25(18):2342-9.
7. Villemure I., Aubin C.E., Grimand G., Dansereau J., Labelle H. Progression of vertebral and spinal three-dimensional deformities in adolescent idiopathic scoliosis. A longitudinal study. *Spine.* 2001; 26(20): 2244-50.
8. Antonescu D. Diformitățile coloanei vertebrale: scolioze-cifoze. *Ann Pato. Ap. Locom.* 2008; II (101):164-265.
9. Mihai Jianu. Scolioza pediatrică. Pro Editura și Tipografie. București. 2005; 141. p.
10. Șavga N.N., Șavga N.G. Operații de reconstrucție în diformitățile scoliotice la copii. *Buletin de Perinatologie.* nr. 2, V.58- nr. 3, V.59. Materialele Congresului V al Federației Pediatrilor Țerilor CSI și Congresului VI al Pediatrilor și Neonatologilor din Republica Moldova. Chișinău. 2013; pp. 148-51.
11. Ульрих Э.В. Аномалии позвоночника у детей. *Руков. для врачей СПб. ЭЛБИ-СПб.* 1995; 364 с.