

Doctoral school in the field of medical sciences

By manuscript title
C.Z.U.: 616.381-006-07(043.2)

ȘCHIOPU Victor

**VALUE ESTIMATION AND COMPARISON OF DIAGNOSTIC
METHODS FOR PRIMARY RETROPERITONEAL TUMOURS**

321.13 - SURGERY

Summary of Ph.D. Thesis in Medical Sciences

Chișinău, 2022

The thesis was elaborated within the Department of Oncology, IP State University of Medicine and Pharmacy "Nicolae Testemitanu", and IMSP Institute of Oncology, Gastrology Department, Founding Consortium of the Doctoral School in Medical Sciences.

Scientific coordinator

Ghidirim Nicolae, professor, M.D., Ph.D.

Co-tutelle conductor

Țurcanu Vasile, Ph.D., Associate Professor

Members of the guidance group:

Lilian Antoci, Ph.D.

Nadejda Corobcean, Ph.D., Associate Professor

Godoroja Vitalie, surgeon

Ph.D. thesis defence will take place on 05.10.2022, 02:00 pm, within "Nicolae Testemitanu" State University of Medicine and Pharmacy, 165 Ștefan cel Mare și Sfânt bd., room 205, at the meeting of the Commission for Public Defence of Ph.D. thesis, approved by the decision of the Scientific Council of the Consortium minutes no. 33 from 03.06.2022.

Composition of the Commission for the public defense of the doctoral thesis:

President:

Ungureanu Sergiu,

professor, M.D., Ph.D., „Nicolae Testemitanu” SUMPh

Members:

Ghidirim Nicolae,

professor, M.D., Ph.D.

Corobcean Nadejda,

Ph.D., Assoc. Prof

Belev, Nicodim,

professor, M.D., Ph.D.

Official Reviewers:

Cazacov Vladimir,

professor, M.D., Ph.D.

Dascaluc Ion,

M.D., Ph.D.

Olaru Andrei,

M.D., Ph.D.

Author

Victor Șchiopu

SUMMARY

SUMMARY	2
CONCEPTUAL RESEARCH MILESTONES	3
THESIS CONTENT.....	6
GENERAL CONSIDERATIONS ABOUT PRIMITIVE RETROPERITONEAL TUMORS.	6
CHARACTERISTIC OF CLINICAL OBSERVATION MATERIAL AND METHODS OF RESEARCH.....	8
COMPARATIVE ANALYSIS OF DIAGNOSTIC METHODS OF PRTs.....	9
GENERAL CONCLUSIONS.....	20
PRACTICAL RECOMMENDATIONS	32
BIBLIOGRAPHY	33
APPENDIXES	35
LIST OF SCIENTIFIC PUBLICATIONS AND EVENTS.....	38
LIST OF ABBREVIATIONS.....	40

CONCEPTUAL RESEARCH MILESTONES

Timeliness and importance of the issue addressed: Primitive retroperitoneal tumors (PRTs) develop in the space delimited by the posterior parietal peritoneum and endoabdominal fascia, comprising extraorganic structures of fatty, connective, fascial, vascular, nervous, muscular fascicules, lymph vessels and nodes or embryonic vestiges, more commonly derived from the urogenital apparatus. [1,2,3,4,5].

PRT are rare tumors, representing 0.2% of the 60,000 tumors researched by Pack and Tabah, 0.07% of 30,000 collected by Bucalossi [7,16]. Russian literature mentions the rarity of PRT, providing data on the incidence of 0.03-1% of all human tumors [8,9,10]. According to the data taken from the "National Cancer - Registry" of the Department of Monitoring, Evaluation and Integration of Medical Care Services of the Oncology Institute of the Republic of Moldova, during a calendar year there are registered in the average 15-18 cases of PRT, which constituted 0.7%.

Benign or malignant retroperitoneal tumors derive from a wide variety of tissues, so their classification is mainly by histological parameter (tissue of origin). These tumors are independent to the retroperitoneal organs: pancreas, adrenal, kidney, ureter or viscera in the vicinity. Depending on the tissues of origin, PRTs can be classified [11] in tumors of mesodermic origin, ectodermic and origin in embryonic vestigial tissues.

Developed in retroperitoneal space, PRT is a heterogeneous group of oncological diseases with late diagnosis, malignancy in about 80% of cases, and only 20% benign [12]. Clinical signs appear as a consequence of compression or invasion of organs in the vicinity. The emerged clinic is a secondary one, characteristic of the affected adjacent organ. According to literature data, tumors with a size less than 5 cm in diameter can be incidentally diagnosed [13,16], the most common PTR are diagnosed at a diameter size greater than 10 cm, with an average of 13.7 cm [14,15].

In the treatment plan, the surgical one remains to be of choice. For the determination of treatment tactics, timely diagnosis of these tumors is indispensable. The diagnostic algorithm is uncertain, being adapted for each clinic, depending on the existing possibilities. Abdominal ultrasound remains to be the most important and used investigation highlighting the tumor, indicating its solid or cystic character, but cannot always state the tumor's organ belonging and its visceral or vascular relationships. Much more valuable in terms of diagnosis are computed tomography (CT) and magnetic resonance investigation (MRI). These methods of investigation can easily determine tumor location, organ membership and visceral or vascular relationships, but a definite diagnosis is established only after the histological examination of the operative part [1,16]. The low incidence, the clinical, histological polymorphism and the anatomical peculiarities of the retroperitoneal space create difficulties even for the most experienced surgeons and oncologists [6]. In this context, the scientific research focused on the diagnosis and treatment of PTR remains to be current and present.

Aim of the study: Estimating the informativity and specificity of diagnostic methods of Primitive Retroperitoneal Tumors for the elaboration of a practical behavior algorithm in the diagnosis of patients with PTR from the Republic of Moldova.

Study objectives:

1. Estimation of the degree of informativity and accuracy of imaging methods in the diagnosis of primitive retroperitoneal tumors.
2. Determining the role of laparotomy, laparoscopy and morphopathological examination in the diagnosis of primitive retroperitoneal tumors.
3. Comparative analysis of diagnostic-therapeutic results obtained in the study group.
4. Development of an early diagnostic algorithm of PRT and its implementation in the activity of surgeons and oncologists practitioners

Solved scientific problem:

1. It was determined the primacy of computerized tomography with intravenous contrast in the diagnosis of PRT.
2. The role of laparotomy in the diagnosis of PRT was established due to the visualization of the tumor with its macroscopic characteristics and the microscopic and immunohistochemical examination of the extirpated tumor or of the bioptic material, establishing the morphological picture.
3. Estimating the comparative value of the obtained results, the main role of immunohistochemical examination has been demonstrated, especially in the diagnosis of some forms of sarcoma and determining their degree of differentiation, which allows to establish the treatment tactics.
4. Based on the results obtained, it was possible to develop a behavioral algorithm in the diagnosis of PRT.

Novelty and originality of the study:

The scientific novelty and originality lies in the fact that PRT diagnosis requires a thorough clinical-imagistic and surgical effort (diagnostic laparotomy) in the early establishment of these pathologies. A diagnostic algorithm was developed through comparative evaluation of diagnostic methods. Each method has been demonstrated to have a reliable diagnosis of PTR with the finding of tumor origin in the histological and immunohistochemical examination result. Based on this algorithm, a conduct of investigations in helping clinicians was recommended, first of all surgeons and oncologists who will receive information and logistical support to guide step by step in the application of diagnostic methods of PRT.

Theoretical significance:

It consists in conducting a comparative study of the results obtained from the use of complex diagnostic methods to streamline the diagnostic act in the PRT.

Applicative value of research:

The results obtained required the establishment of an effective diagnostic algorithm. Based on this algorithm a methodological conduct of early diagnosis of PRT for surgeons and oncologists was recommended.

Implementation of scientific results

The results of the study were implemented in the daily practice of the Department of Gastrology, Proctology, Urology and ALM Tumors as well as in the respective offices of the Diagnostic Advisory Center (DAC) of the IMSP IO.

Implementation of research results.

The results of the scientific research and the aspects of the clinical management studied were mirrored through discussions at national and international forums (Moldova, Romania), at the annual conferences of the collaborators and students of the USMF "Nicolae Testemitanu", the meetings of the Oncologists Society of the MSP IO in 2016-2021: International Meeting of Surgery, Iași, 4 - 7 October 2017; National Congress of Surgery, Sinaia, 6-9 June 2018; Congress of Oncologists of Moldova with International Participation, Chisinau, October 8-10, 2020; Annual conference dedicated to the days of the State University of Medicine and Pharmacy "Nicolae Testemitanu", Chisinau, October 19, 2017; Annual conference dedicated to the days of the State University of Medicine and Pharmacy "Nicolae Testemitanu", Chisinau, October 18, 2018; Posters State University of Medicine and Pharmacy "Nicolae Testemitanu" of the Republic of Moldova. Congress is also dedicated to the Science for Peace and Research Day. Chisinau, 21-23 October 2020; MedEspera, The 7th International Medical Congress for Students and Young Doctors, May 3-5, 2018.

Publications on the thesis topic: On the topic of the study were published 12 publications, of which 2 articles in international journals, 3 in national journals (category B), 9 abstracts in international and national congresses and conferences with international participation, 4 certificates of innovator

Summary of the thesis compartments: The thesis includes: introduction, 3 chapters, the synthesis of the obtained results, general conclusions, practical recommendations; the bibliographic index, the annexes, the list of abbreviations, are attached.

Summary of results obtained. The relevant results of the research shall be interpreted in relation to the objectives and assumptions undertaken, with the results of other researchers of the field investigated.

Keywords: Primitive retroperitoneal tumors (PRT), retroperitoneal space, diagnosis.

For the elaboration of the PhD thesis was obtained the positive opinion of the Research Ethics Committee within IP Nicolae Testemitanu State University of Medicine and Pharmacy of the Republic of Moldova (Minutes no. 84 of 20 June 2017).

THESIS CONTENT

GENERAL CONSIDERATIONS ABOUT PRIMITIVE RETROPERITONEAL TUMORS.

Primitive retroperitoneal tumors (PRTs) are a heterogeneous and complex group of nosological oncological entities with the following characteristics: develops in the retroperitoneal space; are primitive, not belonging to metastatic secondary tumors or to invasive ones in the vicinity; do not have organic membership (pancreas, adrenal glands, kidneys, ureters) or bones, are of mesenchymal, neuro-ectodermal or vestigial origin [1-5]. Tumors located in the pelvic retroperitoneal space also refer to primitive retroperitoneal tumors except those derived from the bladder or prostate. As an argument for the inclusion of the latter in the group of primitive retroperitoneal tumors also serves their common biological characteristic, which is why the therapeutic tactics are common.

Having different histological structures, PRT are part of the group of tumors developed from extra-skeletal soft non-epithelial tissues, except for the reticulo-endothelial system, glia and stromal tissue of the parenchymal organs. Soft tissue tumors constitute an extremely heterogeneous group, thus they are classified according to the cytogenetic criterion and according to the adult resembling tissues [8]. PRTs, embryogenic, are grouped into 4 categories: mesenchymal, neurogenic, teratomas or vestigial and retroperitoneal cysts. Tumors of mesenchymal origin constitute about 75.0% [9-11], consisting of fat, smooth or striated muscle, blood or lymphatic vessels, fibrous connective tissue.

Having different histological structures, PRT are part of the group of tumors developed from extra-skeletal soft non-epithelial tissues, except for the reticulo-endothelial system, glia and stromal tissue of the parenchymal organs. Soft tissue tumors constitute an extremely heterogeneous group, thus they are classified according to the cytogenetic criterion and according to the adult resembling tissues [8]. PRTs, embryogenic, are grouped into 4 categories: mesenchymal, neurogenic, teratomas or vestigial and retroperitoneal cysts. Tumors of mesenchymal origin constitute about 75.0% [9-11], consisting of fat, smooth or striated muscle, blood or lymphatic vessels, fibrous connective tissue.

Retroperitoneal cysts are tumor formations consisting of a capsule and fluid content. The histological structure of the cysts, as well as their content, are different, depending on the etiology and the time period in which they were formed. There are 2 types of cysts: neoplastic or genuine and false (pseudocysts). The capsule of the veridic cyst is most often padded with a layer of epithelial cells less often endothelial, while the capsule of the pseudocysts has fibrous structure being the result of the local inflammatory process. Etiopathogenetic, retroperitoneal cysts, are classified into inborn and acquired.

The inclusion of these tumors in a single nosological form is due to the common space of development - retroperitoneal space (RPS), similar clinical manifestations, similar diagnostic principles, common principles of treatment, the basic being surgical. The anatomical complexity and the tissue polymorphism hosted by it are reflected in the favorable neoplastic conditions for the development of numerous tumor entities. Retroperitoneum space, can accommodate a large group of tumors both benign and malignant [14], the malignant ones being 4 times more common (H. Chang et al.2017). PRT constitutes approximately 0.1%-0.2% of all malignancies of the human body, 80-90.0% of them being malignant [18].

Classification of tumors in benign-malignant is more conventional. The conventionality of classifying tumors in benign and malignant is due to the fact that, although it is an index of malignancy, some benign tumors often have an infiltrative growth character and have a high relapse rate. Often, even if histologically the presence of sarcomatose structures is confirmed, tumors have a capsule and rarely metastasize [6, 15-17]. The multistructurality of PRT complicates their unitary classification. Thus, several classifications have been designed according to the concepts on which they are based.

The incidence of PRT varies from year to year, due to the modernization of investigation methods. Analyzing literature data, PRTs are tumors rarely found in clinical activity of practitioners representing 0.01-1.0% of all neoplasms of the human body [6,7]. Pack and Tabah provide PRT incidence data of 0.2% of 60,000 tumors researched, and Bucalossi - 0.07% of 30.00 cases analyzed. Primitive retroperitoneal

tumors (PRTs) are a heterogeneous and morphological group, about 80.0% of them being malignant. Retroperitoneal sarcomas constitute approx. 15.0% of all sarcomas of the human body. Affecting more often the female gender, 1,5-2 times than the male sex, it can be said that PRT are characteristic of the adult's age, being more affected patients of the decade 5 and 6 [19- 22].

Because the area of the SRP is very large, PRT develops in an asymptomatic clinical silencer for a long time, eventually reaching an exaggerated tumor volume presenting a varied clinical picture. Clinical manifestations of PRT are non-specific, and depend on their location and relationship to adjacent structures.

Small tumors are usually asymptomatic and can only be detected incidentally. When the tumor grows, symptoms appear as a result of compression, displacement or invasion of adjacent organs. Clinical symptoms of retroperitoneal tumors are determined by the specific properties of places of development. Thus, the tumor in compression or infiltration of blood vessels, nerves, or other vital organs and structures leads to the emergence of symptoms and syndromes corresponding [76,77].

CHARACTERISTIC OF CLINICAL OBSERVATION MATERIAL AND METHODS OF RESEARCH

The study represents a complex, prospective structural and retrospective analysis of clinical, anamnestic, imagistic, morpho pathological and immunohistochemical data of 118 patients with primitive and non-primitive retroperitoneal tumors, investigated and treated within the Public Medical-Sanitary Institution Oncological Institute of Moldova (IMSP IO), during 2015 - 2020. In order to determine the informativity of the investigation methods used, the representative research group was calculated in the EpiInfo Program 7.2.2.6, compartment "StatCalc-Sample Size and Power" for transversal study based on the following parameters:

Confidence interval for 95.0% significance of results,

Statistical power - 80.0%,

- Frequency 0,01-0.2% is on average up to 1.0% [6,7,19-22].

Result: for 95.0% CI the calculated value is 15.21 design performed

(nx4: size, structure, multifoquality of the tumor, involvement of adjacent organs) = 60,8 and with 10.0% of the non-response rate n=67. For the given research was created the group of patients with retroperitoneal tumors or tumors suspected to be retroperitoneal, n=118 respecting the criteria of inclusion and exclusion from the research.

The study group should contain at least 67 patients. This study group consisted of 118 patients with retroperitoneal tumors. In order to exclude the secondary catheter of retroperitoneal tumors, the patients included in the study were examined in a complex, clinical and paraclinical manner using individual questionnaires according to a predetermined algorithm.

The study group was established according to the criteria of inclusion and exclusion in the study as follows:

Inclusion criteria:

- Adult patients who did not have absolute contraindications for carrying out investigations and submitting them to surgery, necessary for the study;
- Patients with primitive retroperitoneal tumors or tumors of the abdominal cavity that remained suspected retroperitoneal.
- Patients were included in the study based on the informed and signed agreement. The necessary information regarding the investigated parameters was collected after the observations made on the patients, taken from medical records and clinical monitoring cards in the wards: Gastrology, Urology, Malignant Tumors of the Musculoskeletal System and Malignant Melanoma (ALM), Profile Cabinets within CCD IO.

Exclusion criteria:

- Tumors with origin in the retroperitoneal organs (pancreas, adrenal, kidney, ureters);
- Patients in terminal states, swollen or with severe states caused by organ failure (cardiovascular, pulmonary, hepatic, renal).

COMPARATIVE ANALYSIS OF DIAGNOSTIC METHODS OF PRTs

The study group consists of 118 patients, 84 (71.18%) of whom are diagnosed with primitive retroperitoneal tumor (PRT) and 34 (28.81%) with non-PRT tumors, peritoneal cavity or secondary retroperitoneal space tumors. Of the patients with PRT, 48 (57.1% (95% CI 46.5, 67.3)) were female and 36 (42.9% (95% CI 32.7, 53.5)) were male. The mean age of patients with PTR in the research group is 57 years ($\sigma=12.0$), Me =59, Q1=51, Q3=67.

Table 1. Gender and age distribution of patients with TRP tumors

Gender \ Age	20-29 year	30-39 year	40-49 year	50-59 year	60-69 year	70-79 year	>80 year	Total
Female	-	n=3 (3,57%)	n=9 (10,71%)	n=16 (19,05%)	n=11 (13,9%)	n=7 (8,33%)	n=2 (2,38%)	n=48 (57,15%)
Male	n=2 (2,38%)	n=2 (2,38%)	n=4 (4,76%)	n=10 (11,9%)	n=15 (17,85%)	n=3 (3,57%)	-	n=36 (42,85%)
								n=84 (100%)

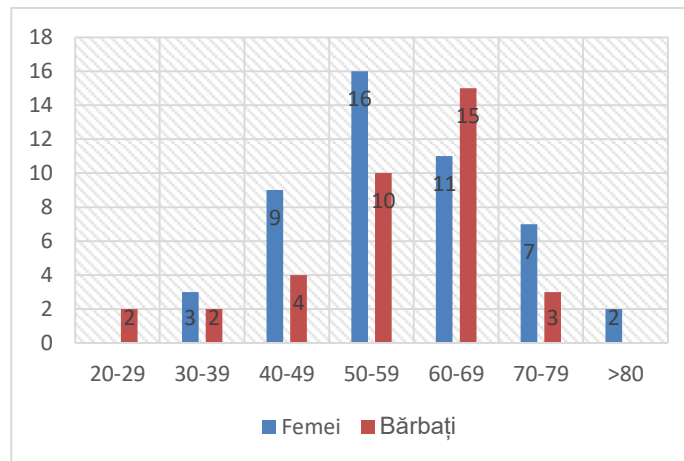


Figure 1. Gender and age distribution of patients

According to the data presented in the table below, which illustrates the distribution of patients according to age, we observe an identical percentage distribution for the cases included in the study where patients aged up to 55 years predominate.

"Primitive Retroperitoneal Tumor" is a common term used to define a group of tumors developed from mesenchymal, neuronal or vestigial tissue in retroperitoneal space. Of the total of 118 patients with retroperitoneal and abdominal tumors included in the study group, the diagnosis of primitive retroperitoneal tumor was established in 84 cases (73.0%, $p < 0.05$), the remaining 31 tumors (27.0%, $p < 0.05$) being metastatic or abdominal cavity. Primitive retroperitoneal tumors were represented by 32

benign tumors (38.1%, $p < 0.05$) and in 52 cases malignant tumors (61.9%, $p < 0.05$).

Table 2. Ratio of primitive vs non-primitive tumors

			Benign/Malignant		Total
			Benign	Malignant	
Classify	Secondary retroperitoneal tumors or abdominal cavity	No.	11 _a	23 _a	34
		No. expected	11,6	22,4	34,0
		%	32,35%	67,64%	100,0%
		%, Benign/Malignant	25,6%	27,8%	27,0%
	PRT	Nr.	32 _a	52 _a	84
		No. expected	31,4	52,6	84,0
		%	38,1%	61,9%	100,0%
		%, Benign/Malignant	74,4%	72,2%	73,0%
Total	No.	43	75	118	
	No. expected	43,0	75,0	118,0	
	%	36,44%	63,55%	100,0%	
	%, Benign/Malignant	100,0%	100,0%	100,0%	

Analyzing the clinical manifestations presented by the patients on admission, we can mention that these were varied and were mainly due to involvement or dislocation of retroperitoneal organs by massive tumors.

Table 3. Clinical manifestations of PRT

		Abs.	%
Presence of palpable volume Formation	No	63	53.4%
	Yes	55	46.6%
Localized pain in tumor area	No	54	45.8%
	Yes	64	54.2%
Pain with lumbar or lower limbs Irradiation	No	81	68.6%
	Yes	37	31.4%
Dyspepsia	No	49	41.5%
	Yes	69	58.5%
Edema of the lower limbs	No	113	95.8%
	Yes	5	4.2%
Urinary symptoms (haematuria, polyuria, dysuria, anuria)	No	107	90.7%
	Yes	11	9.3%
Fever	No	110	93.2%
	Yes	8	6.8%
Weight decrease >5 kg	No	62	52.5%
	Yes	56	47.5%

For the establishment of the diagnosis of "Primitive retroperitoneal tumor", the primordial for the clinician, is to exclude the organic or secondary character of the tumor. Thus, patients were examined by: Abdominal USG - 118 patients (100%), abdominal and small pelvis CT with intravenous contrast - 118 patients (100), MRI - 3 patients (2.5), fibroesogastroduodenoscopy - 32 patients (27.1%), fibrocolonoscopy - 31 patients (26.3%), irrigography - 4 patients (3.4%), urography - 29 patients (24.6%).

Given the fact that the retroperitoneal space is a vast space, the content of which is consisted of fat, connective tissue, blood vessels, fascia and organs, retroperitoneal tumors develop unhindered in an asymptomatic clinical silentium over a long period of time, reaching large dimensions at the time of diagnosis. As shown in Table no.10 and Figure 4, patients are hospitalized with tumors in an average of cm ($\sigma=10.5$), with a median disease period of 13 months ($\sigma=20$). It points out that only 25% of patients with PRT have addressed tumors under 10 cm. It should be mentioned that for non-PRT tumors, their dimensions are in the environment of 12.6 cm ($\sigma=20$), and the disease period is much shorter, only 7 months ($\sigma=6$). This may be explained by the precocciity of clinical sign development in non-PRT tumors with visceral involvement, leading patients to seek medical attention earlier.

Table 4. Tumor sizes and disease period

		PRT	Tumors non-PRT
Tumor size	Mean	17.3	12.6
	Median	13.0	10.0
	Standard Deviation	10.5	12.3
	Percentile 25	10.0	5.5
	Percentile 75	25.0	14.0
	Disease period	Mean	13
	Median	6	6
	Standard Deviation	20	6
	Percentile 25	3	3
	Percentile 75	12	12

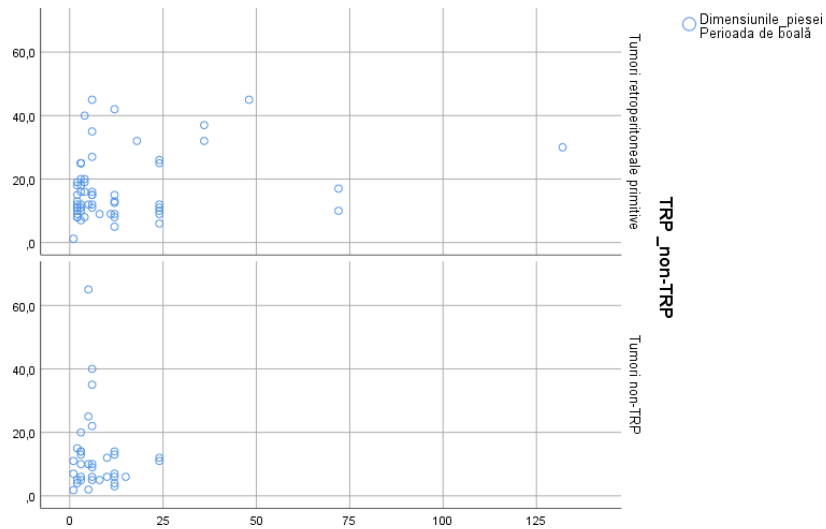


Figure 2. Graphical representation of interdependence of tumor size, tumor type and disease period

Appreciation of tumor location is paramount to the scheduling of the type of surgery. The diagnostic test used to determine the intra- or retroperitoneal location of the tumor based on CT with i.v. contrasting, showed the integrative value of sensitivity and specificity at the level of 0.620 (CI 95% 0.496, 0.743, $p < 0.001$), while the USG-based test demonstrated the same integrative values of sensitivity and specificity of 0.641 (IC 95% 0.541, 0.740, $p < 0.001$), which indicates that both CT and USG indicate good diagnostic accuracy compared to the occasional test, Figure 3a. Analyzing the average quality of diagnostic models, the USG is insignificantly higher compared to the CT with i.v. contrast. (0.54 vs 0.53, Figure 3 b). The differences determined are not of statistical significance because the AUC values are within the confidence interval.

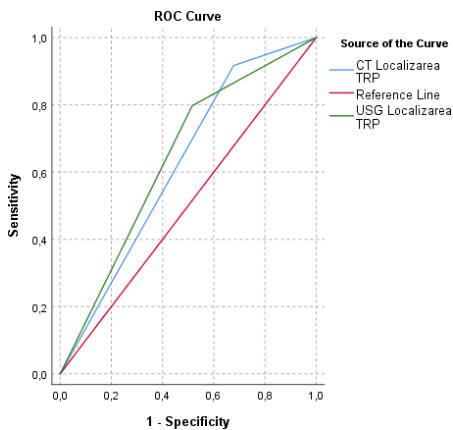


Figure 3a

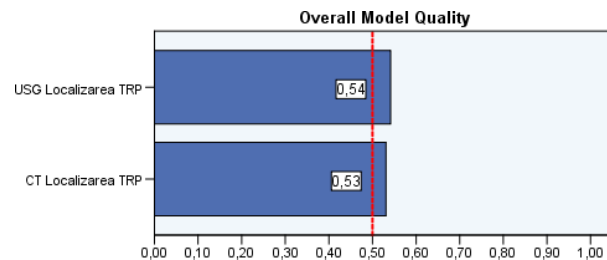


Figure 3b

Pearson χ^2 test with continual corrections was used to determine the correlation between the regular or irregular nature of the tumor and the type of tumor (benign or malignant). For primitive tumors, because the p- value is less than the chosen significance level $\alpha = 0.05$, we can reject the null hypothesis and conclude that there is a significant association between the edge carater and the benign or malignant type of tumor ($\chi^2 = 9.843$, $df = 1$, $p < 0.001$). Thus, tumors localized in the retroperitoneal space, with the unclear contour have a higher probability of being malignant.

Table 5. Assessment of the correlation between regular/irregular tumor margins and benign/malignant tumor type

			Character of the edges of the post-operative part		Total
			Irregular	Regular	
Non-primitive	Benign/Malignant	Benign	9	2	11
		Malignant	19	7	26
	Total		28	9	37
Primitive	Benign/Malignant	Benign	7	25	32
		Malignant	26	19	45
	Total		33	44	77
Total	Benign/Malignant	Benign	16	27	43
		Malignant	45	26	71
	Total		61	53	114

Also, a significant association between tumor consistency (solid, cystic, mixed) and benign or malignant type of tumor was identified. For primitive tumors, because the p-value is less than the chosen significance level $\alpha = 0.05$, the null hypothesis is rejected and we conclude that there is a significant association between the consistency of the tumor and the benign or malignant type of tumor ($\chi^2 = 7.526$, $df = 2$, $p = 0.023$).

Table 6. Assessment of the correlation between the tumor structure and the benign/malignant type of tumor

			Structure of the tumors			Total
			Solid	Cystic	Mixed	
Non-primitive	Benign/Malignant	Benign	3	1	7	11
		Malignant	17	0	10	27
	Total		20	1	17	38
Primitive	Benign/Malignant	Benign	23	5	4	32
		Malignant	38	0	7	45
	Total		61	5	11	77
Total	Benign/Malignant	Benign	26	6	11	43
		Malignant	55	0	17	72
	Total		81	6	28	115

In determining the uni- or multi-center character of the tumor, the CT showed an integrative sensitivity and specificity value of 0.733 (CI 95% 0.527, 0.939, $p < 0.001$), while the USG a value of 0.644 (CI 95% 0.415, 0.873, $p < 0.001$). Comparing the average quality of the USG vs CT model (0.42 vs 0.53, Figure 4), in the detection of multifocal carcater tumors, CT is more valuable.

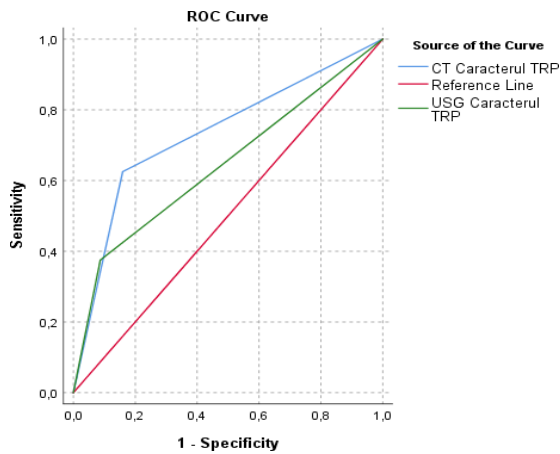


Figure 4 a

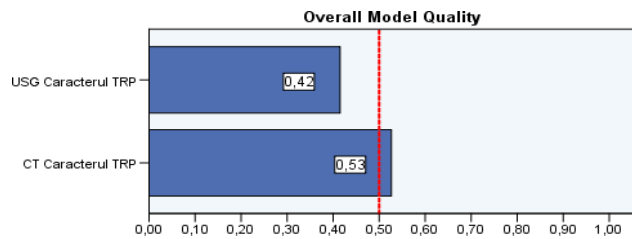


Figure 4 b

Contrast i.v. CT, as a diagnostic test to identify the character of tumor marigins, showed the integrative sensitivity and specificity value of 0.617 (95% CI 0.490, 0.745, $p < 0.001$, which denotes that contrast CT shows significantly better ability compared to an occasional diagnostic test, Figure 3.6 a). At the same time, the method based on USG showed the higher absolute value of AUC 0.720 (IC 95% 0.601, 0.838, $p < 0.001$, interpretations being similar to contrast CT, Figure 5 a), the average quality of the USG model being higher compared to the CT with intravenous contrasting (0.60 vs 0.49, Figure 5b).

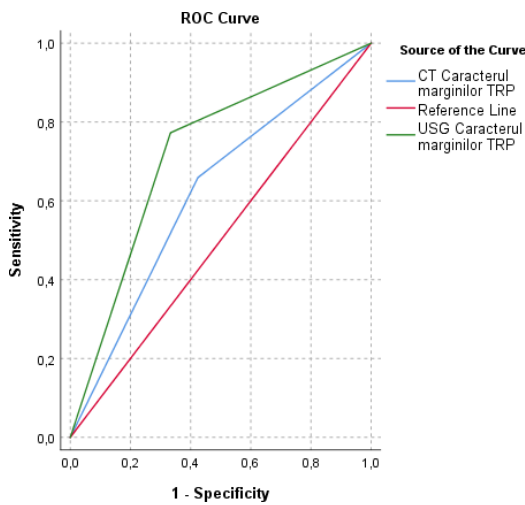


Figure 5 a

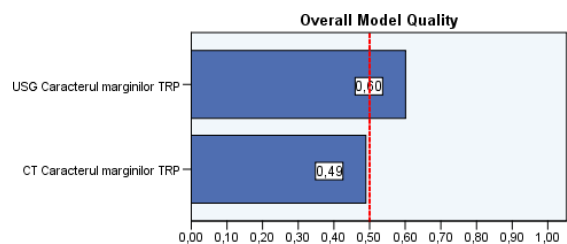


Figure 5 b

Correct assessment of the neighborhood ratio of tumors with adjacent organs is a must for determining the treatment tactics and the volume of surgery. Thus, the cerebral blood vessels were involved in 23 cases, which constitutes (19.49%), the small intestine - 22 cases (18.64), the pancreas - 17 cases (14.40%), the colon in 15 cases (12.7%), the kidneys - 9 cases (7.62%), adrenal gland - 9 cases (7.62%), spleen - 7 cases (5.93%), stomach - 3 cases (2.54%), bladder - 3 cases (2.54%) (Figure 6).

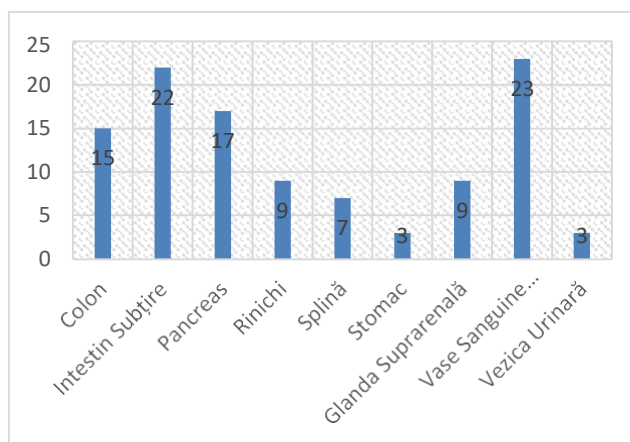


Figure 6. **Detection of organs involved in the tumor process during the surgery**

Often the resectability of the tumor is compromised by multiple invasions of organs with the impossibility of resection or prosthetics of these organs in case of involvement of the main vessels. Analyzing the imaging results with reference to the qualitative assessment of the tumor invasion in the adjacent organs, a superiority of the CT versus the USG is shown (Table 16). Although, according to AUC and AQD calculated in part for each statistical parameter investigated, CT showed superiority to USG, only a diagnostic method cannot be used in the clinical management of primitive retroperitoneal tumors. These two diagnostic methods should be used in tandem to obtain as real information as possible about the retroperitoneal neoplastic process.

Table 7. **Comparative analysis of diagnostic tests used in the study**

		USG		CT	
		AUC	AQD	AUC	AQD
Tumors localisation		0.641 (IC 95% 0.541, 0.740, p < 0.001).	0.54	0.620 (IC 95% 0.496, 0.743, p < 0.001).	0.53
Uni- or multicenter type of Tumor		0.644 (IC 95% 0.415, 0.873, p < 0.001).	0.42	0.733 (IC 95% 0.527, 0.939, p < 0.001).	0.53
Edges character		0.720 (IC 95% 0.601, 0.838, p < 0.001).	0.49	0.617 (IC 95% 0.490, 0.745, p < 0.001).	0.60
Tumor Neighborhood	Colon	0.767 (IC 95% 0.611, 0.922, p < 0.001).	0.61	0.908 (IC 95% 0.810, 1.006, p < 0.001)	0.81
	Bowels	0.795 (IC 95% 0.672, 0.917, p < 0.001).	0.67	0.930 (IC 95% 0.858, 1.002, p < 0.001).	0.85

	Pancreas	0.838 (IC 95% 0.705, 0.971, p < 0.001).	0.71	0.911 (IC 95% 0.818, 1.005, p < 0.001).	0.82
	Kidney	0.861 (IC 95% 0.699, 1.024, p < 0.001).	0.70	0.866 (IC 95% 0.703, 1.029, p < 0.001).	0.70
	Spleen	0.567 (IC 95% 0.326, 0.808, p < 0.001).	0.33	0.853 (IC 95% 0.649, 1.056, p < 0.001).	0.65
	Adrenal glands	0.593 (IC 95% 0.377, 0.808, p < 0.001).	0.38	0.778 (IC 95% 0.571, 0.985, p < 0.001).	0.57
	Blood Vessels	0.674 (IC 95% 0.532, 0.816, p < 0.001).	0.53	0.777 (IC 95% 0.647, 0.908, p < 0.001).	0.65

Depending on the resectable or non-resectable status of the tumor that was assessed based on the information obtained from the investigations, the patients included in the study were subjected to the laparotomy with a diagnostic or curative purpose. In primitive benign retroperitoneal tumors, excisional biopsy was performed in 12 patients (35.3% (95% CI 20.9, 52.0) and 17 patients (34.0%)(95% CI 22.1, 47.7)) tumor excision was performed. Primitive malignant retroperitoneal tumors were subjected to excisional biopsies in 15 cases (44.3% (95% CI 20.9, 52.0)), and in 27 cases (54.0% (95% CI 40.3, 67.3)), the tumor was completely exuded. Although retroperitoneal cysts are in most cases benign, which we demonstrated in our study as well, all 6 cysts identified were benign, the full excision of cysts was successful in only 2 cases (4.0% (95% CI 0.8, 12.2), in 4 cases what constituted (11.% (95% CI 20.9, 52.0)) partial excision of cysts was performed. Non-Hodgkin's lymphomas with primary damage of the retroperitoneal lymph nodes were confirmed in 7 cases, in 3 cases by excisional biopsy (8.8% (95% CI 4.1, 25.6)), and in 4 cases, when the disease was manifested by the presence of a formation or a solitary conglomerate, the entire formation or conglomerate was removed (8.0% (95% CI 2.8, 17.9)). Analyzing the overall, radical excision of primitive tumors was possible only in 50 cases (59.52%, p<0.05), in 34 cases (31.48%, p<0.05) performing excisional biopsy.

Table 8. Type of interventions undertaken

			Biopsy/Partial excision	Radiacal excision
PRT classification	1-PRT benign	Absolute number	12a	17a
		Relative number (%)	35,3%	34,0%
		95,0%, Inf. Limit IC for No. relative	20,9%	22,1%
		95,0%, Sup limit IC for No. relative	52,0%	47,7%
	2-PRT malignant	Absolute number	15a	27a
		Relative number (%)	44,1%	54,0%
		95,0%, Inf. Limit IC for No. relative	28,5%	40,3%

		95,0%, Sup limit IC for No. relative	60,7%	67,3%
3- Retroperitoneal cyst		Absolute number	4a	2a
		Relative number (%)	11,8%	4,0%
		95,0%, Inf. Limit IC for No. relative	4,1%	0,8%
		95,0%, Sup limit IC for No. relative	25,6%	12,2%
4 – LNH		Absolute number	3a	4a
		Relative number (%)	8,8%	8,0%
		95,0%, Inf. Limit IC for No. relative	2,5%	2,8%
		95,0%, Sup limit IC for No. relative	21,7%	17,9%

A variety of benign and malignant lesions (primary or metastatic) can be detected in the retroperitoneal space. The study showed 84 cases of primary retroperitoneal tumors (71.18 %), confirmed by morphopathological examination, out of a total of 118 cases originally included in the study. Data from the literature indicate that malignant tumors are four times more frequent than benign lesions (Hong Chang et al. 2017). Retroperitoneal space is the second most common soft tissue sarcomas development site, constituting 80% of malignant retroperitoneal tumors of mesenchymal origin, is associated with an unfavorable prognosis of long-term survival. In our study the most common form of sarcoma found was liposarcoma: in 20 cases (42.55% of all malignant tumors), followed by undifferentiated pleomorphic sarcoma - in 6 cases (12.76% of malignant tumors), and leiomyosarcoma, in 4 cases (8.51% of malignant tumors). The adverse prognosis in these types of tumors is due to the technical difficulties in obtaining R0 resections during surgery. Although liposarcoma compared to leiomyosarcoma reaches much larger dimensions, both forms of sarcoma are characterized by an aggressive loco-regional development, frequently invading adjacent organs and tissues. Other malignant tumors diagnosed in the study were: fibrosarcoma - 3 cases (3.57%), MPNST - 2 cases (2.38%), hemangiopericytoma, myofibrosarcoma, osteosarcoma, synovial sarcoma, ectopic seminoma - each one case (1.19%). The vast majority of malignant lymphomas detected in the study were non-Hodgkin's type, derived from B cells, in 7 cases (14.89% of malignant tumors). These tumors were diagnosed by biopsy, morphological diagnosis being confirmed by immunohistochemistry. Among benign PRTs, the most common were lipoma and benign schwannoma

- 7 each (8.33%) and retroperitoneal cyst - 6 cases (7.14%). The most rare histopathological forms were: retroperitoneal lymphadenopathy - 3 cases (3.57%), mesenchyma and neurofibroma (each with 2 cases (2.38%)), angioliipoma, fibrolipoma, granuloma, leiomyoma, lymphangioma (each with one case what constituted (1.19%)).

Completion of the diagnosis was possible after histopathological examination of tumor tissues. Immunohistochemical techniques were used in addition to the examination of H & E colored sections in 44 cases which constituted (37.28%). The use of immunohistochemical diagnostic techniques allowed to finalize the morphopathological diagnosis of PRTs in 30 cases (25.42%), and in 14 cases, what constituted (11.86%) was confirmed the non-PRT status of tumors, these being: metastases of carcinoma in 4 cases (3.39%), neuroendocrine tumor - 4 cases (3.39%), GIST - 5 cases (4.23%), peritoneal pseudomixoma - 1 case (0.84%). However, due to the inherent limitations of immunohistochemistry, in 6 cases what constituted (7.14%) was not possible to determine the morphological diagnosis. To prevent cases of diagnostic uncertainty, complementary immunohistochemistry techniques should be supplemented with molecular genetic testing (Miettinen et al. 2000).

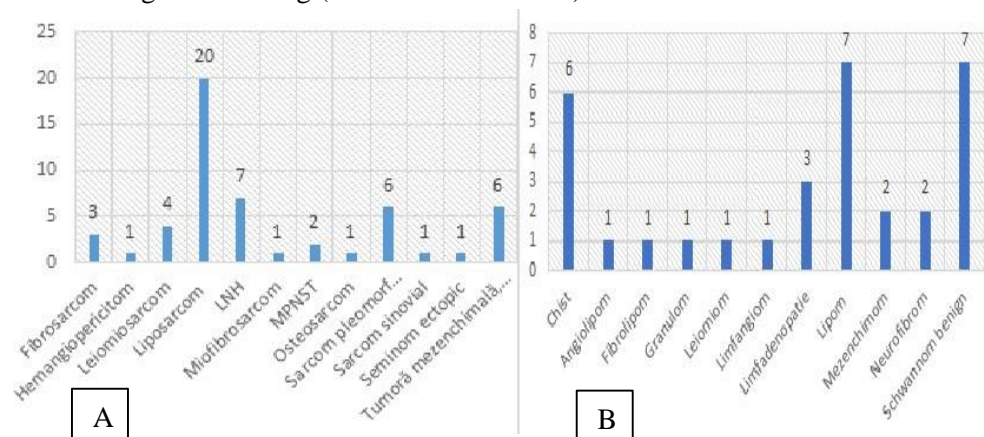
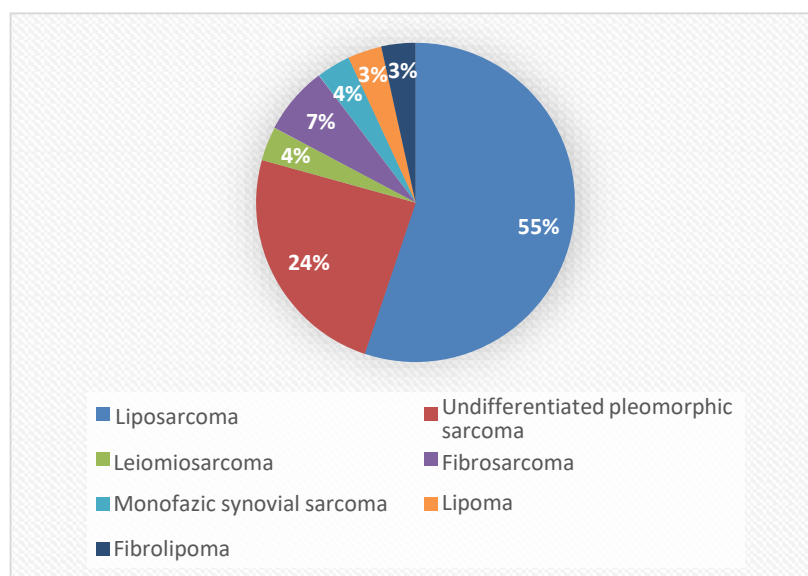


Figure 7. PRT histological type
A. Malignant primitive retroperitoneal tumor. B. Benign retroperitoneal tumor

An important feature of malignant retroperitoneal tumors is a tendency to relapse. Patients who experienced relapses of retroperitoneal tumors 29 (34.52%) were also included in the study after radical

surgical treatment. Thus, 15 of the patients in the study addressed repeatedly on the first relapse (which was 17.85%), 4 patients on the second relapse (4.76%) and 2 patients on the third relapse (2.38%). The most common relapsed liposarcoma. This type of retroperitoneal sarcoma relapsed in 8 cases - once (34.78%), in one case - 2 relapses (4.34%) and in 2 cases - 3 relapses (8.69%). Undifferentiated pleomorphic sarcoma was the second most frequent relapses. It relapsed in 3 cases (13.04%) once and in 2 cases (4.34%) 2 times. As with 2 relapses (4.34%) a patient was diagnosed with fibrosarcoma. A recurrence of monophasic synovial sarcoma was also recorded. Although benign tumors, lipomas and fibrolipomas have each relapsed once. In 2 cases, the patients were hospitalized with a diagnosis of relapsing liposarcoma, clinically-imagistically confirmed and undergoing surgical treatment, and the morphological examination of the removed postoperative part established the diagnosis of granuloma and inflamator process.

Figure 8. Share of PRT recurrences



GENERAL CONCLUSIONS

1. To determine the topographic localization, the tumour texture as well as the uni- or multicentric character of the tumour, both USG and CT with i.v. contrast. demonstrate virtually the same informativeness. In assessing the tumour size as well as the proximity ratio of the tumour to the adjacent organs, the CT with i.v. contrast. it is superior to ultrasonography.
2. Considering the large size of the tumour, on average 17.3 cm, preference was given to the laparotomy approach which offered the possibility of macroscopic evaluation of the tumour with excisional biopsy or cytoreductive excision of the tumour in 34 cases, which constituted 40.47 % and the pathological examination of the fully removed tumour, in 50 cases, which is 59.53%.
3. Analyzing the data obtained in the study, we can affirm that the USG and the CT with i.v. contrast. it provides information about location, tissue texture, the uni- or multicentric nature of the tumour and the relationship between the tumour and the adjacent anatomical structures that allows the assessment of the indications for surgical treatment. The pathological and immunohistochemical examination of the excised tumour or the biopsy material allows the definitive diagnosis of TRP with the definitive assessment of the morphological type of the tumour.
4. A diagnostic algorithm and clinical approach to patients with retroperitoneal tumours were developed with its implementation in the work of surgeons and oncologists.

PRACTICAL RECOMMENDATIONS

a. For medical practitioners:

1. In order to optimize the diagnostic-curative management and increase the yield of surgical treatment in patients with primitive retroperitoneal tumors, the "Algorithm of conduct of patients with PRT" is recommended, proposed to clinicians (surgeons, oncologists, family doctors, imaging physicians) in the Republic of Moldova, developed in accordance with the conditions of local activity.

a. For the administration IMSP IOM

2. Ultrasound is the diagnostic method used in the first stages of diagnosis, but it can also be used in the finalization of the diagnosis - a guiding method for puncture-biopsy of tumors, especially in the case of giant tumors that exceed the retroperitoneal space dislocating the organs of the abdominal cavity. The use of the Doppler module provides the opportunity to study the vascular behavior patterns of some tumors in real time, with a superior resolution. Also, ultrasound can be used at the post-operative monitoring stage, the method being accessible and efficient. Thus, providing the institution with specialists trained to perform investigation tablets, equipping the institution with performant ultrasound apparatus and providing the supplies needed to perform ultrasound guided biopsies would facilitate the diagnosis and programming of combined treatment stages.

3. Providing patients access to high-resolution Computed Tomography investigation, with the possibility of performing CT-guided biopsies, would offer the possibility of establishing morphopathological diagnosis minimizing the weight of diagnostic laparotomy and traumatic impact of this procedure.

4 Providing the Morphopathology section with the supplies necessary for the immunohistochemical study of tumors through financial and logistical supply efficiency.

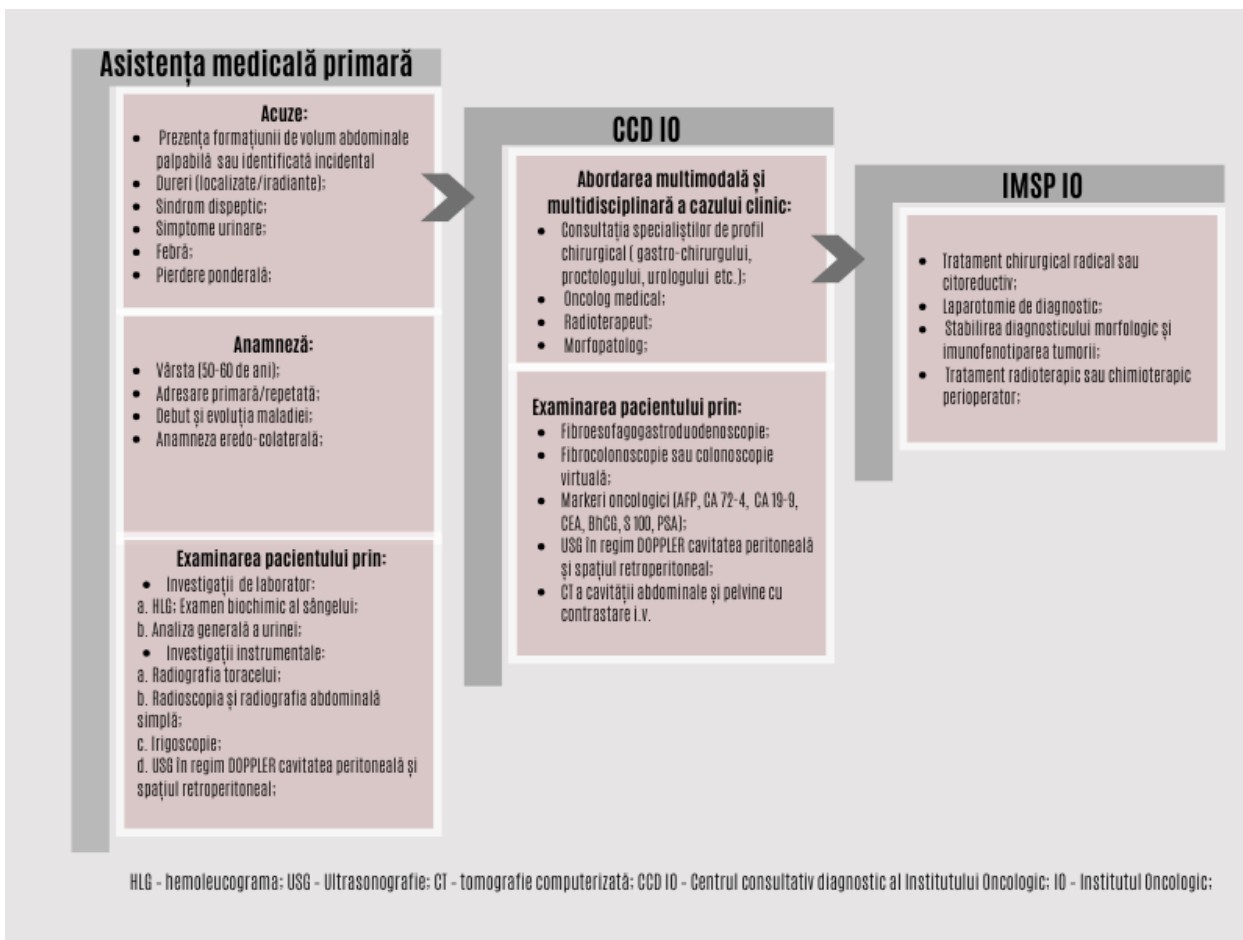
BIBLIOGRAPHY

1. Aragón-Mendoza RL, Arenas-Gamboa J, Vieira-Serna S, Sierra IAJ. Primary retroperitoneal tumor during pregnancy: Case report and review of the literature. *Rev Colomb Obstet Ginecol*. 2020;71(2):195–207.
2. Roată C., Bosânceanu ML, Pantazescu AN, Luncă S. Thoraco-retroperitoneal neurogenic tumors. Report of two cases. *Jurnalul Chir*. 2013;9(3):261–7.
3. Sorin P, Roxana G, Ionuț N, Adrian N. Abordul laparoscopic al tumorilor retroperitoneale primitive. 2011;6(3):109–13.
4. Brennan C, Kajal D, Khalili K, Ghai S. Solid malignant retroperitoneal masses-a pictorial review. *Insights Imaging*. 2014;5(1):53–65.
5. Schmitz E, Nessim C. Retroperitoneal Sarcoma Care in 2021. *Vol. 14, Cancers. MDPI*; 2022.
6. Șchiopu V. Diagnosticul tumorilor retroperitoneale primitive: reviu literaturii. În: *Buletinul Academiei de Științe a Moldovei. Științe Medicale*. 2018, 2-3(59-60), 125-132. ISSN 1857-0011.
7. Erzen D, Sencar M, Novak J. Retroperitoneal sarcoma: 25 Years of experience with aggressive surgical treatment at the Institute of Oncology, Ljubljana. *J Surg Oncol*. 2005 Jul;91(1):1–9.
8. Jobanputra GP, Parikh UR, Goswami HM. Histopathological study of soft tissue tumors (a study of 140 cases) in tertiary care center. *Int J Cur Res Rev*. 2016.
9. Goenka AH, Shah SN, Remer EM. Imaging of the Retroperitoneum. *Radiologic Clinics of North America*. 2012.
10. Chaudhari A, Desai P, Vadel M, Kaptan K. Evaluation of primary retroperitoneal masses by computed tomography scan. *Int J Med Sci Public Heal*. 2016;5(7):1423.
11. Elsayes KM, Staveteig PT, Narra VR, Chen ZM, Moustafa YL, Brown J. Retroperitoneal Masses: Magnetic Resonance Imaging Findings with Pathologic Correlation. *Vol. 36, Current Problems in Diagnostic Radiology*. 2007. p. 97–106.
12. Park SY, Kim SR, Choe YH, Lee KY, Park SJ, Lee HB, et al. Extra-axial chordoma presenting as a lung mass. *Respiration*. 2009 Feb;77(2):219–23.
13. Malde S. Primary retroperitoneal seminoma: an unusual cause of testicular pain. *JRSM Short Rep*. 2010 Dec;1(7):1–3.
14. Choi JH, Ro JY. The 2020 WHO Classification of Tumors of Soft Tissue: Selected Changes and New Entities. 2020.
15. Харченко ВП, Чхиквадзе ВД, Абдуллаева АА. Хирургического лечения неорганных забрюшинных опухолей. 62:65–9.
16. Rasulov RI, Dvornichenko V V, Muratov AA, Songolov GI, Mozgunov D V. Неорганные забрюшинные опухоли: прошлое и настоящее Родион. *Сибирский медицинский журнал (Иркутск)*. 2015;№ 7:5–14.
17. Osman S, Lehnert BE, Elojeimy S, Cruite I, Mannelli L, Moshiri M. A Comprehensive Review of the Retroperitoneal Anatomy, Neoplasms, and Pattern of Disease Spread. *Curr Probl Diagn Radiol [Internet]*. 2013 Sep 1 [cited 2018 Mar 9];42(5):191–208. Available from: <https://www.sciencedirect.com/science/article/pii/S0363018813000030>
18. Fujimoto N, Kubo T, Hisaoka M, Udo K, Yokomizo A, Shibuya T, et al. Demographics, management and treatment outcomes of benign and malignant retroperitoneal tumors in Japan. *Int J Urol*. 2018 Jan;25(1):61–7.

19. Hui JYC. Epidemiology and Etiology of Sarcomas. *Vol. 96, Surgical Clinics of North America*. 2016.
20. Sassa N. Retroperitoneal tumors: Review of diagnosis and management. *Int J Urol*. 2020 Dec;27(12):1058–70.
21. Lewis JJ, Leung D, Woodruff JM, Brennan MF. Retroperitoneal soft-tissue sarcoma: analysis of 500 patients treated and followed at a single institution. *Ann Surg [Internet]*. 1998;228(3):355–65.
22. Zeng X, Liu W, Wu X, Gao J, Zhang P, Shuai X, et al. Clinicopathological characteristics and experience in the treatment of giant retroperitoneal liposarcoma: A case report and review of the literature. *Cancer Biol Ther*. 2017;18(9):660–5.
23. Cheng-Hua Luo. Retroperitoneal Tumors. Cheng-Hua Luo, editor. Beijing; 2018.
24. Mullinax JE, Zager JS, Gonzalez RJ. Current diagnosis and management of retroperitoneal sarcoma. *Cancer Control*. 2011;18(3):177–87.

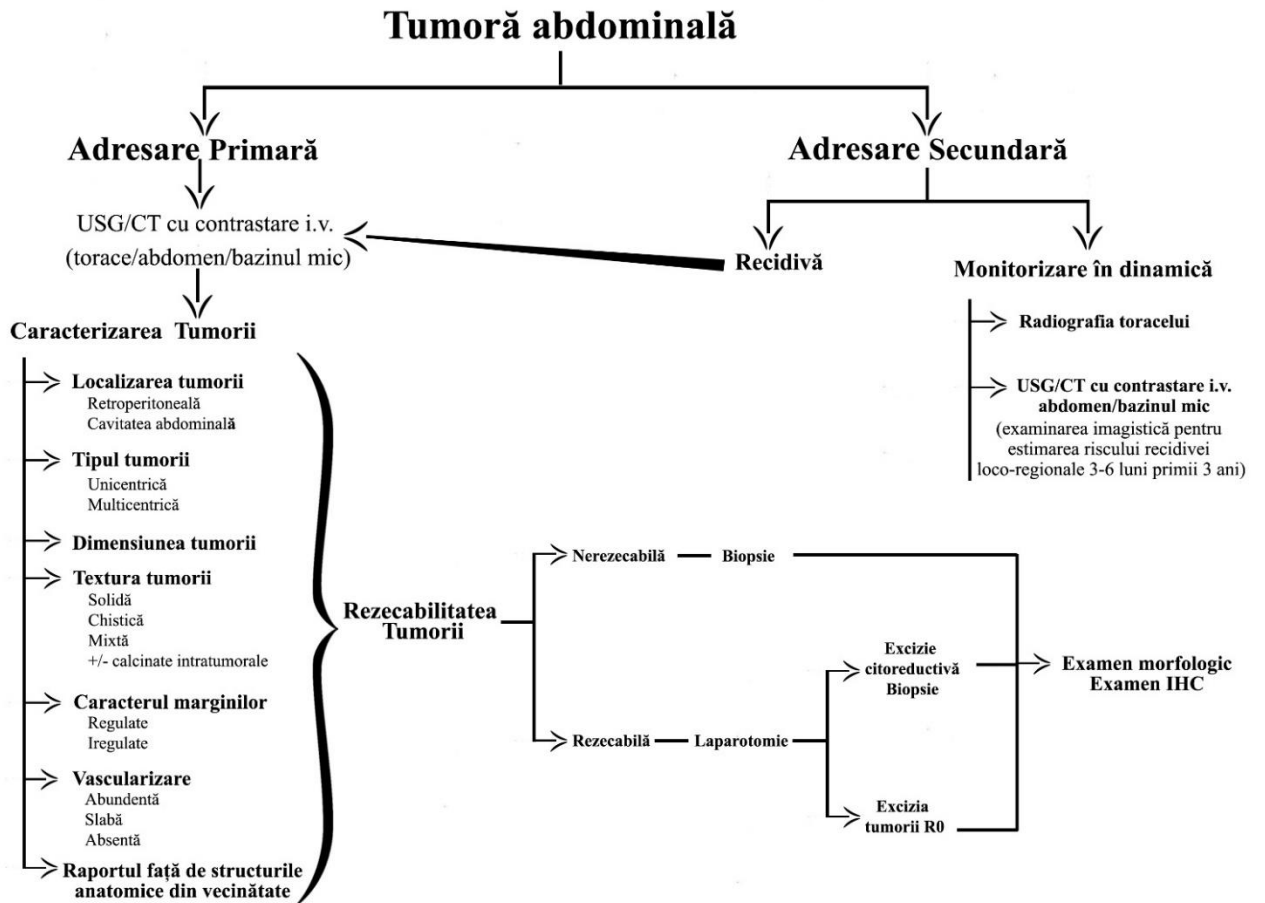
Appendix no. 1

PRACTICAL APPROACH TO RETROPERITONEAL MASSES



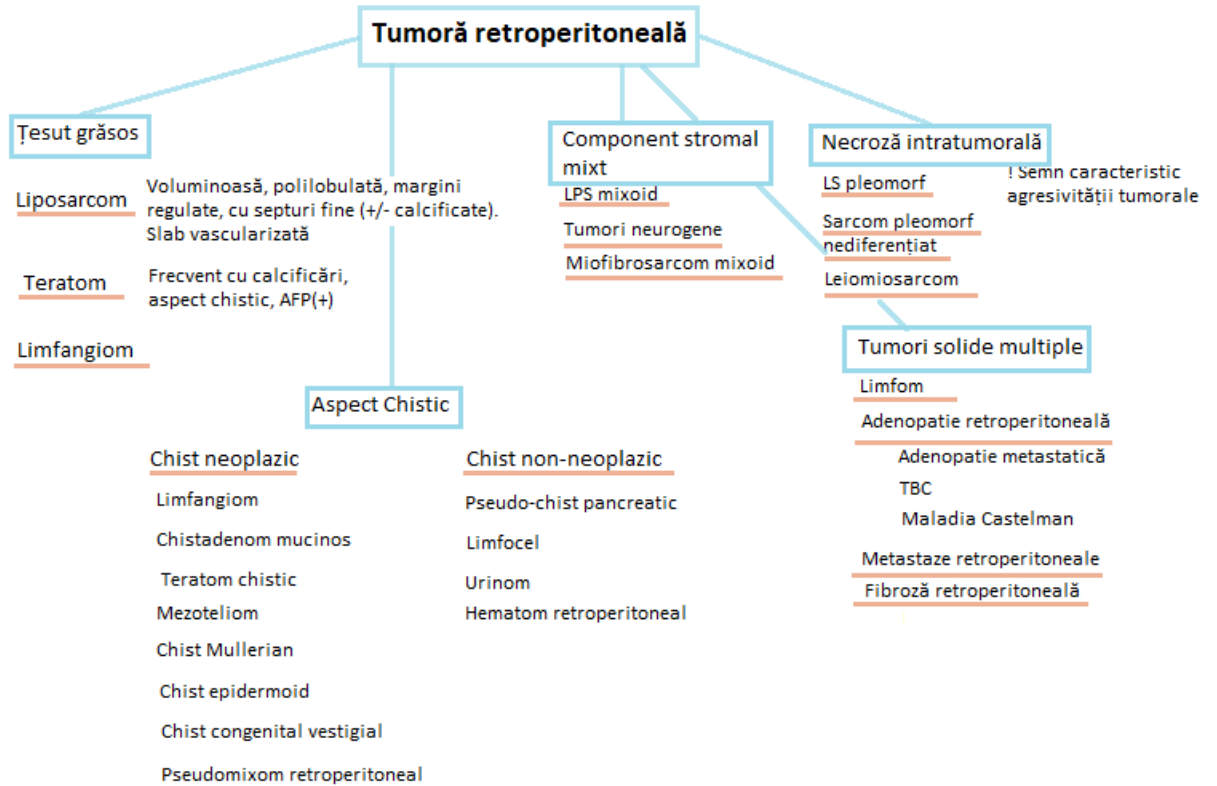
Appendix No. 2

THE DIAGNOSIS AND MANAGEMENT OF THE RETROPERITONEAL MASSES



Appendix No. 3

PREDICTIVE ASSESSMENT OF RETROPERITONEAL TUMOR BASED ON IMAGING FEATURES



AFP - alfa-fetoproteină; LPS - Liposarcom; TBC - tuberculoză

LIST OF SCIENTIFIC PUBLICATIONS AND EVENTS
which presented the research results of the doctoral thesis in medical sciences,
with the theme "Valuable and comparative estimation of diagnostic methods of
primitiveretroperitoneal tumors", conducted within the Department of Oncology
of the State University of Medicine and Pharmacy "Nicolae Testemitanu" of the Republic
of Moldova
Victor Șchiopu

SCIENTIFIC PAPERS

- **Articles in accredited national scientific journals:**
 - **articles in category B magazines**
 1. **Șchiopu V**, Scerbatiuc-Condur C, Ghidirim N. Comparative analysis of imaging investigations in the diagnosis of retroperitoneal tumors. *Mold Med J.* 2022;65(1):36-39. <https://doi.org/10.52418/moldovan-med-j.65-1.22.06>.
 2. **Șchiopu V.**, Țurcanu V., Ghidirim, N. Sonographic approach to the tumours of retroperitoneal space. În: *Moldovan Medical Journal.* 2021, nr. 6(64), pp. 37-40. ISSN 2537-6373.10.52418/moldovan-med-j.64-6.21.07
 3. **Șchiopu V.** Diagnosticul tumorilor retroperitoneale primitive: reviu literaturii. În: *Buletinul Academiei de Științe a Moldovei. Științe Medicale.* 2018, 2-3(59-60), 125-132. ISSN 1857-0011.
- **Abstracts/theses in the works of national and international scientific conferences**
- Gutul C., **Șchiopu V.** Histological and immunohistochemical profile of primary retroperitoneal tumors. In: *AbstractBook "Medespera 2022", International Medical Congress. Chișinău, 2022*, p. 415.
- Ciorici V., **Șchiopu V.**, et al. Primitive retroperitoneal tumors – problems of diagnosis and treatment. In: *Cercetarea în biomedicină și sănătate: calitate, excelență și performanță.* 20-22 octombrie 2021, Chișinău. Chișinău, Republica Moldova: 2021, p. 247. ISBN 978-9975-82-223-7 (PDF).
- Simcov V., **Șchiopu V.**, Vîrlan M. Sarcoamele retroperitoneale (reviu literaturii). In: *Congresul consacrat aniversării a 75-a de la fondarea Universității de Stat de Medicină și Farmacie „Nicolae Testemitanu”.* 21-23 octombrie 2020, Chișinău. Chișinău: USMF, 2020, p. 445.
- **Șchiopu V.** The Neurogenic Retroperitoneal Primitive Tumors. In: *AbstractBook "Medespera 2018", International Medical Congress. Chișinău, 2018*, pp.114-115.
- Butnari V., **Șchiopu V.** Primary Retroperitoneal Liposarcoma. In: *AbstractBook "Medespera 2018", International Medical Congress. Chișinău, 2018*, p. 115.
- **Șchiopu V.**, Bacalîm L., Catrinici V., Antoci L., Ghidirim N. Necroza glandei suprarenale unilaterale. Prezentare de caz. În: *Conferința științifică „Nicolae Anestiadi – nume etern al chirurgiei basarabene”.* *Arta Medica, ediție specială.* 2019, 3(72), pp.167-168. ISSN 1810-1852.
- **Șchiopu V.**, Butnari V., Godoroja V., Antoci L., Duda B., Ghidirim N. Sarcoamele retroperitoneale – Experiența unui singur Centru. În: *Al XIII-lea Congres al Societății de*

Endoscopie, Chirurgie miniminvasivă și Ultrasonografie "V.M.Guțu" din Republica Moldova. Arta Medica, ediție specială. 2019, 3(72), p. 82. ISSN 1810-1852.

- Veverița I., **Șchiopu V.** Tumorile neuroendocrine ale tractului digestiv. În: *Congresul consacrat aniversării a 75-a de la fondarea Universității de Stat de Medicină și Farmacie „Nicolae Testemițanu”*. Chișinău, 2020, p. 462.
- **Șchiopu V.**, Antoci L., Godoroja V., Ghidirim N. Tumorile retroperitoneale primitive, experiența unui singur centru. În: *Buletinul Academiei de Științe a Moldovei. Științe Medicale*. 2020, 4(68), pp. 185-186. ISSN 1857-0011.

- **Participation with communications in scientific forums: International:**

2. **Șchiopu V.**, Antoci L., Corobcean N., Ghidirim N. Tumorile retroperitoneale primitive – review al literaturii. *Reuniunea Internațională de Chirurgie*. Iași, 4 – 7 octombrie 2017.
3. **Șchiopu V.**, Antoci L., Ghidirim N. The retroperitoneal sarcomas – the experience of our clinic. *Congresul Național de Chirurgie*. Sinaia, 6-9 iunie 2018.

National:

4. **Șchiopu V.** Tumorile retroperitoneale - probleme de diagnostic în medicina contemporană. *Conferința științifică anuală în cadrul Zilelor USMF "Nicolae Testemițanu"*. Chișinău, 19 octombrie, 2017.
5. **Șchiopu V.** Diagnosticul și tratamentul tumorilor retroperitoneale limfoganglionare și din țesutul conjunctiv. *Conferința științifică anuală în cadrul Zilelor USMF "Nicolae Testemițanu"*. Chișinău, 18 octombrie, 2018.
6. **Șchiopu V.**, Antoci L., Catrinici V..Patologia Castelman cu afectarea ganglionilor limfatici retroperitoneali – imitator al tumorilor retroperitoneale. Conferința științifică anuală în cadrul Zilelor USMF "Nicolae Testemițanu". Chișinău, 17 octombrie, 2019.
7. **Șchiopu V.** Tumorile retroperitoneale primitive, experiența unui singur centru. *Al V-lea congres al Oncologilor din Republica Moldova*. Chișinău, 8-9 octombrie, 2020.

- **Participation with posters in scientific forums:**

National:

8. Simcov V., **Șchiopu V.**, Vîrlan M. Retroperitoneal sarcomas (literature review). *Conferința științifică anuală în cadrul Zilelor USMF "Nicolae Testemițanu" Congresul este consacrat și Zilei Științei pentru Pace și Cercetare*. Chișinău, 21-23 octombrie 2020.

Innovative certificates:

1. **ȘCHIOPU, V.**; **ANTOCI, L.**; **TURCANU, V.**; **GHIDIRIM, N.** *Utilizarea tomografiei computerizate și USG în determinarea volumului intervenției chirurgicale în cazul tumorilor retroperitoneale*. Certificat de inovator nr.5860; 05.10.2021.
2. **ȘCHIOPU, V.**; **ANTOCI, L.**; **TURCANU, V.**; **GHIDIRIM, N.** *Profilul imunohistochimic al tumorilor retroperitoneale primitive*. Certificat de inovator nr.5861; 05.10.2021.
3. **ȘCHIOPU, V.**; **ANTOCI, L.**; **TURCANU, V.**; **GHIDIRIM, N.** *Tumorile retroperitoneale – algoritm diagnostic-curativ optimizat*. Certificat de inovator nr.5862; 06.10.2021.

4. **ȘCHIOPU, V.; ANTOCI, L.; TURCANU, V.; GHIDIRIM, N.** *Algoritmul aprecierii corelației semnelor imagistice specifice și tipul TRP.* Certificat de inovator nr.5863; 06.10.2021.

LIST OF ABBREVIATIONS

AFP – alfa fetoprotein
Ao – Aorta
APR – Previous Pararenal Space
AUC – Area under ROC curve
CCD IO – Consultative Diagnostic Center of the Oncology Institute
CD56 – Neuronal cell adhesion molecule (NCAM)
CD99 – Differencing cluster 99
CD31 – Differencing cluster 31 (PECAM-1)
CD34 – Differencing cluster 34
CDK4 – Cycline Dependent Kinase 4
CMM – Average quality of the diagnostic model
CREPT – cell-cycle related and expression-elevated protein, named as RPR1BCT – computed tomography
DDL – dedifferentiated liposarcoma
EMA – Epithelial membrane antigen
FLI-1 - Leukemia integration 1 transcription factor
FNA – fine needle aspiration
FNCLCC – Fédération Nationale des Centres de Lutte Contre Le Cancer
GIST – Gastrointestinal stromal tumor
H&E – Hematoxyline and eosin
HHF 35 – Actin-specific mon oclonal muscle antibody
HMGA1 și HMGA2 - high mobility group A 1 și 2
i.v. – intra-venous
IC – Confidence Interval
ICH - immunohistochemistry
IMSP IO – Medical and Sanitary Institution Oncology Institute
MRI – Magnetic Resonance Imaging
Ki67 – proliferate markers
LNH – Non-Hodgkin Limfom
LS – liposarcoma
MDM 2 – p53 gene activity regulating oncoprotein
MPNST –Malignant peripheral nerve sheath tumors
OMS – World Health Organization
PCNA – Nuclear proliferation antigen
PPR – Posterior perirenal space
RMS – rabdomiosarcoma
ROC – Receiver Operating Characteristics
RPS – retroperitoneal sarcoma

S-100 – peripheral nerve sheath superficial protein

SATB – identified marker in metastases of colorectal carcinoma

SMA – smooth muscle actin

SRP – Retroperitoneal space

STS – Soft tissue sarcomas

TLS/EWS-CHOP

TNF – Tumor necrosis factor

PRT – Primitive retroperitoneal tumorUSG

– ultrasonography

VCI – Inferior vena cavaVim

– vimentin