

COLESTATIC CHOLEMIA IN INFLAMMATORY COMPLICATIONS OF BILIARY LITHIASIS, STAGE TREATMENT OPTIONS

Liuba Streltov

SUMF "Nicolae Testemitanu", Chisinau, Republic of Moldova

Background

The rate of benign inflammatory complications in gallstones varies with the prevalence of acute cholecystitis (ALC) in 10-15% and cholangitis (CL) in 2-4% of cases, etc. Statistics show that in pre-existing conditions, in 10-15% of cases, cholestatic jaundice (CJ) is associated.

Keywords

gallstones, acute cholecystitis, cholangitis, Mirizzi syndrome

Purpose

Analysis of the experience of treatment of patients with inflammatory complications of gallstones associated with cholestatic jaundice.

Material and methods

Options of approach of 67 patients with inflammatory complications, selected from 191 patients with complicated gallstones and associated cholestatic cholemia, treated in the hospital "St. Arch. Michael" are presented.

Results

It was found: I gr. - ALC associated with choledocholithiasis (CD) and CJ (16) - destructive form (13), simple form (3), II gr. - ALC associated with stenosis of the sphincter Oddi and CJ (19) - destructive form (6), simple form (13), III gr. - Destructive ALC, CL and CJ (12), IV gr. - CD, CL and CJ (7), V gr. - Mirizzi syndrome, CL and CJ (13). Management: in simple ALC, compliant with drug treatment (16) - endoscopic PST in 48-72 hours, cholecystectomy over 3-4 days after decompression. In destructive ALC (31) at the first stage decompression was performed by cholecystectomy (laparoscopic-10, classic-21) with external drainage of the bile ducts, in the second stage - PST if necessary. In CD and CL - PST with litextraction - complete solution. In Mirizzi syndrome at stage I - PST with drainage of the bile ducts, in stage II - bile duct reconstruction interventions over 3-4 days after decompression, adjusted to the type of obstruction. Mortality -0%. Morbidity - 5 cases (7.4%).

Fig.1 Inflammatory complications in gallstones

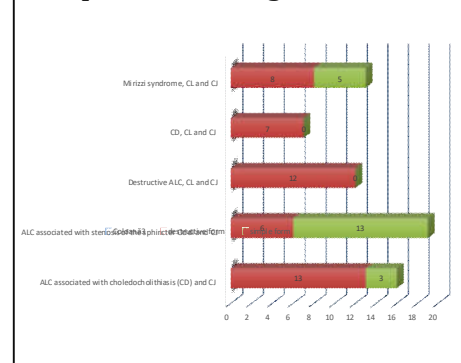


Fig.2 Acute destructive cholecystitis

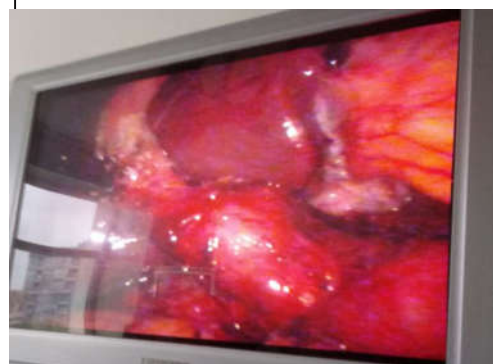

Fig.3 PST Stone extraction with balloon catheter

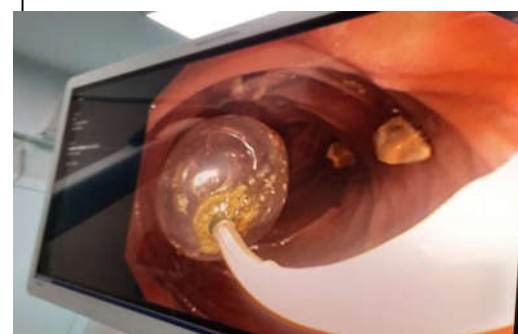
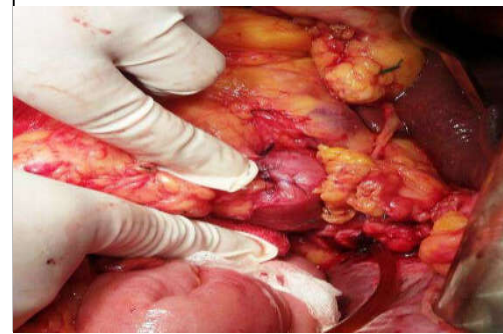


Fig.4 Choledoco-duodeno anastomosis in Mirizzi syndrome



Conclusions

Individualization of the terms and type of surgery, depending on the morphological form of the disease and homeostatic liver disorders, improves the results of treatment of patients with inflammatory complications and cholestatic jaundice in gallstones. Regardless of the type of approach, the primary goal in the first stage is biliary decompression.