

Doctoral school in the field of Medical Sciences

With the title of manuscript
C.Z.U: 616.216.1-07-089.844(043.2)

MIGHIC Alexandr

**MAXILLARY SINUS PATHOLOGY TREATMENT IN IMPLANT-PROSTHETIC
REHABILITATION**

323.01 – STOMATOLOGY


Summary of the Doctoral Thesis in Medical Sciences

Chişinău, 2024

The thesis was developed at the Department of oral and maxillofacial surgery and oral implantology „Arsenie Guțan” Nicolae Testemițanu State University of Medicine and Pharmacy of the Republic of Moldova.

Scientific coordinator

Sîrbu Dumitru,
PhD med. sci, Associate Professor



Guidance committee members:

Maniuc Mihail
PhD med. sci, University Professor



Topalo Valentin

PhD med. sci, University Professor




The defense will take place on 28.02.2024 14:00 in the premises of Nicolae Testemițanu State University of Medicine and Pharmacy, bd. Ștefan cel Mare și Sfânt, 165, office 204, in the meeting of the Commission for public defense of the doctoral thesis, approved by decision of the Scientific Council of the Consortium of 05.12.23 (minutes no. 29).

The composition of the Commission for public defence of the defence of the doctoral thesis:

President:

Chele Nicolae,
PhD med. sci, University Professor



Secretary:

Spinei Iurie
PhD med. sci, Associate Professor




Members:

Sîrbu Dumitru,
PhD med. sci, Associate Professor




Maniuc Mihail,
PhD med. sci, University Professor



Agop Forna Doriana,
PhD med. sci, Associate Professor,
official referent




Zabolotnii Dumitru,
PhD med. sci, official referent



Author

Mighic Alexandr



CONTENTS

CONCEPTUAL FRAMEWORK OF THE RESEARCH	4
THESIS CONTENT	6
1. ASPECTS OF PHYSIOLOGY AND PATHOLOGY OF THE MAXILLARY SINUS IN THE CONTEXT OF IMPLANT-PROSTHETIC REHABILITATION.....	6
2. MATERIAL AND RESEARCH METHODS.....	7
2.1. Study Design.....	7
2.2. Investigation Methods.....	8
2.3. Treatment Methods	9
3. RESULTS.....	9
DISCUSSIONS	13
GENERAL CONCLUSIONS	15
PRACTICAL RECOMMENDATIONS:	16
BIBLIOGRAPHY.....	17
LIST OF PUBLICATIONS AND PARTICIPATIONS IN SCIENTIFIC FORUMS.....	19

MIGHIC Alexandr

MAXILLARY SINUS PATHOLOGY TREATMENT IN IMPLANT-PROSTHETIC REHABILITATION

323.01 – STOMATOLOGY

Summary of the Doctoral Thesis in Medical Sciences

Aprobat spre tipar: 31.01.2024

Hârtie ofset. Tipar digital.

Coli de tipar: 1.75

Formatul hârtiei: 60x84 ¹/₁₆

Tiraj: 10 ex.

Comanda nr.: 14

Tipărit la "Tipografia Nr.1" SRL
MD-2001, Chişinău, str. 31 August 1989, 46
Tel: (+373) 069 104 435

CONCEPTUAL FRAMEWORK OF THE RESEARCH

Actuality and importance of the studied problem

Prosthetic rehabilitation has become a method of choice in treating patients without teeth (edentulous patients). Following tooth extraction, there is a progressive atrophy of the alveolar process, and often, specialists face a deficiency in bone support. In the lateral areas of the upper jaw, besides the atrophy of the alveolar process at the crown, there is also pneumatization of the maxillary sinus with resorption of the alveolar crest at the apical part. The most commonly used method for bone augmentation in the lateral areas of the upper jaw is the sinus lift (SL) procedure, which has proven its high efficiency and predictability over time. However, one of the primary conditions for performing SL is that the maxillary sinus (SM) must be intact. At the same time, there needs to be more data in the specialized literature regarding the criteria and boundaries for assessing the functional state of the maxillary sinus.

It is well-established that the primary reason for postoperative complications of SL is the pathological state of the maxillary sinus before the operation [6, 7]. Sinus mucosal thickening is found in 23.7%-28.2% of patients, mucosal cysts in 8.9%-19.4%, and acute sinusitis in 3.6%-6.5% of patients seeking implant-prosthetic rehabilitation [8, 9]. Beaumont (2005) reported that 40% of patients seeking SL have pathology of the maxillary sinus [5]. Analyzing the functional state of the maxillary sinus, the thickness of the Schneiderian mucosa, and the permeability of the natural ostium play a vital role in determining the indications and contraindications for SL.

The issues and questions highlighted above, as well as many others encountered in our routine practice and by other specialists in the field, have motivated us to initiate this study.

The purpose of the Study

To evaluate the optimal treatment methods for maxillary sinus conditions in pre-implant preparation and to develop recommendations for the insertion of endosseous dental implants involving the operated maxillary sinus.

Research Objectives

Develop a methodology for clinical and paraclinical examination of patients indicated for the sinus lift procedure.

Study the advantages and disadvantages of existing surgical techniques for pre-implant preparation in patients with maxillary sinus conditions.

Evaluate the role of the osteomeatal complex in surgical treatment planning.

Assess the role of anatomical deviations of the endonasal structures in the treatment of sinusitis and the planning of the sinus lift.

Develop a method to clean the maxillary sinus in combination with a sinus lift in a single surgical stage through an intraoral approach.

Scientific research methodology

A controlled clinical study was conducted with randomized patient selection, comprising a total of 128 participants. The research subjects were divided into two groups. The study group included 65 patients undergoing sinus lifting with the presence of maxillary sinus pathology, where functional endoscopic sinus surgery clearance was performed, followed by implant-prosthetic rehabilitation. The control group consisted of 63 patients who underwent surgical treatment following modified Caldwell-Luc procedure, with subsequent implant-prosthetic rehabilitation.

• Participations with posters at scientific forums:

✓ national level

27. **Mighic, A.**, Sîrbu, D., Țiple, T. Micoza sinusului maxilar. Prezentare de poster la *Conferința anuală dedicată aniversării a 70 de ani a universității*. Chișinău, octombrie 2015.

28. **Mighic, A.**, Sîrbu, D., Țiple, T. Tratatamentul complicațiilor cauzate de propulsarea materialului endodontic în sinusul maxilar. *Zilele universității de stat de medicină și farmacie Nicolae Testemițanu*. Chișinău, Republica Moldova, 18-21 octombrie, 2016.

29. **Mighic, A.**, Țiple, T., Strîșca, S. Effectiveness of causativ tooth extraction in maxillary sinusitis of dental origin. *Congresul "International Medical Congress for Students and Young doctors"*, 7-th edition, Chișinău, Republica Moldova, 2018.

• Invention patents, patents, registration certificates, materials at invention exhibitions

30. Sîrbu, D., Topalo, V., Chele, N., **Mighic, A.**, Ghetiu, A. Metodă de abord miniinvaziv în sinuslifting lateral. *Certificat de inovator nr. 5487*; 04.12.2015.

31. Sîrbu, D., Topalo, V., Chele, N., **Mighic, A.**, Ghetiu, A. Metodă de utilizare a materialului aloplastic Kolapol KP-3LM pentru menajarea membranei Schneider în sinuslifting lateral cu implantare simultană. *Certificat de inovator nr. 5488*; 04.12.2015.

32. Sîrbu, D., Strîșca, S., Caldarari, S., **Mighic, A.**, Ghețiu, A. Metodă de poziționare și ghidare a axului de inserare a implantelor în protocolul Bredent Sky Fast and Fixed. *Certificat de inovator nr. 5606*; 21.08.2017.

33. Sîrbu, D., Strîșca, S., Caldarari, S., **Mighic, A.**, Ghețiu, A. Accesul chirurgical menajant în protocolul Bredent Sky Fast and Fixed cu utilizarea șabloanelor chirurgicale. *Certificat de inovator nr. 5604*; 15.05.2017.

34. **Mighic, A.**, Sîrbu, D., Mostovei, A. Metoda de tratament a sinuzitei fungice în combinație cu sinuslifting lateral prin acces endooral. *Certificat de inovator nr. 5994*; 22.02.23.

Mighic, A., Sîrbu, D., Mostovei, A. Metoda de acces osteoplastic către sinus maxilar prin acces endooral. *Certificat de inovator nr. 5995*; 22.02.23

- **Participations with oral communications at scientific forums:**

- ✓ **international level meetings**

13. Sîrbu, D., Strîșca, S., **Mighic, A.**, Ghețiu, A. Reabilitarea pacienților cu defecte, deformații și atrofii severe ale maxilarelor. *Congres UNAS ediția a XXII-a cu tema "Tulburări în sfera aparatului dento-maxilar cu impact în activitatea de cabinet"*. București, Romania, 3-6 octombrie, 2018.

14. Ghețiu, A., Sîrbu, D., **Mighic, A.**, Strîșca, S. Evaluarea defectelor de creastă alveolară a maxilarului superior în vederea reabilitării implanto-protetice. *Congres UNAS ediția a XXII-a cu tema "Tulburări în sfera aparatului dento-maxilar cu impact în activitatea de cabinet"*. București, Romania, 3-6 octombrie, 2018.

15. **Mighic, A.**, Sîrbu, D., Topalo, V., Ghețiu, A., Strîșca, S. Operația de sinus lifting în prezența patologiei sinusului maxilar. Particularitățile protocolului preoperator, operator și a perioadei postoperatorii. *Congres UNAS ediția a XXII-a cu tema "Tulburări în sfera aparatului dento-maxilar cu impact în activitatea de cabinet"*. București, Romania, 3-6 octombrie, 2018.

16. **Mighic, A.**, Sîrbu, D. Sinuslifting în prezența patologiei sinusului maxilar. *Simpozionul anual "Zilele stomatologiei galatene. Interferențe multidisciplinare în medicina dentară"*. Galați, Romania, 8-9 iunie, 2018.

17. **Mighic, A.**, Sîrbu, D., Topalo, V., Ghețiu, A., Strîșca, S. Tratatamentul chirurgical al sinuzitei maxilare de origine odontogenă. *Congres UNAS ediția a XXIII-lea cu tema "Stomatologia, între clasic și modern"*. București, Romania, 2-5 octombrie 2019.

- ✓ **national level meetings**

18. **Mighic, A.** Tratatamentul endoscopic asistat a patologiei sinusului maxilar în pregătirea preimplantării. *Conferința științifică anuală a specialiștilor IMU "Actualități și controverse în managementul urgențelor medico-chirurgicale"*. Chișinău, 2016.

19. **Mighic, A.**, Sîrbu, D., Tiple, T. Tratatamentul complicațiilor cauzate de propulsarea materialului endodontic în sinusul maxilar. *Zilele Universității de Stat de Medicină și Farmacie „Nicolae Testemițanu”*. Chișinău, Republica Moldova, 18-21 octombrie, 2016.

20. **Mighic, A.** Chisturi mucoale a sinusului maxilar. Diagnostic diferențial și conduita de tratament. *Conferința Științifico-Practică națională cu participare internațională consacrată aniversării a 90 de ani de la nașterea ilustrului savant Nicolae Testemițanu*, organizată de Catedra de chirurgie oro-maxilo-facială și implantologie orală "Arsenie Guțan". Chișinău, Republica Moldova, 19 septembrie, 2017.

21. **Mighic, A.** Conduita tratamentului chirurgical la propulsarea materialului endodontic în sinusul maxilar. *Conferința științifică anuală a tinerilor specialiști cu genericul "Performanțe și perspective în urgențele medico-chirurgicale" consacrată aniversării de 60 ani a IMSP IMU*, Chișinău, 2017.

22. **Mighic, A.**, Sîrbu, D. Diagnosticul și tratamentul sinuzitei fungice maxilare. *Zilele Universității de Stat de Medicină și Farmacie Nicolae Testemițanu*. Chișinău, Republica Moldova, 15-19 octombrie, 2018.

23. **Mighic, A.**, Sîrbu, D. Tratatamentul chisturilor mucozale al sinusului maxilar. *Conferința științifică anuală a tinerilor specialiști din cadrul IMSP IMU „Performanțe și perspective în urgențele medico-chirurgicale"*. Chișinău, 18 mai 2018.

24. **Mighic, A.**, Sîrbu, D. Operația sinuslifting în prezența patologiei sinusului maxilar. *Al XIX-lea congres național cu participare internațională al asociației stomatologilor din Republica Moldova. De la prevenție spre avansare*. Chișinău, 2018.

25. **Mighic, A.**, Sîrbu, D. Managementul sinuzitei fungice de origine odontogenă. *Zilele Universității de Stat de Medicină și Farmacie „N. Testemițanu”*. Chișinău, 2019.

26. **Mighic, A.** Sinuslifting lateral în prezența chisturilor mucozale ale sinusului maxilar. *Conferința științifică cu participare internațională în memoria distinsului savant, profesor universitar Valentin Topalo*. Chișinău, 2023.

The study groups were compared based on the following outcome criteria:

- Lund-Kennedy scale assessment;
- OMU (osteomeatal unit) status assessment;
- Sinus mucosa thickness assessment;
- Persistence of postoperative pain (days);
- Duration of the surgical intervention (minutes);
- Healing duration (months);
- Presence/absence of anterior maxillary sinus wall defect.

Approval for the thesis topic was obtained during the Scientific Council meeting of the "Nicolae Testemițanu" State University of Medicine and Pharmacy (USMF), number 6, dated November 1, 2016. Positive feedback from the Research Ethics Committee for the study was obtained during the session on June 17, 2016.

Scientific Novelty and Originality

A step-by-step methodology for diagnostic rhinoscopy of sinus lifting candidates was developed.

A step-by-step algorithm for CBCT examination of sinus lifting candidates was created.

It was demonstrated for the first time that OMU blockage in maxillary sinusitis is usually secondary and occurs due to increased swelling of the sinus membrane.

It was proven that anatomical deviations of endonasal structures are important factors but not determinants in the pathogenesis of sinusitis.

The first endooral osteoplastic access to the maxillary sinus was developed.

A novel method for treating fungal sinusitis in combination with sinus lifting through endooral access was proposed.

Guidelines for the treatment of sinus lifting candidates with maxillary sinus conditions were developed.

Implementation of Scientific Results

The study results are applied in clinical practice and in the teaching process at the Department of Oro-Maxillofacial Surgery and Oral Implantology "A. Guțan" of USMF "Nicolae Testemițanu". Implementation details are provided in the Annex.

Approval of Scientific Results: The results were presented in 27 active participations at national and international scientific forums, including various conferences and congresses.

Thesis Publications: The main thesis materials were published in 2 articles with Impact Factor, 4 articles in category B journals, 3 articles in category C journals, 3 abstracts in international scientific conference proceedings, 1 single-author publication, and 2 innovation certificates.

Thesis Volume and Structure: The thesis text consists of 136 pages of processed computer-based content, including a list of abbreviations, introduction, 4 chapters, general conclusions, practical recommendations, bibliography with 219 sources, and 2 annexes. The illustrative material includes 16 tables, 50 figures, and 2 formulas.

Keywords: endoscopic sinus surgery, sinusotomy, sinus lifting, osteomeatal unit, sinus membrane, fungal sinusitis, odontogenic sinusitis, mucosal cyst, mucocele, computed tomography.

THESIS CONTENT

1. ASPECTS OF PHYSIOLOGY AND PATHOLOGY OF THE MAXILLARY SINUS IN THE CONTEXT OF IMPLANT-PROSTHETIC REHABILITATION

Spread of the inflammatory process from maxillary molars, premolars, and occasionally canines to the maxillary sinus can be explained by their close anatomical relationship. A significant part of maxillary sinus (MS) pathology is correlated with periapical conditions and endodontic treatment maneuvers of the upper dental arch, causing trauma to the lower wall of the maxillary sinus both during and after various surgical manipulations performed on teeth with a sinus relationship [31–33].

The management of maxillary sinusitis of odontogenic origin (MSO) has two primary goals: first, to handle the inflammation and infection in the sinus and second, to address the cause of the infection in the maxillary sinus (be it extraction, apical resection, or cystectomy, as needed). If either of these objectives is unmet, a vicious cycle ensues, and the clinical picture of the disease remains unresolved [96].

Traditionally, MSO is treated through the radical Caldwell-Luc antrostomy. Even though the radical Caldwell-Luc procedure was proposed two centuries ago, many authors still consider this approach to be the only solution for treating MSO [7–9].

However, there are very few studies that elucidate the endoscopic approach in the treatment of MSO. This issue was first reported by Lopatin A. and Sysolyatin P. in 2002 in the article titled "Chronic sinusitis of odontogenic origin. Is external access necessary?". The authors reported a success rate of 94.7% over a 3-year follow-up period and concluded that external access is not required for treating MSO [10]. The high success rate of the endoscopic approach in treating maxillary sinusitis of odontogenic origin has been confirmed by several authors.

After undergoing sinus lift surgery, all patients temporarily experience sinusitis. This is a natural response to the trauma from the surgery. For those without any unusual structures inside their nose, this issue clears up quickly. This innate ability of the maxillary sinus mucosa to restore its normal homeostasis after lifting the sinus floor is termed "sinusal compliance". When preoperative conditions are favourable, high compliance and a reduced risk of postoperative complications are noted.

For patients with anatomical or functional deviations (low compliance), transitional sinusitis following sinus lift surgery can become irreversible, leading to acute purulent sinusitis or chronicity. Low compliance requires the surgeon to have extensive knowledge of maxillary sinus pathology and indicates a high risk of complications if an inappropriate treatment approach is chosen.

In all patients undergoing sinus lift surgery, transient sinusitis develops, which is the body's physiological protective response to trauma.

In patients without any anatomical deviations in the internal nasal structures, the condition mentioned above typically resolves on its own in a short period. This innate ability of the maxillary sinus mucosa to restore its average balance after elevation of the sinus floor is referred to as "sinusal compliance." When preoperative conditions are favourable, there is high compliance and a decreased risk of postoperative complications.

For patients with anatomical or functional deviations (low compliance), the transient sinusitis following a sinus lift surgery might become irreversible, leading to purulent acute sinusitis or chronicization of the condition. Low compliance demands extensive knowledge in maxillary sinus pathology from the surgeon and indicates a high risk of complications if the wrong treatment strategy is chosen.

LIST OF PUBLICATIONS AND PARTICIPATIONS IN SCIENTIFIC FORUMS

at which the results of the researches for the doctoral thesis in Medical Sciences with the topic „**Maxillary sinus pathology treatment in implant-prosthetic rehabilitation**”, performed at Stomatology department, Nicolae Testemițanu State University of Medicine and Pharmacy, were presented:

Publications in scientific journals:

✓ articles in ISI, SCOPUS and other international databases *

1. Hîțu, D., Chele, N., Cabac, V., **Mighic, A.**, Bădărău, L. Maxillary Sinusitis of Odontogenic Origin. In: *Europe. Online Journal of Complementary & Alternative Medicine*. June, 2021, 6(1). ISSN: 2644-2957. doi: 10.33552/OJCAM.2021.06.000626 (IF: **0.489**).

2. Hîțu, D., Chele, N., Cabac, V., **Mighic, A.**, Bădărău, L. Maxillary sinusitis of odontogenic origin. In: *European Journal of Oral and Maxillofacial Surgery*. 2022, 6(1), pp. 11-16. ISSN 2532-3466. doi: 10.23736/S2532-3466.20.00248-9.

• Publications in accredited national scientific journals:

✓ Articles in Category B journals

3. **Mighic, A.**, Sirbu, D., Ghețiu, A., Țiple, T. Tratatamentul chirurgical miniinvaziv al comunicărilor oro-sinusale. În: *Medicina Stomatologică.*, 2015, 3(36), pp.7-10. ISSN 1857-1328.

4. Sirbu, D., Topalo, V., Chele, N., Suharschi, I., **Mighic, A.**, Ghețiu, A., Sobetchi, A., Strișca, S. Regenerarea osoasă în reabilitarea implanto-protetică a pacienților cu defecte ale oaselor maxilare. În: *Medicina Stomatologică.* 2016, 1-2(38-39), pp. 33-42. ISSN 1857-1328.

5. **Mighic, A.**, Sirbu, D., Țiple, T. Chisturi mucozale a sinusului maxilar. Diagnostic diferențial și controverse în tratament. În: *Medicina Stomatologică.* 2017, 3(44), pp. 34-38. ISSN 1857-1328.

6. Sirbu, D., Suharschi, I., Strișca, S., **Mighic, A.**, Ghețiu, A., Mostovei, M. Perspectivele contemporane ale utilizării CBCT-ului în patologie oro-maxilo-facială. În: *Medicina Stomatologică.* 2017, 3(44), pp. 16-24. ISSN 1857-1328.

✓ Articles in Category C journals

7. **Mighic, A.** Tratatamentul sinuzitei maxilare de origine odontogenă. În: *Medicina Stomatologică.* 2019, 4(53), pp. 36-45. ISSN 1857-1328.

8. Barcaru, D., Hîțu, D., **Mighic, A.** Sinuzita maxilară neodontogenă 2019. În: *Culegere de rezumate științifice. Congresul consacrat aniversării a 75-A de la fondarea USMF „Nicolae Testemițanu”* Chișinău, 2020, p. 693. ISSN 978-9975-118-61-3.

9. **Mighic, A.**, Sirbu, D., Mostovei, A., Dabija, I. Lateral sinus floor elevation with simultaneous mucosal cysts management. În: *Moldovan Journal of Health Sciences. Revista de Științe ale Sănătății din Moldova.* 2023, 2(10), pp. 32-39. ISSN 2345-1467. <https://doi.org/10.52645/MJHS.2023.2.06>.

• Abstracts/summaries/theses in national and international scientific conference papers

10. Ghetiu, D., Sirbu, D., Topalo, V., **Mighic, A.**, Suharschi, I., Mostovei, A., Rusnac, C., Strisca, S. Tissue engineering with Platelet-Rich Fibrin in oral region. In: *Clin. Oral Impl. Res.* 2015, 26(S12), p. 205. (IF **5.021**).

11. Sirbu, D., Topalo, V., **Mighic, A.**, Ghetiu, A., Popovici, V., Mostovei, M., Strisca, S. Aspecte în restabilirea morfo-funcțională a pacienților edentați la mandibulă cu deficit osos prin intermediul implantelor dentare. In: *Al XX-lea Congres Internațional al UNAS.* București, Romania, 05-08 octombrie, 2016, p. 32.

12. **Mighic, A.**, Țiple, T., Strișca, S. Effectiveness of causativ tooth extraction in maxillary sinusitis of dental origin. In: *Congresul "International Medical Congress for Students and Young doctors"*, 7-th edition, Chișinău, 3-5 mai, 2018, pp. 245-246.

17. Saibene AM, Collurà F, Pipolo C, Bulfamante AM, Lozza P, Maccari A, et al. Odontogenic rhinosinusitis and sinonasal complications of dental disease or treatment: prospective validation of a classification and treatment protocol. *European Archives of Oto-Rhino- Laryngology* 2019;276:401–6. <https://doi.org/10.1007/s00405-018-5220-0>.
18. Longhini AB, Ferguson BJ. Clinical aspects of odontogenic maxillary sinusitis: a case series. *Int Forum Allergy Rhinol* 2011;1:409–15. <https://doi.org/10.1002/alr.20058>.
19. Hajjiannou J, Koudounarakis E, Alexopoulos K, Kotsani A, Kyrmizakis DE. Maxillary sinusitis of dental origin due to oroantral fistula, treated by endoscopic sinus surgery and primary fistula closure. *J Laryngol Otol* 2010;124:986–9. <https://doi.org/10.1017/S0022215110001027>.
20. Huang Y-C, Chen W-H. Caldwell-Luc Operation Without Inferior Meatal Antrostomy: A Retrospective Study of 50 Cases. *Journal of Oral and Maxillofacial Surgery* 2012;70:2080–4. <https://doi.org/10.1016/j.joms.2011.09.044>.
21. Sathananthar S, Nagaonkar S, Paleri V, Le T, Robinson S, Wormald P-J. Canine Fossa Puncture and Clearance of the Maxillary Sinus for the Severely Diseased Maxillary Sinus. *Laryngoscope* 2005;115:1026–9. <https://doi.org/10.1097/01.MLG.0000162651.22019.4A>.
22. Närkiö-mäkelä M, Qvarnberg Y. Endoscopic Sinus Surgery or Caldwell-Luc Operation in the Treatment of Chronic and Recurrent Maxillary Sinusitis. *Acta Otolaryngol* 1997;117:177–80. <https://doi.org/10.3109/00016489709124115>.
23. Närkiö-mäkelä M, Qvarnberg Y. Endoscopic Sinus Surgery or Caldwell-Luc Operation in the Treatment of Chronic and Recurrent Maxillary Sinusitis. *Acta Otolaryngol* 1997;117:177–80. <https://doi.org/10.3109/00016489709124115>.
24. Senior BA, Kennedy DW, Tanabodee J, Kroger H, Hassab M, Lanza D. Long-term Results of Functional Endoscopic Sinus Surgery. *Laryngoscope* 1998;108:151–7. <https://doi.org/10.1097/00005537-199802000-00001>.
25. Chandra RK, Pearlman A, Conley DB, Kern RC, Chang D. Significance of osteomeatal complex obstruction. *J Otolaryngol Head Neck Surg* 2010;39:171–4.
26. Toskala E, Rautiainen M. Effects of surgery on the function of maxillary sinus mucosa. *European Archives of Oto-Rhino-Laryngology* 2005;262:236–40. <https://doi.org/10.1007/s00405-004-0773-5>.
27. Myller J, Toppila-Salmi S, Torkkeli T, Heikkinen J, Rautiainen M. Effect of endoscopic sinus surgery on antral mucociliary clearance. *Rhinology* 2006;44:193–6.
28. Hafner B, Davris S, Riechelmann H, Mann WJ, Amedee RG. Endonasal Sinus Surgery Improves Mucociliary Transport in Severe Chronic Sinusitis. *Am J Rhinol* 1997;11:271–6. <https://doi.org/10.2500/105065897781446612>.
29. Mattos JL, Ferguson BJ, Lee S. Predictive factors in patients undergoing endoscopic sinus surgery for odontogenic sinusitis. *Int Forum Allergy Rhinol* 2016;6:697–700. <https://doi.org/10.1002/alr.21736>.
30. Peleg M, Chaushu G, Mazor Z, Ardekian L, Bakoon M. Radiological Findings of the Post- Sinus Lift Maxillary Sinus: A Computerized Tomography Follow-Up. *J Periodontol* 1999;70:1564–73. <https://doi.org/10.1902/jop.1999.70.12.1564>.
31. Galli SKD, Lebowitz RA, Giacchi RJ, Glickman R, Jacobs JB. Chronic Sinusitis Complicating Sinus Lift Surgery. *Am J Rhinol* 2001;15:181–6. <https://doi.org/10.2500/105065801779954120>.

A group of authors [132] have studied the local factors leading to sinus lift failure and have outlined what they term "otolaryngological contraindications to sinus lifting." They are divided into two categories:

1. Irreversible ENT (ear, nose, and throat) contraindications.
2. Reversible ENT contraindications

The significant importance of rhinological contraindications when preparing candidates for sinus lifting has been extensively emphasized in the literature [12]. According to Pignataro's study [11], sinusitis was diagnosed in 27% of patients who sought sinus lifting. In other words, every third candidate for sinus lifting has contraindications to the procedure.

In the currently available literature, there needs to be a unanimous opinion regarding the indications and relative or absolute contraindications for sinus lifting. In cases where there is pathology of the maxillary sinus or deviations in the ostiomeatal complex structures, there is no established protocol for managing the given pathology that, beyond treating the underlying condition, sets the best conditions for the subsequent elevation of the sinus floor. Likewise, the terms and nuances of performing sinus lifting following various methods of clearing the maxillary sinus must be adequately detailed in specialist literature.

2. MATERIAL AND RESEARCH METHODS

2.1. Study Design

The sample size is determined by applying the following formula:

$$n = \frac{1}{(1-f)} \times \frac{2(Z_{\alpha} + Z_{\beta})^2 \cdot P(1-P)}{(P_0 - P_1)^2}$$

Where:

Po = Failure rate in patients treated with the classical method is 49% (P0=0.49).

P1 = Failure rate in patients treated with the functional endoscopic method is 23% (P1=0.23).

P = (P0 + P1)/2 = 0.36

Zα – tabulated value. When the "α" – significance level is 5%, then Zα = 1.96

Zβ – tabulated value. When "β" – statistical power of the comparison is 80.0%, then Zβ = 0.84

f = The proportion of subjects expected to drop out of the study for various reasons q = 1/(1-f), f=10.0% (0.1).

This formula was chosen because the outcome parameters are binary categorical, and there are two patient groups.

By entering the data into the formula, we found:

$$n \approx \frac{1}{1 \approx 0.1} \times \frac{2 \times [1.96 \approx 0.84]^2 \times 0.36 \times 0.64}{[0.49 \approx 0.23]^2} \approx 59$$

Thus, for the research, two groups will be created: Research Group L1, which will include no fewer than 59 patients who will undergo the functional endoscopic treatment, and Control Group L0, which will include no fewer than 56 patients who will undergo the classical treatment.

Initially, 200 patients were included in the study. Using randomization methods, they were divided into two equal groups. 128 adult patients aged 18-71 attended follow-up visits and subsequent implant-prosthetic rehabilitation and constituted the final study sample. The remaining 72 patients did not consistently attend postoperative follow-ups for various reasons and were excluded from the study. Group I, comprising 65 patients, underwent surgical treatment using the principles of functional endoscopic surgery, and Group II, the control group of 63 individuals, underwent surgical treatment following the Caldwell-Luc method (Figure 2.1).

Inclusion Criteria:

- Age over 18 years.
- Signing of the informed consent form.
- Patients missing teeth in the upper lateral jaw section with the presence of pathology in the maxillary sinus require implant-prosthetic rehabilitation involving the maxillary sinus.

Exclusion Criteria:

- Patients were excluded from the study if they had:
- Allergic sinusitis.
- Nasal polyps.
- Invasive fungal sinusitis.
- Conditions of the lower respiratory tract, including chronic bronchitis and diffuse bronchiolitis.
- Nasal tumors.
- Immunodeficiencies (AIDS, drug-induced immunosuppression).
- Hemophilia.
- Decompensated endocrine diseases.
- Pregnancy.
- Treatment with bisphosphonates (in the last six months).
- Anatomical structural disorders of the nose and/or paranasal sinuses (post-traumatic, post-surgical, following radiotherapy).
- Chronic rhinosinusitis is irreversible due to congenital impairment of mucociliary clearance (Young's syndrome, Kartagener's syndrome).
- Aspirin intolerance (triad: nasal polyps, bronchial asthma, aspirin intolerance).
- Systemic granulomatous diseases (Wegener's granulomatosis, sarcoidosis).
- Insufficient preoperative or postoperative examination, as per the study protocol.
- Request to withdraw from the study.

2.2. Investigation Methods

For all patients, the degree of pneumatization of the affected sinus was noted both pre-operatively and post-operatively for 3-6 months, according to the modified scale by V.J. Lund and D.W. Kennedy [13]. This scale allows for the quantification of the degree of pneumatization and can provide crucial information about the structure of the sinus before and after surgical treatment (Fig. 2.1).

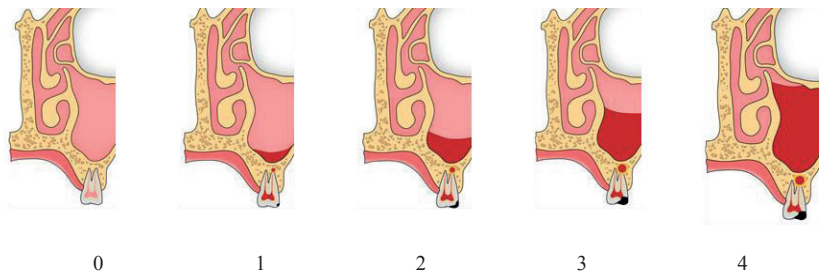


Figure 2.1. Schematic representation of the Lund-Kennedy scale. Original image

Note: 0 - Complete pneumatization, 1 - Mucosal thickening up to 5mm, 2 - Mucosal thickening up to 1/3 of the sinus volume, 3 - Mucosal thickening up to 2/3 of the sinus volume, 4 - Absence of sinus pneumatization.

Method for Assessing the Permeability of the Ostiomeatal Complex

BIBLIOGRAPHY

1. Anavi Y, Allon DM, Avishai G, Calderon S. Complications of maxillary sinus augmentations in a selective series of patients. *Oral Surgery, Oral Medicine, Oral Pathology, Oral Radiology, and Endodontology* 2008;106:34–8. <https://doi.org/10.1016/j.tripleo.2007.09.021>.
2. Topalo V, Fahim A, Dobrovolschii O. Rata succesului implantației dentare în elevația planșeului sinusului maxilar prin acces crestral. *Buletinul Academiei de Științe a Moldovei Științe Medicale* 2009;2:193–8.
3. Manji A, Faucher J, Resnik RR, Suzuki JB. Prevalence of Maxillary Sinus Pathology in Patients Considered for Sinus Augmentation Procedures for Dental Implants. *Implant Dent* 2013;22:428–35. <https://doi.org/10.1097/ID.0b013e31829d1a20>.
4. Pazera P, Bornstein M, Pazera A, Sendi P, Katsaros C. Incidental maxillary sinus findings in orthodontic patients: a radiographic analysis using cone-beam computed tomography (CBCT). *Orthod Craniofac Res* 2011;14:17–24. <https://doi.org/10.1111/j.1601-6343.2010.01502.x>.
5. Beaumont C, Zafiroopoulos G-G, Rohmann K, Tatakis DN. Prevalence of Maxillary Sinus Disease and Abnormalities in Patients Scheduled for Sinus Lift Procedures. *J Periodontol* 2005;76:461–7. <https://doi.org/10.1902/jop.2005.76.3.461>.
6. Brook I. Sinusitis of odontogenic origin. *Otolaryngology–Head and Neck Surgery* 2006;135:349–55. <https://doi.org/10.1016/j.otohns.2005.10.059>.
7. Troeltzsch M, Pache C, Troeltzsch M, Kaeppeler G, Ehrenfeld M, Otto S, et al. Etiology and clinical characteristics of symptomatic unilateral maxillary sinusitis: A review of 174 cases. *Journal of Cranio-Maxillofacial Surgery* 2015;43:1522–9. <https://doi.org/10.1016/j.jems.2015.07.021>.
8. Bucur A., Navarro V., Acero J. *Compendiu de chirurgie oro-maxilo-facială*. vol. 1. Med Publishing; 2009.
9. Onișor-Gligor F, T. Lung, M. Lazăr. Inflammatory affections of the maxillary sinus – statistical study on a 5-year period. *Revistă de Medicină Și Farmacie* 2009;LXXXI:606–8.
10. Lopatin AS, Sysolyatin SP, Sysolyatin PG, Melnikov MN. Chronic Maxillary Sinusitis of Dental Origin: Is External Surgical Approach Mandatory? *Laryngoscope* 2002;112:1056–9. <https://doi.org/10.1097/00005537-200206000-00022>.
11. Pignataro L, Mantovani M, Torretta S, Felisati G, Sambataro G. ENT assessment in the integrated management of candidate for (maxillary) sinus lift. *Acta Otorhinolaryngologica Italica* 2008;28:110–9.
12. Torretta S, Mantovani M, Testori T, Cappadona M, Pignataro L. Importance of ENT assessment in stratifying candidates for sinus floor elevation: a prospective clinical study. *Clin Oral Implants Res* 2013;24:57–62. <https://doi.org/10.1111/j.1600-0501.2011.02371.x>.
13. Lund VJ, Kennedy DW. Staging for Rhinosinusitis. *Otolaryngology–Head and Neck Surgery* 1997;117:S35–40. <https://doi.org/10.1016/S0194-59989770005-6>.
14. Lund VJ, Kennedy DW. Quantification for staging sinusitis. *The Staging and Therapy Group. Ann Otol Rhinol Laryngol Suppl* 1995;167:17–21.
15. Felisati G, Chiapasco M, Lozza P, Saibene AM, Pipolo C, Zaniboni M, et al. Sinonasal Complications Resulting from Dental Treatment: Outcome-Oriented Proposal of Classification and Surgical Protocol. *Am J Rhinol Allergy* 2013;27:e101–6. <https://doi.org/10.2500/ajra.2013.27.3936>.
16. Lee KC, Lee SJ. Clinical Features and Treatments of Odontogenic Sinusitis. *Yonsei Med J* 2010;51:932. <https://doi.org/10.3349/ymj.2010.51.6.932>.

PRACTICAL RECOMMENDATIONS:

In cases where radiological evaluation (based on CBCT) reveals sinus membrane (SM) thickening over 5 mm, and surgical management for sinus lifting (SL) is unclear, additional anterior rhinoscopy is recommended to assess the functional state of the SM and exclude acute pathology or pathological obstructions.

1. In the absence of clinical signs of acute infection on rhinoscopy, SL can be considered safe even in the presence of radiological signs of mucosal thickening.
2. If signs of sinusitis are present following a comprehensive examination (clinical, CBCT, and rhinoscopy), general and local medical treatment is recommended (with removal of the causal factor in odontogenic sinusitis), and sinus compliance should be dynamically analyzed with radiological and clinical reassessment after 3 months. For patients with high compliance, sinusitis signs will regress, and SL can be performed. For patients with low compliance, reevaluation is necessary to determine the need for surgical treatment of sinusitis.
3. In the presence of reversible pathologies of the SM, surgical treatment is recommended through an endooral or endoscopic approach, with reevaluation after 3 months for SL.
4. Considering that the efficacy of endooral treatment, according to study results, is similar to endoscopic treatment, the surgical technique should be selected based on the design of the access window for the subsequent SL procedure.
5. Due to technical features, endooral access is easier to perform and does not require general anesthesia. Access window planning should ensure it does not coincide with the future SL access window. If anatomical features do not allow for this access, a window can be created at the same level, but with the removal of a fragment from the lateral sinus wall and repositioning it at the end of the intervention (innovation No.). This access will prevent defect formation and mucoperiosteal ingrowth from the SM membrane.
6. For SM clearance interventions through endooral access, radical cure should be avoided, with maximal preservation of the SM mucosa.
7. In cases where SM pathology is associated with significant deviations of the Eustachian tube structures causing its obliteration or dysfunction, SM clearance surgery is recommended to be performed through endoscopic-assisted endonasal access with plasty of its elements.

To determine whether the ostium of the maxillary sinus was open or obstructed, we examined CT images. We looked for the presence or absence of a direct drainage pathway for mucus from the maxillary sinus to the middle nasal meatus (Fig. 2.2). In cases where there was a direct route without areas of radiopacity in the maxillary sinus in the middle nasal meatus. The ostium was deemed open (indicated by a green circle). Conversely, when the evacuation route was not visible on the CT, the ostium was blocked (indicated by a red circle).

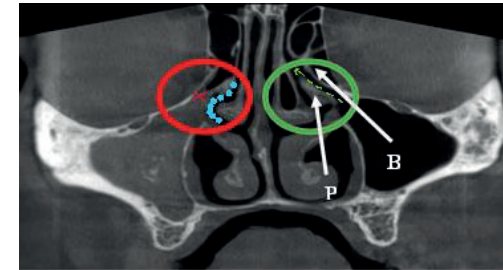


Figure 2.2. Assessment of OMU permeability based on CBCT. Coronal projection. Original collection

Note: Red circle - Blocked OMU, Green circle - Permeable COM, Green arrow - Drainage pathway of the maxillary sinus (SM), Red X - Absence of drainage pathway of the maxillary sinus (SM), Blue dots - Middle meatus, BE - Ethmoidal bulla, PU - Uncinate process.

2.3. Treatment Methods

Study Group I consisted of 65 patients who underwent surgical treatment using the principles of Functional Endoscopic Sinus Surgery (FESS). This endoscopic surgical approach was employed for procedures on the paranasal sinuses. It involves using a rigid optical endoscopic set to visualize and address sinus conditions. The procedure was carried out according to the appropriate standards and techniques of FESS, aiming at restoring the permeability of the ostiomeatal complex, removing obstructions, and unblocking the drainage of the maxillary sinus and other paranasal sinuses.

Control Group II consisted of 63 patients who underwent surgical treatment through an endooral approach by osteotomy of the lateral wall.

3. RESULTS

The patients admitted to the current research, according to the inclusion criteria, covered all age groups (Table 1). The youngest participants were 18 years old, while the maximum age was 71 years. The values were centred around an average age of 44 years with a standard deviation of 11 years. Half of the patients were between 35 and 52 years old, with the median age being 44 years.

Age	Minimum	18
	Maximum	71
	Medium	44
	Standard deviation	11
	25 th Percentile	35
	Median	44
	75 th Percentile	52

The research included participants of both genders. In both groups combined, there were 54 men, accounting for 42.2% of the overall sample. The remaining 57.8% were women.

The distribution by gender across the two groups is shown in Figure 3.1. As can be observed, the structure of the endoscopically treated group included 43.1% men and 56.9% women. The group of patients treated through endoral access consisted of 41.3% men and 58.7% women. Both study groups had a relatively similar gender distribution.

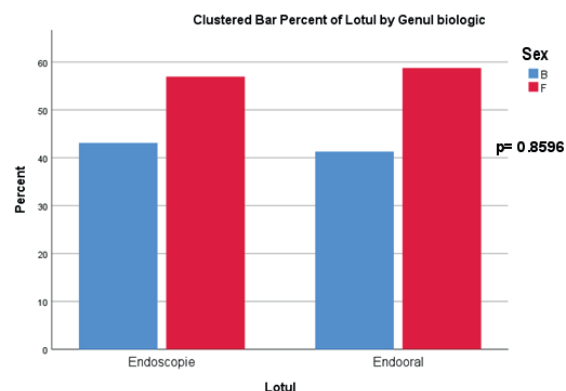


Figure 3.1. Comparative analysis of gender distribution in the study groups. Applied statistical test: Fisher's exact test

It's evident from the data that both treatment groups had a balanced gender distribution, with a slightly higher percentage of female participants in both. This balanced distribution is essential for ensuring the generalizability and validity of the study's findings across both genders.

The primary indicator of treatment success for sinusitis in our study was the modified Lund-Kennedy Score [14], which was compared between groups at both preoperative and postoperative stages. In the endoscopic group, patients recorded scores ranging from 0 to 4 on the Lund-Kennedy Scale (Figure 3.2), while those in the endooral group had scores ranging from 1 to 4 points.

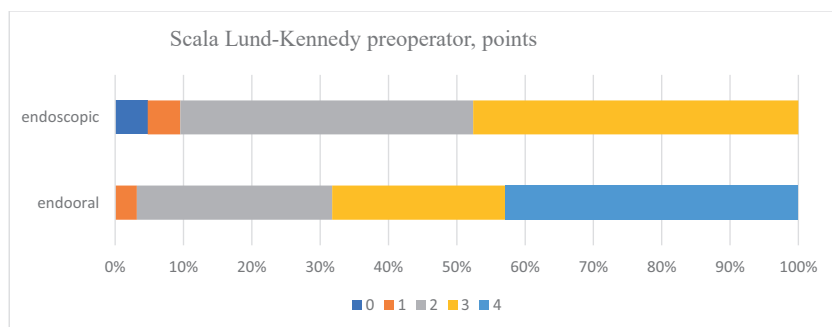


Figure 3.2. Comparative analysis of the preoperative Lund-Kennedy Score across the study groups at the preoperative stage

In the preoperative stage, participants treated with endoscopic techniques recorded a Lund-Kennedy Score of either 0 or 1, with unique cases for each score. Two points were

Doud Galli et al. reported that inefficient drainage of the maxillary sinus, combined with the penetration of augmentation biomaterial into the antrum, can cause sinusitis. They documented 14 cases of chronic sinusitis post-sinus lift procedure [31]. Timmenga et al. studied the effect of sinus lifting on the development of sinus pathology using endoscopy. Only 2 out of 45 patients (4.5%) developed sinusitis. Postoperative sinusitis occurred in 2 out of 5 patients with low compliance and none of the remaining 40 patients. The authors concluded that postoperative complications only occur in patients predisposed to sinusitis. These factors should be taken into account during surgical planning.

GENERAL CONCLUSIONS

1. Our unique approach, combining CBCT-based radiological examination of sinus compliance with diagnostic endoscopic rhinoscopy, has proven highly effective. It successfully diagnosed asymptomatic sinusitis in 35% of patients in the study group and 55.6% in the control group ($p=0.0327$). Additionally, this method excels in assessing the health and functionality of the paranasal sinuses, nasal cavities, and internal nasal structures. It is invaluable for pinpointing rhinological issues, diagnosing sinusitis, crafting an apt treatment plan, and mitigating the risk of complications during and after surgery.

2. The endoscopic and intraoral techniques showcased their effectiveness in our study. The endoscopic method had a 98.5% success rate, while the intraoral method boasted a 100% success rate. Either can be routinely employed in clinical scenarios. However, the endoscopic approach stands out as it is less invasive, speeds up the recovery process, and minimizes postoperative discomfort. Moreover, it offers a higher likelihood of preserving the maxillary sinus's lateral wall.

3. Our findings highlight the osteomeatal complex's pivotal role in surgical treatment planning. Restoring its permeability is crucial for the treatment's efficacy, especially when prepping for sinus lifts. Often, blockages in the osteomeatal complex in maxillary sinusitis cases are secondary, resulting from increased swelling in the sinus membrane. Both treatment strategies effectively restore the natural opening's permeability ($p < 0.001$), bolster the maxillary sinus's ventilation and expedite the healing trajectory.

4. While deviations in the internal nasal structures are crucial in treating sinusitis and mapping out implant-prosthetic rehabilitation, they are not the sole determinants. We did not find a strong correlation between these anatomical variances and sinus health issues ($p > 0.005$ for each anomaly). Therefore, correcting these deviations is essential only if they hinder endoscopic access or affect sinus ventilation and drainage. When planning a sinus lift, these anomalies can be overlooked as long as the sinus's aeration and drainage remain uncompromised and the mucosal thickness is within acceptable limits.

5. Our novel technique, combining maxillary sinus cleaning with a one-shot surgical sinus lift via an intraoral route, has shown remarkable efficiency, boasting a 100% success rate. This method is on par with the deferred sinus lift post-sinus cleaning ($p=0.0001$) and the combination of endoscopic sanitation with a simultaneous surgical sinus lift ($p=0.6769$). Its effectiveness suggests it could become a standard practice.

ensures the physiological and organ-preserving restoration of the COM and can be considered a significant advantage over endoscopic surgery (Figure 8b).

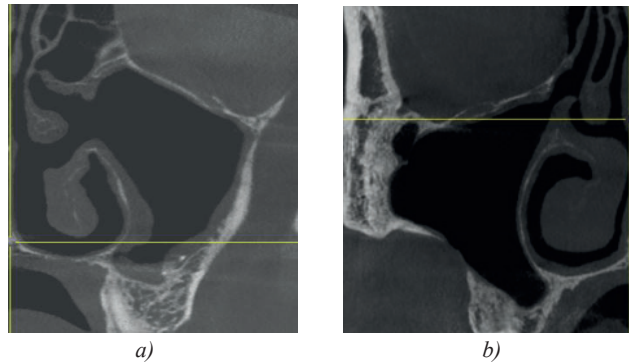


Figure 8. Postoperative appearance of the COM: a) after FESS, b) after intraoral access. Original image

Analyzing the gathered data, we evaluated the influence of the Osteomeatal Complex (COM) on the onset of sinusitis and mucociliary drainage. We also explored the possibility that the COM could be secondarily obstructed by inflamed mucosa.

FESS (Functional Endoscopic Sinus Surgery) is considered the gold standard in treating chronic sinusitis, as it facilitates the unblocking of COM permeability [24]. Recent studies have shown that over 35% of patients with chronic sinusitis do not have a blocked COM on tomography [25]. Two studies demonstrated a minor improvement in mucociliary clearance after FESS with expansion of the natural ostium [26,27]. Hafner et al. conducted the saccharin test on patients before and after FESS, revealing that transport time significantly improved in 17 out of 22 patients [28].

The absence of a noticeable visual difference was also confirmed when comparing pre-and postoperative values of the COM permeability. It was observed that, in the given group, for all operated patients, there was no statistically significant difference between the COM permeability before and after the procedure ($p = 0.869$). This emphasizes that while COM obstruction is an essential factor, it is not the primary cause in the pathogenesis of sinusitis. Some authors recommend using endoscopic methods to treat maxillary sinusitis precisely when the COM is obstructed [29]. Our study indicated that intraoral access can also be successfully applied in treating maxillary sinusitis in cases of a blocked COM. In most cases, COM obstruction is secondary due to the reversible edema of the sinus or nasal mucosa.

COM permeability is a crucial factor when planning a sinus lift (SL) procedure to ensure efficient drainage of the inflamed maxillary sinus (transitory sinusitis) after raising the sinus membrane. In pre-implant preparation, evaluating the natural ostium's permeability is decisive for establishing contraindications for SL. Peleg et al. (2010) conducted a CT scan 8-10 months post-sinus lift on 24 maxillary sinuses, with simultaneous implant installation, and concluded that patients with a blocked ostium are more prone to complications and should be informed of this [30].

recorded by 13.8% of the patients in this group. Slightly more patients, at 15.4%, scored 3 points. The maximum score, 4 points, was commonly observed among most individuals in the endoscopic group, with 67.7% receiving this score preoperatively.

The group of patients treated with open endooral access did not include any individuals with a preoperative Lund-Kennedy Score of 0 points (Figure 3.2). A score of 1 point was observed in 3.2% of patients. Participants scoring 2 or 3 points on the given scale during the preoperative phase were nearly the same in number, with 28.6% and 25.4%, respectively. In this group, the majority also had a predominant relative frequency, with 42.9% scoring the highest.

The distribution of observed values in the study participants changed almost symmetrically in the postoperative stage (Figure 3.3). In the endoscopic group, recorded scores ranged from 0 to 4 on the Lund-Kennedy scale, except for a score of 3, whereas in the opposite group, scores ranged between 0 and 2 points.

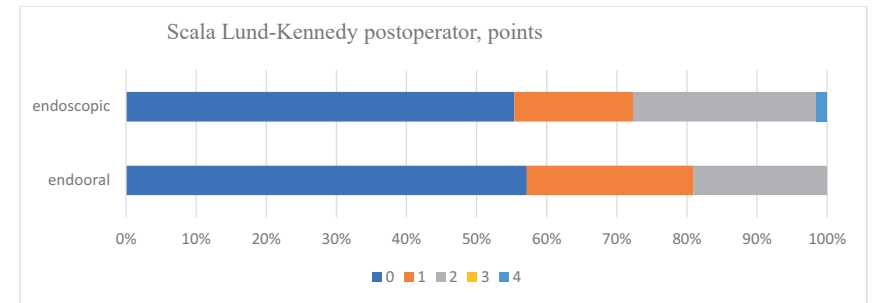


Figure 3.3. Comparative analysis of the postoperative Lund-Kennedy Score across the study groups.

The endoscopic group had most patients whose postoperative Lund-Kennedy Score was 0 points (55.4%) (Table 3.3). 16.9% of individuals in this group scored 1 point on this scale. 26.2% recorded a score of 2 points, and only one patient was noted with a score of 4. The group operated on using the endooral technique included 57.1% of patients who were postoperatively evaluated with 0 points on the Lund-Kennedy scale. Patients scoring 1 and 2 points were observed in 23.8% and 19.0% respectively. Scores of 3 or 4 points were not recorded in this group.

The subsequent feature observed in the study was the permeability of the osteomeatal complex (Figure 3.4). This represents another criterion by which the effectiveness of applying the two preimplantation preparation techniques can be assessed.

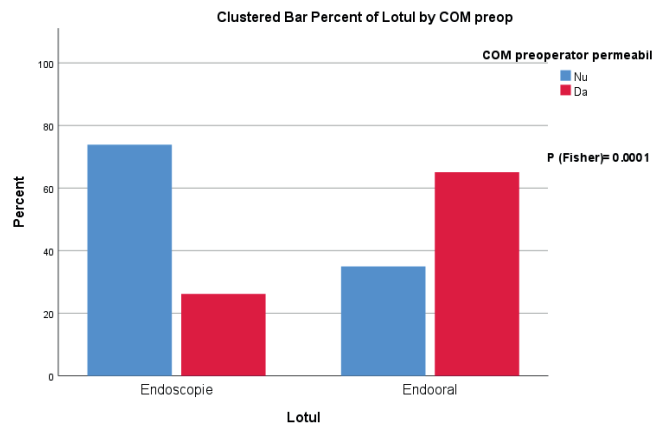


Figure 3.4. Comparative analysis of the preoperative permeability of the ostiomeatal complex in the study groups

It was observed that in the group of patients where the maxillary sinus was accessed endoscopically, 73.8% of the subjects had an impermeable ostiomeatal complex at the preoperative stage. In contrast, 26.2% of patients retained permeability. In the group operated on through intraoral antrostomy, as opposed to the previous group, there was an increased prevalence of individuals with a permeable ostiomeatal complex. Only 34.9% of cases in this group had an obstructed ostiomeatal complex.

The surgical procedure restored the permeability of the ostiomeatal complex in nearly all cases (Figure 3.5). In the group of patients operated on with endoscopic techniques, only one individual remained with an impermeable ostiomeatal complex. For the rest of the patients in this group, the permeability was restored.

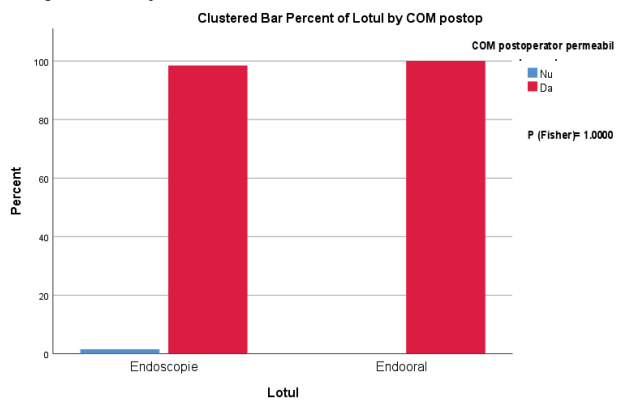


Figure 3.5. Comparative analysis of the postoperative permeability of the ostiomeatal complex in the study groups

In the group with intraoral antrostomy, all subjects had a permeable ostiomeatal complex at the postoperative stage.

4. DISCUSSIONS

In the preoperative period, the majority of patients in Group I had a score of 4 (67.7%), and similarly, Group II also had the majority of patients scoring 4 (42.9%) according to the Lund-Kennedy scale. These findings had high statistical significance ($p=0.0194$). The distribution of scores observed in the study subjects almost symmetrically shifted at the postoperative stage. This study demonstrates that the endoscopic functional approach, with the removal of the dental cause, is not only effective in treating sinusitis of rhinogenic origin but also odontogenic origin. Many authors have obtained similar results [69, 111]. At the same time, the endooral approach should not be underestimated. To date, many authors compare the endoscopic approach with the traditional Caldwell-Luc method, which involves removing the mucosa and performing an antrostomy in the inferior nasal meatus. Unsurprisingly, results favour the endoscopic approach, which is much more effective and organ-sparing [20]. Currently, the classic CL intervention is no longer performed; as the method continues to be refined, it has come to be used in a minimally invasive aspect. Presently, the Schneiderian mucosa is not entirely removed. Antrostomy in the inferior nasal meatus is not effective and has become a thing of the past [20]. By analyzing our results, we conclude that the minimally invasive endooral approach, without completely removing the sinus mucosa, also achieves good outcomes similar to the endoscopic method, sometimes being more manageable and more comfortable. Some authors confirm the equal effectiveness of the minimally invasive endobuccal access compared to the endoscopic one [23]. In one study, CL was compared with FESS, and it was found that patients with CL had a reoperation rate of 4.8-7.3%, while those with FESS had 18-27% [23]. In our study, we had a complication rate of 9.2% in the study group and 4.8% in the control group. The similar efficacy of the two methods indicates the possibility of choosing the appropriate treatment method based on the surgeon's experience.

Restoring the permeability of the osteomeatal complex (COM) is a crucial aspect in treating patients with sinusitis and holds significant importance in the medical context. This area plays a pivotal role in the proper drainage and ventilation of the sinuses, thereby maintaining an appropriate airy environment within this cavity.

It was noted that among the patient group who underwent maxillary sinus access via endoscopy, 73.8% had an impermeable osteomeatal complex during the preoperative stage. In comparison, Group II comprised only 34.9% of cases where the osteomeatal complex was obstructed. These findings are statistically highly significant ($p=0.0001$). Surgical procedures successfully restored the osteomeatal complex's permeability in almost all cases. In the group of patients treated with endoscopic techniques, only one individual still had an impermeable osteomeatal complex.

Restoring the natural ostium's permeability in these two surgical techniques operates through different mechanisms. The FESS (Functional Endoscopic Sinus Surgery) technique restores the COM's permeability by removing anatomical structures, which involves resecting the uncinate process, widening the natural ostium posteriorly, and occasionally opening the ethmoidal bulla, Haller's cells, and partial resection of the middle turbinate, creating a stable antrostomy in the middle meatus (Figure 8a). However, this antrostomy is not physiological; it is surgically created, sacrificing essential anatomical structures.

The natural ostium's permeability in the group with intraoral access is re-established as self-regulating without additional interventions at the COM level. This is due to the removal of the causal factor and the subsequent reduction of sinus mucosa edema. The intraoral approach