

<https://doi.org/10.52418/moldovan-med-j.66-2.23.02>  
UDC: 616.314.18-08



## Modern nickel-titanium rotary systems in endodontic treatment

\*Elena Buga, Eugen Buga, Diana Uncuta

*Pavel Godoroja* Department of Dental Propaedeutics  
*Nicolae Testemitanu* State University of Medicine and Pharmacy, Chisinau, the Republic of Moldova

Authors' ORCID iDs, academic degrees and contributions are available at the end of the article

\*Corresponding author – Elena Buga, e-mail: [drelenabuga@gmail.com](mailto:drelenabuga@gmail.com)

Manuscript received April 13, 2023; revised manuscript June 07, 2023; published online December 27, 2023

### Abstract

**Background:** One of the most important steps in endodontic treatment is the preparation of a uniform space, the use of endodontic irrigant and creating space for the endodontic filling. Therefore, improving endodontic treatment techniques is one of the most important tasks of modern dentistry. The success and effectiveness of endodontic treatment is largely determined by the quality of chemo-mechanical root canal treatment. In recent years there has been a major emphasis on the use of rotary mechanical instrumentation systems, namely the use of nickel-titanium (NiTi) alloys, which due to their properties represent a favorable flexibility in the instrumentation of difficult anatomies.

**Material and methods:** 20 patients were examined and treated. They were divided into 2 groups: for the treatment of 6 patients was applied the Protaper Universal rotary system. In the second group of 14 patients to whom mechanical instrumentation was applied, were 7 patients following the Protaper Next and the other 7 Dc Taper with different pulpal and periodontal diseases.

**Results:** Mechanical instrumentation was performed on different nosological entities, the prevalence being acute pulpitis. Among instrumented teeth, the prevalence was on the side of pluriradicular teeth.

**Conclusions:** The practical application of different NiTi rotary systems has to be determined individually, as each clinical case has its own practical properties. But the success of an endodontic treatment depends not only on the rotary instruments used and, on the method, chosen, but also on the practitioner's experience, detailed knowledge of the properties and step-by-step instrumentation protocols.

**Key words:** nickel-titanium alloy, rotary systems, endodontic instrumentation.

### Cite this article

Buga E, Buga E, Uncuta D. Modern nickel-titanium rotary systems in endodontic treatment. *Mold Med J.* 2023;66(2):12-19. <https://doi.org/10.52418/moldovan-med-j.66-2.23.02>.

### Introduction

The success of endodontic treatment is based on a clinician's skill in diagnosis, treatment planning, and advanced knowledge of root canal anatomy and morphology. This allows the most effective protocol to be chosen in daily practice and is supported by the pillars of endodontic treatment represented by instrumentation, irrigation and obturation [1, 2]. With the development of microtomography (MicroCT), the internal morphology of the tooth has acquired more complex and extensive nuances. Analyzing in detail the MicroCT performed by Marco Versiane, we truly understand the difficulties faced by a rotating needle on its way to the apical foramen [1, 3].

Undoubtedly, steel endodontic pins are important tools in endodontic practice, being useful in both primary treatment and endodontic retreatment. At the same time, steel endodontic needles have a high tendency to carry the original canal axis, creating thresholds, false pathways, perforations and other iatrogenics, due to the tendency to straighten once we advance in endodontic needle size. With the introduction of nickel-titanium (Ni-Ti) alloys, they have become indispensable in endodontic treatment. Because of this, more and more clinicians have switched to full or partial mechanical preparation of the endodontic

space with more flexible and cyclic fatigue resistant alloy needles.

In the early 1990s dental instrument manufacturers launched the revolutionary NiTi rotary endodontic needle system with increased flexibility and cutting properties, which significantly increased the clinicians' efficiency in endodontic treatment, making it faster and easier [4, 5].

An endodontic file, in the process of instrumentation, is continuously subjected to two stress forces: cyclic fatigue and torsional fatigue. Rotating endodontic needles made of NiTi, having a much higher flexibility than those made of steel, still have one property that needs considerable improvement, namely torsional strength. Moreover, as the size of the NiTi rotary needle advanced, the resistance to cyclic fatigue, equivalent to flexibility, also decreased considerably. For this reason, in subsequent studies, it has been shown that 10% of NiTi endodontic needles break on first use. Following this in the desire to improve the physical properties of endodontic file, a new type of wire was introduced for making the rotating file stem: M-wire, which heat-treated during production also gave it memory control, which led to an increase in the physical properties of the endodontic needle, and with them the speed, efficiency and control of endodontic preparation [6].

The combination of modern technologies in endodontic file manufacturing, using heat-treated alloys and appropriate cross-sectional design, provides a highly effective opportunity to negotiate the complex endodontic space for any practitioner.

As a result, the next 3 decades have seen an explosion in the development of NiTi endodontic rotary file systems. Improved properties in metallurgical technology have enabled the development of various new rotary instrument systems with innovative designs with a wide geometric range of blades and differently thermomechanically treated alloys [7, 8].

So individual design features differ from one endodontic needle system to another, as taper, helical angle, cross-sectional shape, tip (aggressive, non-aggressive), pitch of coils. Those endodontics that were among the first implemented on the dental market, many are already no longer used in the clinician's daily practice, giving way to innovative ones with a design much more enriched in properties [9].

According to Priyanka J. (2016) classification there are 5 generations of NiTi rotary systems [5, 9]:

1. **Generation I** – appeared in the mid to early 1990s, which is characterized by:

- They have passive non-marking guide facets, which stabilize the instrument and ensure its central position in the channel;
- They represent a constant taper along the length of the file;
- The angle of attachment is negative or neutral;
- During machining, a sequence of tools is determined which requires several rotating tools.

Examples: ProFile, GT Files, LightSpeed, Quantec, BioRace.

2. **Generation II (2001)** – is characterised by:

- Active cutting edges, no guide facets;
- Fewer rotary instruments are used during treatment;
- Some rotary instruments have been treated by electropolishing.

Examples: Flexmaster, BioRaCe, ProTaper U, Hero, Mtwo, BioRaCe.

3. **Generation III (2007)** – is characterised by:

- They are active rotary instruments;
- They are thermomechanically processed, such as M-wire or CM-wire;
- Decreased incidence of tool fracture due to reduced cyclic fatigue through improved elastic properties and durability.

Examples: HyFlex K3, Twisted file, GT Vortex, Twisted-Files.

4. **Generation IV (2010)** – is characterized by:

- In this generation the mode of action of the rotating system was changed from 360 rotary to a reciprocating motion;
- Single rotary tool technique.

Examples: Reciprocal rotation systems: Endo-Eze M4, Endo-Express.

Single-file systems: Self-adjusting, Wave One, Reciprocal.

5. **Generation V (2013)** – is characterised by:

- Centre of rotation is offset, balanced;
- Includes instruments with an irregular cross-sectional shape.

Examples: ProTaper Next (Dentsply) (2013), One shape, Revo-S (Micro-Mega), DC-Taper.

NiTi rotary files differ greatly in shape, size and mode of action. In order to be used effectively it is necessary to use them in certain sequencing [10]. Thus, many rotating systems are systematized and used in a certain sequencing developed by the production company according to a mathematical principle [11]. The exception is the mutual motion instruments, which according to the manufacturing companies use a single rotary file.

From the point of view of existing designs, it was decided to expose the design properties of various rotary systems and to analyze them in order to expose the diversity (tab. 1).

The aim of this paper is to study the properties of different varieties of rotary systems used in the mechanical preparation of the endodontic space in patients with different pulp diseases.







## Material and methods

The study was conducted in *Pavel Godoroja* Department of Dental Propaedeutics, *Nicolae Testemitanu* State University of Medicine and Pharmacy, where 20 patients were examined and treated, 9 men and 11 women, aged between 20 and 40 years. From the group of 20 patients treated, teeth with one root canal (incisors, canines and premolars) had 6 patients, 13 patients had 3 root canals (molars) and one had 4 root canals (upper molar).

Clinical history, inspection, palpation, percussion and paraclinical data were used to diagnose the nosological forms. In exobuccal clinical examination, great attention was paid to facial appearance and symmetry, in endo-oral examination the condition of the problem tooth was analyzed, on probing the response was followed, also percussion and thermal samples (cold sample) were performed. From the paraclinical examinations the radiological method was used by performing retroalveolar radiography and orthopantomography (OPG).

Endodontic treatment with mechanical root canal treatment was carried out with manual K-files to create glide paths and the ProTaper Universal, Protaper Next and DC Taper rotary systems. Medicated processing was performed with Sodium hypochloride solution 5.25%, 17% EDTA and distilled water solutions. Root canals were sealed with AH+ or Dexodent sealer and gutta-percha cones using the "central cone" method.

Table 1. Design features of rotaring systems [5, 10, 12]

Instrument system	Manufacturer/year	Introduced by	Cross-section/ Transvers section	Helical angle	Rake angle	Size	Taper	Speed (rpm)
<u>Profile</u>	<u>Dentsply Tusla Dental/1993</u>	Ben Johnson	<u>Triple U shape</u> 	Open 20	Negative ( 20)	15-90	2,4,5,6,7,8	150-350
<u>ProTaper</u>	<u>Dentsply TuslaDental/ 2001</u>	<u>P. Machtou,C. Ruddle, J West</u>	<u>Convex triangular</u> 	<u>Variable (grows from tip to shaft)</u>	Negative	17-30	<u>Variable SX-3.3-19, S1-2-11 S2-4-11.5 F1-7-5.5 F2-8-5.5 F3-9-5.5</u>	250-350
<u>M two</u>	<u>VDW, Munich Germany/2003</u>	-	<u>Italic S</u> 	<u>Variable (grows from tip to shaft)</u>	Negative	10-40	4,5,6,7	300-350
<u>Hyflex</u>	<u>Coltene Endo/2011</u>	<u>Ricardo Caicedo Stephen Clark</u>	<u>Double fluted Hedstrom design</u> 	<u>Variable (acelerated flute deesign)</u>	<u>Positive</u>	15-40	4,6,8	500
<u>Wave-One</u>	<u>Dentsply Tusla Dental/2011</u>	-	<u>Parabolic (anneabled heat treated)</u> 	<u>Variable (grows from tip to shaft)</u>	Negative	21-40	6,8	300
<u>Reciproc</u>	<u>VDW GmbH, Munich, Germany/2011</u>	-	<u>Double-S-shaped</u> 	<u>Variable (grows from tip to shaft)</u>	Negative	25-50	5,6,8	300
<u>ProTaper Next</u>	<u>Dentsply Tusla Dental/2013</u>	<u>Ricardo Machado</u>	<u>Rectangular (offset design)</u>	-	-	17-40	4,6	300

Results and discussion

After treatment according to the proposed protocols, depending on the rotating instrumentation system used, in each of the 20 cases examined, the clinical signs present at the time of referral, characteristic of each nosological form diagnosed, disappeared. For the forms with periapical disease, it was recommended to perform radiological examination at 6 and 12 months to highlight and note the disappearance of pathological signs.

Of the 20 patients treated, 5 patients had a single root canal (incisors, canines and premolars), 14 patients had 3 root canals (molars) and one had 4 root canals (upper molar).

From the diagnosed noxious forms from the total group of patients, namely acute diffuse pulpitis, chronic

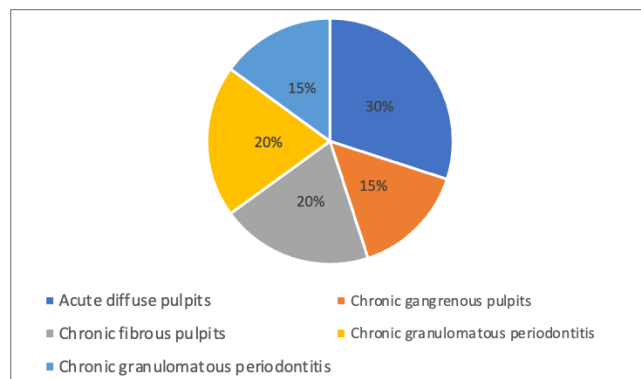


Fig. 1. Ratio of nosological forms of pulpal inflammation and periapical lesions

Table 2. Distribution of nosological forms of pulpal inflammation and periapical lesions

Pulpitis				Apical periodontitis		
Total	Acute diffuse pulpitis	Chronic gangrenous pulpitis	Chronic fibrous pulpitis	Total	Chronic granulating periodontitis	Cronic granulomatous periodontitis
13	6	3	4	7	4	3

gangrenous pulpitis, chronic fibrous pulpitis, chronic fibrous periodontitis, chronic granulomatous periodontitis the prevalence was on the side of acute diffuse pulpitis being 6 (30%) patients from the total group as shown in tab. 2 and fig. 1.

Following the group distribution, was analyzed the frequency of instrumentation of one root canal and multiple root canals with rotary systems as well as the frequency of instrumentation with second and latest generation rotary systems (fig.2). The results are shown below by graphical representation in fig. 3, 4, 5, where it was deduced that the frequency of instrumentation was on the side of multiple root canals, with equal use of rotary systems by each manufacturer included in the data analysis.

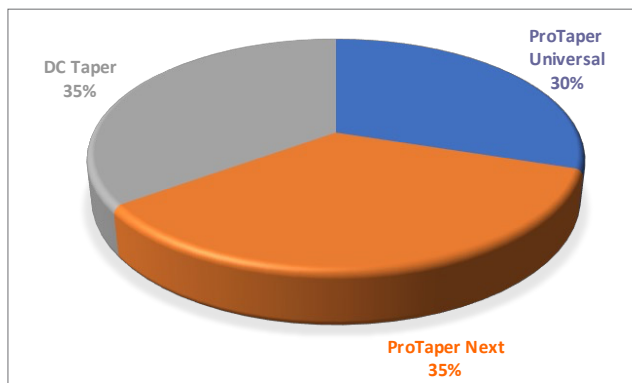


Fig. 2. Frequency of rotary instrumentation used in mechanical root canal preparation

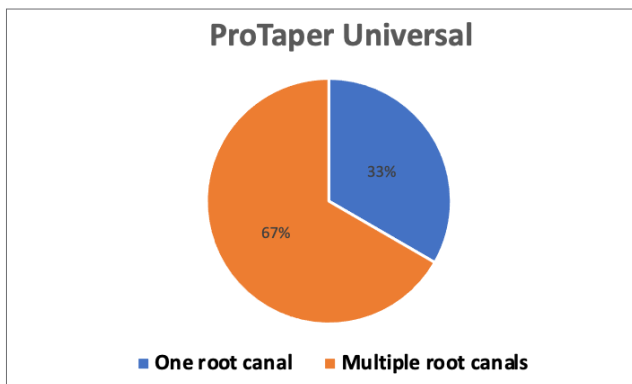


Fig. 3. Frequency of instrumentation with ProTaper Universal depending on the root canal system

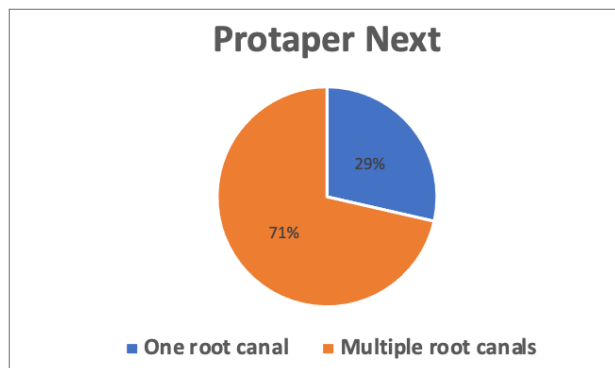


Fig. 4. Frequency of instrumentation with ProTaper Next depending on the root canal system

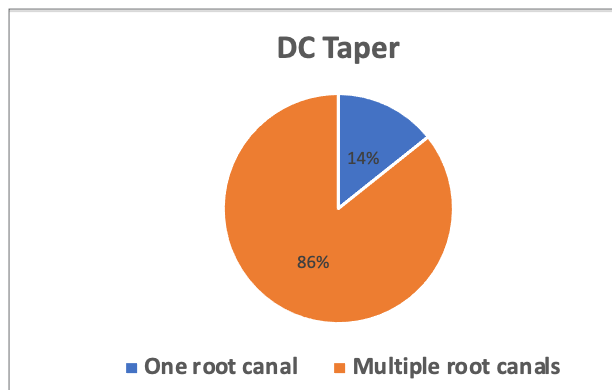


Fig. 5. Frequency of DC Taper instrumentation depending on root canal system

**Clinical case**

Family Name, First name: Patient X  
 Date of birth: 12.08.1983  
 Gender: Female  
 Residence: Chisinau

**The complaints:** the patient presents with an intense pain in the lower jaw on the right side, throbbing, long-lasting with periods of remission, but which are short-lived. The pain may occur spontaneously having a progressive character, but in turn is exacerbated by the action of thermal excitants. The pain is more pronounced at night, when the patient cannot sleep. The pain has a radiating character and radiates towards the temporal region. Pain-killers and analgesics practically do not subside.

**Endo-oral examination**

The mucosa of buccal cavity vestibule, hard palate, pinkish-pale buccal plane without pathological changes. There was an older filling in tooth 37. On probing tooth 37 there was pain on the entire surface of the filling. On percussion, insignificant pain was present. On thermal sampling (cold with ColdSpray) the tooth in question was identified, where the pain persisted even after removal of the excitant. EOD was performed with the Pulpotest device or values of 50 µA were obtained.

**Diagnosis:** Following subjective clinical examination (violent pain, persisting for a long time, with short periods of remission, which worsens on the action of thermal excitants and is maintained when they are removed) and objective data (pain probing, positive thermal sample, EOD 50 µA.), the diagnosis was: acute diffuse pulpitis in tooth 37.

**Treatment:** the treatment method involved vital extirpation of the pulp of the tooth 37. The treatment was carried out in a single session. Infiltrative anaesthesia with Septanest 4% 1/100000-1.7 ml was performed. The tooth was isolated with cofferdam (fig. 6), the access was created by removing the filling and opening the pulp chamber (fig. 7). Three root canals were detected in tooth 37: distal and 2 mesial (fig. 8). The instrumentation of the root canals for the creation of the initial glide path was carried out with the help of K-files of 08/02, 10/02 15/02 (fig. 7).

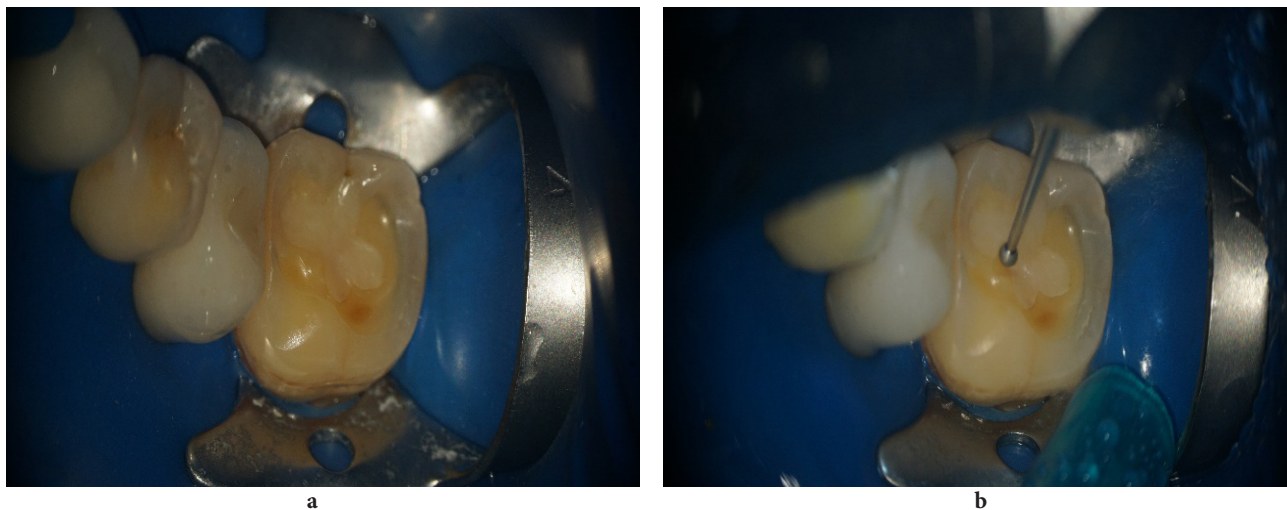


Fig. 6. a) Ruber Dam image application; b) access creation

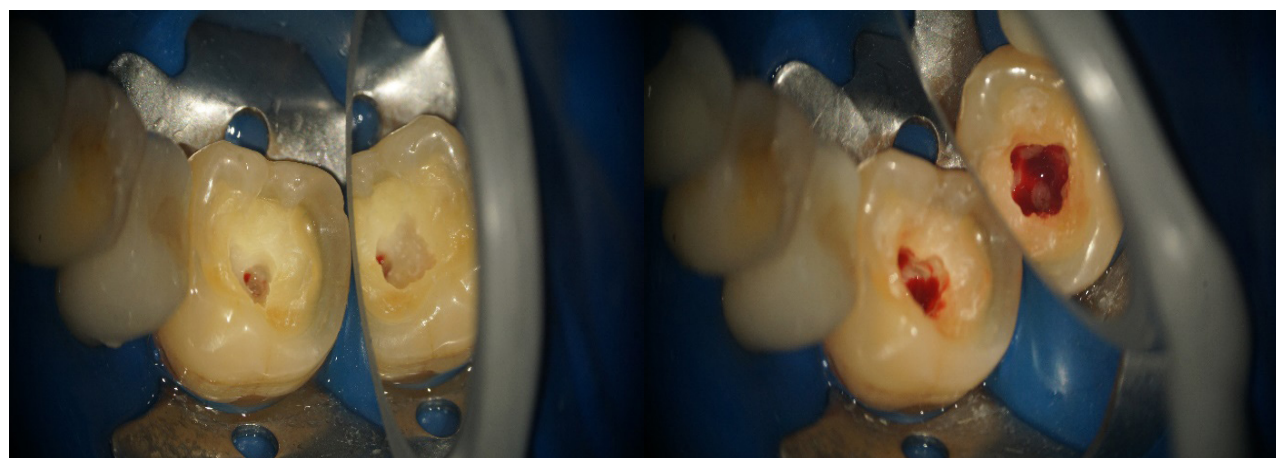


Fig. 7. Opening the pulp chamber

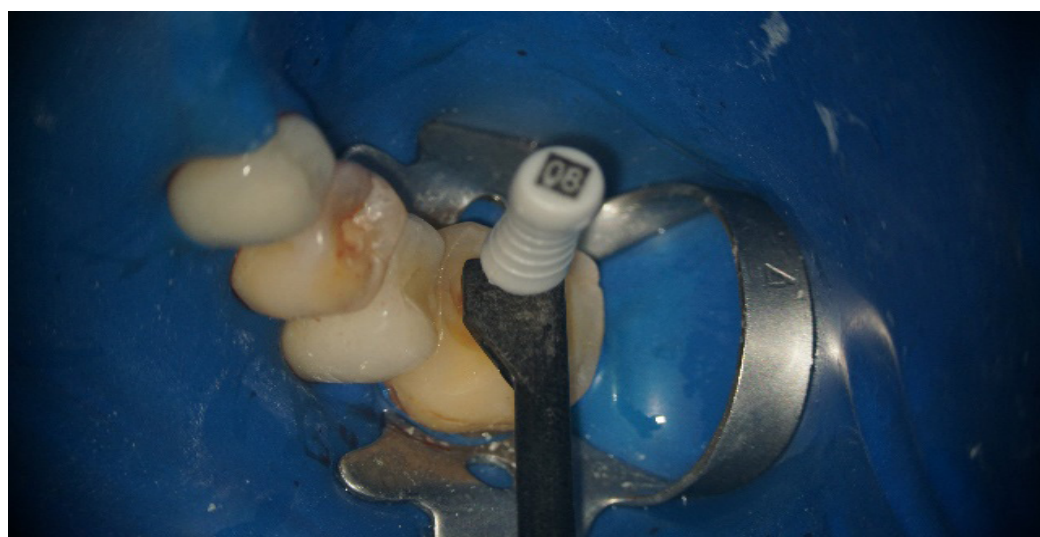

Fig. 8. Determination of working length using the Woodpex V

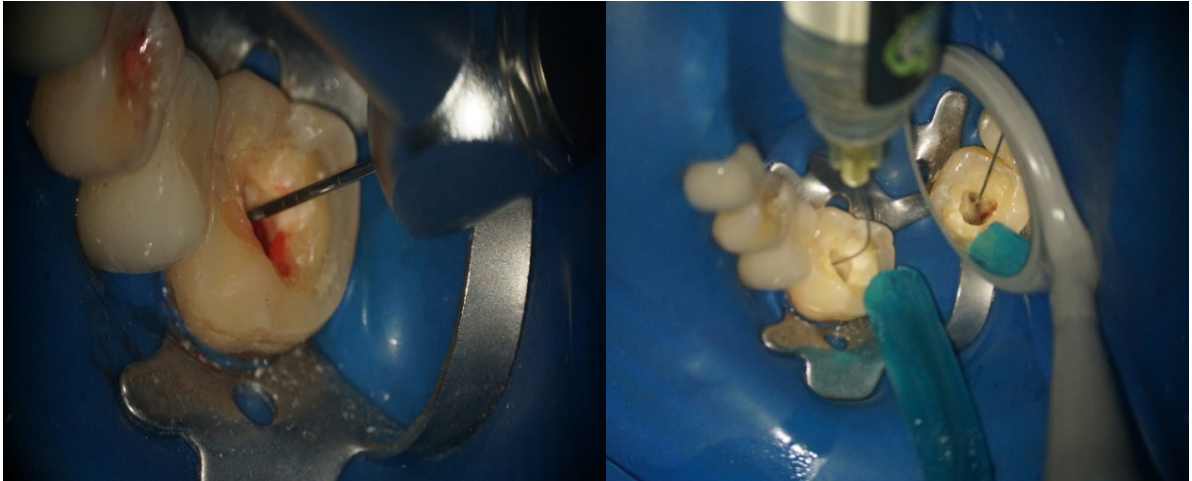

Fig. 9. Mechanical instrumentation with rotary needle 17/04 and irrigation with CHLORAXID 5.25%

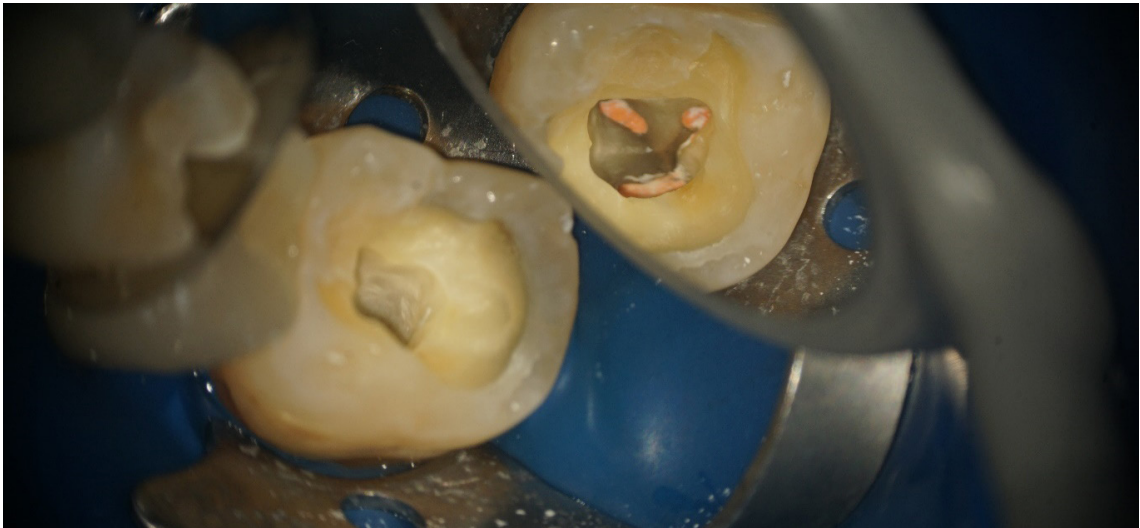

Fig. 10. Root canals obturated by the central cone technique

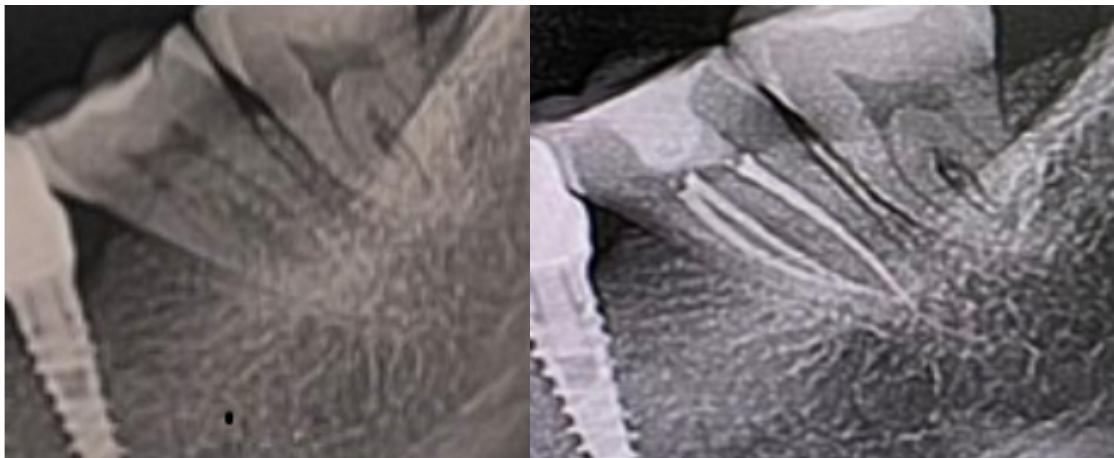


Fig. 11. Preoperative and postoperative retroalveolar radiograph of tooth 37

Then the DC Taper rotary system was used. The technique used was standardized until the apical size of 25/04 was reached according to the manufacturer's protocol (fig. 9). The working length of the root canals was determined by the electronic apex-locator method. Sodium hypochloride solution 5.25% in combination with 17% EDTA gel and distilled water was used for canalicular irrigation (fig. 9). The canals were dried using sterile paper cones, after which they were sealed by the "central cone" method, using size 20 gutta-percha cones with conicity 06 as filler and Dexodent as sealer (fig. 10). The coronal restoration was carried out by the direct method with light-curing composite material "Clearfil-AP-X Esthetics".

According to publications and studies, the advent of nickel-titanium (NiTi) alloys in the late 1980s led to a revolution in endodontics, as these files have been shown to have considerable advantages over stainless steel (SS), particularly in terms of instrument safety [13]. NiTi files were able to overcome the problem of stiffness and low resistance to cyclic fatigue associated with stainless steel instruments. Apart from the advantage of increased flexibility and shorter treatment time, NiTi threads also resulted in fewer procedural errors, such as zippering, corrugations or transport, due to their superelasticity, compared to SS threads [13, 14].

Reference to the study carried out and other comparative studies made in the literature by professionals in mechanical instrumentation with different rotary systems suggested that endodontic instruments made with M-Wire have faster flexibility and mechanical instrumentation staging and higher wear resistance than similar instruments made with conventional NiTi wire, due to its unique nanocrystalline martensitic microstructure [6].

### Conclusions

1. According to contemporary literature the emergence and evolution of modern rotary endodontic instruments is intensively studied and analyzed in the literature. Rotating endodontic instruments have a variety of design, taper characteristics that contribute to their excellent clinical performance in modern endodontics. It is concluded that many studies conducted in the analysis of various NiTi rotary systems have shown that the innovation of rotary systems with properties, considerably increase the cyclic and torsional fatigue strength of modern rotary systems.

2. According to the modern endodontic treatment concept, rotary systems are classified according to generation. Both early and late generation rotary endodontic instruments are effective in removing debris from the walls of

root canal systems and achieving a conical, continuous canal shape. First generation rotary instruments have certain disadvantages compared to the newer generation instruments as they use more rotary instruments in the instrumentation protocol which increases working time, fatigue. Plus, the enrichment of the new generations with properties compared to the first generations increase effectiveness due to increased flexibility and resistance to cyclic and torsional fatigue.

3. The practical application of different NiTi rotating systems has to be determined individually, as each clinical case has its own practical properties. But the success of an endodontic treatment depends not only on the rotary instruments used and the method chosen, but also on the practitioner's experience, detailed knowledge of the properties and step-by-step instrumentation protocols.

### References

- Casteluci A, editor. Endodontics. Vol. 1. Florence: IL Tridente; 2004. 354 p.
- Danici A, Roman I, Ciobanu S, Cucu D. Comparative study of endodontic instruments shaping properties. *Medicina Stomatologică (Chisinau)*. 2017;(1-2):61-65.
- Versiani MA, Basrani B, Sousa-Neto MD, editors. The root canal anatomy in permanent dentition. Cham: Springer; 2019. 420 p.
- McSpadden JT. Mastering endodontic instrumentation. Ramsey, NJ: Cloudland Institute; 2006. p. 43.
- Pishchinskii IA, Delendik AI. Endodonticheskoe lechenie s primeneniem nikel'-titanovykh instrumentov [Endodontic treatment using nickel-titanium instruments]. Minsk: BGMU; 2009. 40 p. Russian.
- Ye J, Gao Y. Metallurgical characterization of M-Wire Nickel-Titanium shape memory alloy used for endodontic rotary instruments during low-cycle fatigue. *J Endod*. 2012;38(1):105-107. doi: 10.1016/j.joen.2011.09.028.
- Gavini G, Santos MD, Caldeira CL, et al. Nickel-titanium instruments in endodontics: a concise review of the state of the art. *Braz Oral Res*. 2018;32(Suppl 1):e67. doi: 10.1590/1807-3107 bor-2018.vol32.0067.
- Zupanc J, Vahdat-Pajouh N, Schäfer E. New thermomechanically treated NiTi alloys – a review. *Int Endod J*. 2018;51(10):1088-1103. doi:10.1111/iej.12924.
- Priyanka J, editor. Current therapy in endodontics. Ames: Wiley BlackWell; 2016. 648 p.
- Pedulia E, Grande NM, Plotino G, Gambarini G, Rapisarda E. Influence of continuous or reciprocating motion on cyclic fatigue resistance of 4 different nickel-titanium rotary instruments. *J Endod*. 2013;39(2):258-261. doi: 10.1016/j.joen.2012.10.025.
- Parashos P, Gordon I, Messer HH. Factors influencing defects of rotary nickel-titanium endodontic instruments after clinical use. *J Endod*. 2004;30(10):722-725. doi: 10.1097/01.don.0000129963.42882.c9.
- Soni MR, Swaroop H, Mathew S, Madhu KS. Rotary systems: an insight. *J Dent Orofac Res*. 2014;10(2):16-21.
- Walia HM, Brantley WA, Gerstein H. An initial investigation of the bending and torsional properties of Nitinol root canal files. *J Endod*. 1988;14(7):346-51. doi 10.1016/s0099-2399(88)80196-1.
- Liu SB, Fan B, Cheung GS, Peng B, Fan MW, Gutmann JL, et al. Cleaning effectiveness and shaping ability of rotary ProTaper compared with rotary GT and manual K-Flexofile. *Am J Dent*. 2006;9(6):353-8.

**Authors' ORCID iDs and academic degrees**

Elena Buga, MD, Undergraduate Student – <https://orcid.org/0009-0002-7359-8245>

Eugen Buga, MD – <https://orcid.org/0009-0003-9669-5205>

Diana Uncuta, MD, PhD, Professor – <https://orcid.org/0000-0001-8172-2854>

**Authors' contributions**

EB and EB collected the data, wrote the first version of the manuscript; DU conceptualized the idea, completed the final text, and revised critically the manuscript. All the authors approved the final version of the manuscript.

**Funding**

This study was supported by *Nicolae Testemitanu* State University of Medicine and Pharmacy of the Republic of Moldova. The study was the authors' initiative. The authors are independent and take responsibility for the integrity of the data and accuracy of the data analysis.

**Ethics approval and consent to participate**

The study was approved by the Research Ethics Committee of *Nicolae Testemitanu* State University of Medicine and Pharmacy, protocol No 2 of 12.09.2022.

**Conflict of interests**

The authors have no conflict of interests to declare.

