

**Doctoral School in Medical Sciences**

Cu titlu de manuscris

*U.D.C: 616.314-089.843:616.716.1-007.23(043.2)*

**ION DABIJA**

**IMPLANT-PROSTHETIC REHABILITATION OF PATIENTS  
WITH SEVERE ATROPHIES IN THE LATERAL AREAS OF  
THE SUPERIOR JAW**

**DISCIPLINE 323.01 - STOMATOLOGY**

**Summary of the Doctoral Thesis in Medical Sciences**

The thesis was prepared within the Department of Oral and Maxillofacial Surgery and Oral Implantology "Arsenie Guțan" at the State University of Medicine and Pharmacy "Nicolae Testemițanu"

**Supervisor**

Nicolae Chele,

Dr. Hab. Med. Sci., Prof..

\_\_\_\_\_

**the Thesis Advisory Committee Members:**

Valentin Topalo,

Dr. Hab. Med. Sci., Assoc. Prof

\_\_\_\_\_

Andrei Mostovei,

Dr. Med. Sci., Assoc. Prof.

\_\_\_\_\_

Oleg Zănoagă,

Dr. Med. Sci., Assoc. Prof.

\_\_\_\_\_

The defense will take place at 02.10.2024 at the premises of USMF "Nicolae Testemițanu", 165 Stefan cel Mare și Sfânt Blvd., office 205 in the meeting of the Public Thesis Defense Committee, approved by the decision of the Scientific Council of the Consortium from 26.06.2024 (minutes no. 24).

**the Public Thesis Defense Committee:**

***Chairman:***

Sergiu Ciobanu,

Dr. Hab. Med. Sci., Assoc. Prof.

\_\_\_\_\_

***Members:***

Nicolae Chele,

Dr. Hab. Med. Sci., Prof.

\_\_\_\_\_

Aurelia Spinei,

Dr. Hab. Med. Sci., Assoc. Prof..

\_\_\_\_\_

Oleg Solomon,

Dr. Med. Sci., Assoc. Prof.

\_\_\_\_\_

***Official Reviewers:***

Aureliana Caraiane,

Dr. Med. Sci., Prof.

\_\_\_\_\_

Doriana Agop-Forna,

Dr. Med. Sci., Prof.

\_\_\_\_\_

Oleg Zănoagă,

Dr. Med. Sci., Assoc. Prof.

\_\_\_\_\_

Author

Ion Dabija,

\_\_\_\_\_

## Contents

INTRODUCTION .....	4
The relevance and importance of the addressed issue. ....	4
2. MATERIAL AND RESEARCH METHODS.....	6
2.1 General Characteristics of the Research.....	6
2.2 Examination and Investigation Methods.....	7
2.3. Surgical Protocol Applied to Patients in the Control Group .....	9
2.4. Surgical Protocol Applied to Patients in the Study Group .....	11
2.5. Patient Evaluation During the Healing Period .....	13
2.6. Statistical Processing Methods for Results .....	14
3. OBTAINED RESULTS .....	14
3.1. General Results of the Study Groups .....	14
3.2. Evaluation of Post-Extraction Periods in the Researched Groups .....	15
3.3. Evaluation of Sinus Shape, Volume, and Grafting Materials in Patients Included in the Study.....	16
3.4. Evaluation of the Influence of Access Windows on Research Outcomes.....	18
3.5. Evaluation of Residual Subantral Bone and Evolution of the Augmented Space During the Healing Period.....	19
3.6. Evaluation of Implant Stability .....	22
3.7. Evaluation of Accidents and Complications Encountered in the Research Groups.....	25
4. SYNTHESIS AND INTERPRETATION OF OBTAINED RESULTS .....	26
4.1. Correlational Analysis of the Studied Lot .....	26
4.2. Analysis of the Results of Implant-Prosthetic Rehabilitation .....	27
5. GENERAL CONCLUSIONS .....	30
PRACTICAL RECOMMENDATIONS .....	30
INFORMATION REGARDING THE VALORIZATION OF RESEARCH RESULTS.....	35

## INTRODUCTION

**The relevance and importance of the addressed issue.** Recently, the indications for the use of dental implants have been expanded, and the proportion of implant-supported prostheses in the prosthetic rehabilitation of patients has increased considerably. Although dental services, including dental implantology, have evolved rapidly in recent decades, remarkable successes have been achieved in the application of innovative surgical techniques and procedures [35] for the rehabilitation of patients with various edentulous conditions, including those with disabilities [53], there are still many controversial and debatable aspects that require further research. Disputes concern the application of minimally invasive procedures in oral implantology [8, 16, 28, 36] and the methods and conditions for installing dental implants in patients with severe atrophies in the lateral areas of the superior jaw [108]. Thus, certain anatomic-physiological conditions may eventually influence the performance of surgical interventions and, therefore, compromise the tissue integration of dental implants.

It is well known that after tooth extraction, a series of immediate post-extraction modifications occur, such as filling the alveolus with a blood clot, which is replaced by granulomatous tissue after one week [39]. The bone trabeculae of the newly formed tissue are subjected to mineralization processes so that dental implants can be inserted towards the end of the second month after extraction [10]. Much more severe are the morphological changes that occur at late post-extraction terms, resulting in the reduction of the buccal palatal volume of bone, bone resorption, and maxillary sinus pneumatization [1]. The tooth loss in the superior arch leads to the activation of osteoclasts of the Schneiderian membrane, which triggers the resorption of the alveolar process of the maxilla with a descent of the sinus floor [52]. Post-extraction bone ridge resorption is more pronounced at the level of molars and more intensive during the first six months. The resorption process continues throughout the patient's life, with changes in the height of the alveolar ridge and the width of the palatal slope of the alveolar process of the maxilla [8, 37, 39].

The tooth loss induces a chain of modifications in the alveolar ridges, triggered by biological factors in the form of inflammatory processes, periodontal disease, chronic marginal periodontopathic, residual alveolar cavities, metabolic disorders, dental anomalies, leading to peri-implant bone tissue resorption [20], and in the maxilla, excessive pneumatization of the maxillary sinus occurs due to subantral bone resorption [12, 29, 40, 44]. Depending on the state of the alveolar bone, an algorithm for individualized treatment is developed, respecting national and international protocols. For example, Atamni F. (2013) [1], in a study, concluded that implants could be inserted into the pre-existing bone tissue of the maxilla, avoiding the sinus augmentation procedure, which, according to the author, is more beneficial and faster for the patient and cost-effective. Unfortunately, in cases of poor residual maxillary bone conditions, without the maxillary sinus augmentation procedure, the insertion of dental implants is not possible, the stability and viability of which may be compromised due to the variability and anomalies of the maxillary sinus, the presence of intrasinus septa, Haller cells, intraorbital recesses [17, 31, 45, 46, 52]. With the advent of the maxillary sinus augmentation procedure, research in the field of oral implantology has been activated, both internationally [2, 6, 19] and nationally [7, 8, 9, 10, 11, 12, 14, 15, 21, 28, 30, 48, 49], leading to the identification of a series of new methods and procedures for the implant-prosthetic treatment of edentulous individuals.

Elevating the maxillary sinus floor can be performed using autogenous, allogeneic, xenogeneic, and alloplastic grafts, with autogenous grafts being the most effective [38], sourced from intraoral or extraoral origins. Intraoral grafts commonly include those harvested from the maxillary tuberosity, ramus and body of the mandible, mental symphysis, and zygomatic arches. Extraoral grafts are predominantly taken from the bone tissue of the ilium, ribs, tibia, and calvaria. A wide range of biomaterials such as beta-tricalcium phosphate,

hydroxyapatite, calcium carbonate, calcium sulfate, and bioactive glass are successfully used for maxillary sinus augmentation [13, 40, 41].

Accessing the maxillary sinus and performing its augmentation can be achieved through lateral and crestal approaches [5, 26, 27], although most researchers opt for the transcristal approach [5, 26, 27, 42, 47]. Maxillary sinus augmentation has proven to be an effective method for obtaining pre-implant intrasinus bone of acceptable quality for implant insertion and dental restoration, a effectiveness demonstrated by domestic researchers [10, 14, 15, 30], predominantly utilizing the transcristal approach to the sinus floor, a minimally invasive and efficient method for edentulous individuals with severe atrophies of the posterior maxillary sectors [51]. Additionally, in patients with bone resorptions and severe atrophies in the posterior sectors of the superior jaw, the classical lateral access method is used for prosthetic rehabilitation and maxillary sinus augmentation. Sinus floor augmentation conditions the formation of new bone tissue in approximately 6 months [2].

Upon analysis of available sources in the specialized literature, a lack of detailed data on choosing optimal conditions for installing dental implants in patients with severe atrophies in the lateral areas of the superior jaw was noted. Therefore, particular interest is focused on the posterior region of the maxilla, where the maxillary sinus is located. In this region, bone tissue is subjected, on one hand, to resorption due to the reduced anatomical density of the maxillary bone, and, on the other hand, to sinus pneumatization [32]. Consequently, patients with severe atrophies in this region encounter difficulties during the stage of bone offer creation and subsequent implant installation. Although there are multiple studies dedicated to augmentation materials [23, 43], the implant-prosthetic rehabilitation of edentulous patients remains current to date. This is explained by the frequent difficulties encountered in remedying severe maxillary atrophies, leading to an increased implant-prosthetic treatment time, with negative consequences on the patient's psycho-emotional state.

Therefore, refining implant-prosthetic rehabilitation methods for individuals with severe atrophies in the lateral quadrants of the maxilla is an indispensable, current, and effective method, both aesthetically and in terms of application [3, 18].

**Purpose of the Paper:** This research holds significant importance as it presents a comparative evaluation of implant-prosthetic rehabilitation methods, aiming to optimize treatment for patients with severe atrophy in the lateral areas of the superior jaw.

#### **Objectives of the Paper**

1. To study the characteristics of bone atrophy and maxillary sinus pneumatization following the extraction of the lateral teeth of the superior jaw.
2. To assess the characteristics of dental implant placement in the posterior sectors of the maxilla depending on the subantral residual bone.
3. To analyze the maxillary sinus floor elevation techniques through lateral access with simultaneous implant placement in cases of severe atrophy and their stabilization during the integration period.
4. To provide a comparative study of the quality, quantity, and dynamics of crestal and intrasinus bone – the thickness, volume, and density of the bone formed depending on the augmentation material used.

**Research Hypothesis** The use of special stabilization devices for implants during osteointegration in SA-4 bone allows achieving a success rate similar to that in SA-2 and SA-3.

**General Methodology and Research Design.** Our study was conducted on a group of 104 patients with various degrees of edentulism and severe atrophy in the lateral quadrants of the maxilla. At the initial stage, it was decided that the patients would be divided into two groups: a control group and a study group, and inclusion and exclusion criteria were established for each patient in either category.

All patients underwent both extra- and intra-oral clinical examinations, and a medical history was collected to rule out any contraindications. The oral cavity clinical examination was conducted thoroughly, assessing each categorical variable of interest to our study. The paraclinical examination included radiological assessment based on orthopantomograms (OPG) and, when necessary, some laboratory tests. In planning the implant-prosthetic rehabilitation, all patients were examined using cone beam computed tomography (CBCT).

**Theoretical Significance and Practical Value of the Work:** The results of the study are important at a theoretical level for the education of scholarly youth, and clinically, they are significant for implant-prosthetic practice.

**Scientific Results Approval:** The results of the study have been reported at various national and international scientific forums as follows: The 23rd Bass Congress Dental Medicine for Younger vs Elderly Patients, May 10-12, 2018, Iași, Romania; International Scientific Conference in memory of the distinguished scientist, university professor Valentin Topalo, Chișinău, Moldova, April 28, 2023; Conference dedicated to the "Nicolae Testemițanu" State University Of Medicine And Pharmacy, October 15-19, 2018, Chișinău, Moldova; National Scientific-Practical Conference with International Participation celebrating 90 years since the birth of the illustrious scholar Nicolae Testemițanu, Chișinău, Moldova, September 29, 2017; Annual Scientific Conference of the Institute of Emergency Medicine for Young Specialists on "Updates and Controversies in the Management of Medical-Surgical Emergencies", Chișinău, Moldova, November 10, 2017; Conference dedicated to the "Nicolae Testemițanu" State University Of Medicine And Pharmacy days, October 18-21, 2016, Chișinău, Moldova.

The research was conducted in accordance with the principles of the Declaration of Helsinki and approved during the meeting of the Research Ethics Committee of "Nicolae Testemițanu" State University Of Medicine And Pharmacy No. 42 on April 23, 2015. The results were endorsed at the meeting of the Department of Oral and Maxillofacial Surgery and Oral Implantology "Arsenie Guțan" at "Nicolae Testemițanu" State University Of Medicine And Pharmacy on March 22, 2024.

**Publications Related to the Thesis Topic.** The obtained results have been published in 20 scientific papers, 5 oral presentations, and 5 posters; 2 patents and 2 innovations; 6 implementation acts.

**Volume and Structure of the Thesis.** The work is presented on 124 pages of printed text. The thesis was developed and structured according to the requirements of current normative acts and includes a table of contents, list of appendices, list of abbreviations, followed by the introduction, 4 chapters, general conclusions, practical recommendations, bibliography from 148 sources, and 10 appendices. The illustrative material includes 42 figures and 6 tables.

**Keywords:** severe atrophy, lateral sinus lifting, dental implants, mini plates, titanium mesh.

## **2. MATERIAL AND RESEARCH METHODS**

### **2.1 General Characteristics of the Research**

The study was multicentric, including patients who sought implant-prosthetic treatment at the University Dental Clinic No. 2 (Mihai Viteazu 1A street) and the "Masterdent" dental clinic during the period 2017-2021. To achieve the purpose and objectives of the research, a controlled clinical study with randomized selection of patients was planned. The patients were divided into two groups: a study group and a control group.

The study group consisted of 50 patients (23 women and 27 men with an average age of 50±9 years), who required lateral access maxillary sinus elevation (sinus lifting) with delayed implant placement. In this group, implants were installed simultaneously with the sinus lifting intervention (50 removable dental implants), with additional fixation using mini plates and titanium meshes.

The control group included 54 patients (24 women and 30 men with an average age of  $51 \pm 8$  years) who had removable dental implants inserted in the posterior sectors of the maxilla with lateral access sinus floor elevation.

#### **Inclusion Criteria for Patients in the Study:**

1. Patients with edentulism in the posterior sectors of the maxilla who required implant-prosthetic rehabilitation with lateral access maxillary floor elevation (Misch class SA3-4) [70].
2. Patients where the residual subantral bone allowed for implant stabilization.
3. Patients aged over 18 years.
4. Patients who agreed to participate in the study and signed the informed consent and information form.

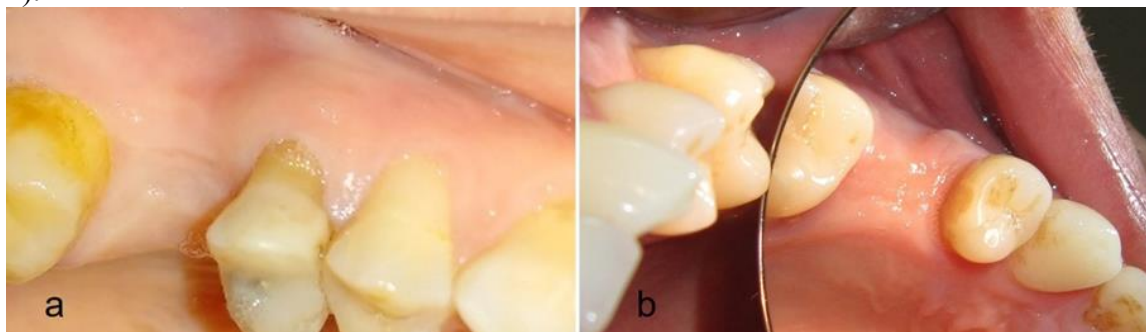
#### **Exclusion Criteria for Patients in the Study:**

1. Patients with decompensated general diseases.
2. Patients who refused to sign the informed consent.
3. Psychologically unstable or uncooperative patients.
4. Patients who required delayed implant insertion after the sinus lifting procedure.
5. Patients who did not require sinus lifting interventions.
6. Patients with a general medical history predisposed to allergies.
7. Patients with moderate to severe periodontal disease.

#### **2.2 Examination and Investigation Methods**

The clinical examination of the patients was conducted through both extra- and intra-oral examinations. Particular attention was given to the medical history to exclude contraindications for guided bone regeneration (GBR) procedures and dental implant placement.

The intraoral examination involved assessing the condition of the dental arches, dento-periodontal tissues, soft tissues, and measuring the dimensions of the edentulous spaces. In the edentulous posterior sectors of the maxilla, the condition and level of the alveolar ridge in relation to the alveolar process at the level of the teeth adjacent to the gap were analyzed, and the coronal space was determined. The quantity and quality of the gingival tissues were evaluated to determine the need for mucosal grafting procedures or vestibuloplasty (Fig. 1).



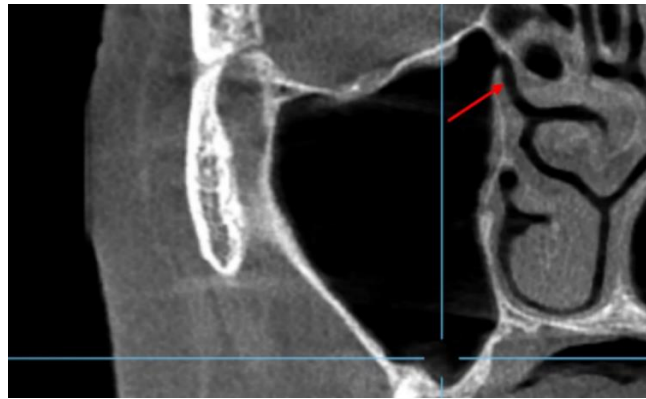
**Figure 1. Evaluation of the mesio-distal and vertical coronal space, quality and quantity of soft tissues, level of the alveolar ridge in relation to the process of adjacent teeth (a, b)**

For the analysis and interpretation of data, the following parameters were recorded: the number and location of missing teeth, the required number of implants, the quantity and quality of soft tissues, the quantitative and qualitative offer of bone (according to Misch, Leckholm, and Zarb classification), and the volume of residual subantral bone (ORS) (according to the SA - Misch and Judy classification) [34, 33]. These parameters were determined following clinical and paraclinical examinations (CT). For the study, only patients presenting with SA 3 and SA 4 bone atrophy, either due to partial resorption of the

alveolar ridge or due to the phenomenon of maxillary sinus pneumatization, or both, were included.

The paraclinical examination of patients focused on radiological assessment and, when necessary, laboratory analysis (blood tests). The initial paraclinical evaluation was based on orthopantomograms (OPG) for patients who already had this available. For the analysis and planning of implant-prosthetic rehabilitation, all patients underwent cone beam computed tomography (CT). The condition of the dento-periodontal tissues, levels of alveolar ridges, and processes were also evaluated and compared with their clinical appearance.

Before planning the implant-prosthetic rehabilitation, based on CT, the condition of the maxillary sinus mucosa, the permeability of the ostiomeatal complex, the presence or absence of foreign bodies in the sinus as well as periapical processes of the remaining teeth that could provoke reactions in the maxillary sinus were evaluated (Fig. 2). In situations where patients presented pathologies that could jeopardize the treatment results (lack of permeability of the ostiomeatal complex, severe nasal septum deviations towards the affected side, sinus mycoses, or the sinus mucosa showing signs of inflammation or having a thickness over 4-5 mm), patients were excluded from the study and treated according to indications.

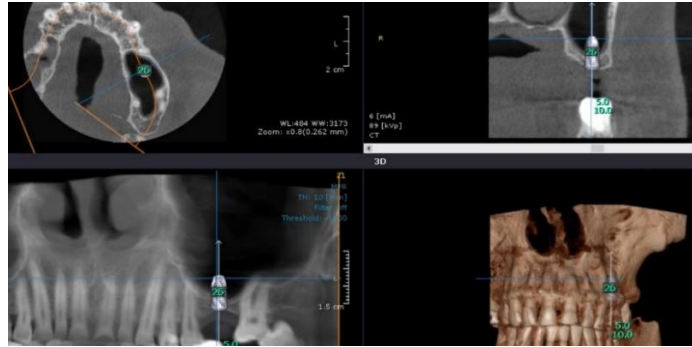


**Figure 2. CT Section: Evaluation of the ostiomeatal complex (arrow) and the state of the maxillary sinus mucosa.**

Using CT, the bone volume in the edentulous sectors was assessed (based on Misch's classification) [33], bone density according to Leckholm and Zarb's classification, as well as using the pseudo-Hounsfield units available in the CBCT analysis program. Another key parameter was the height of the residual subantral bone (according to the SA classification by Misch) [33].

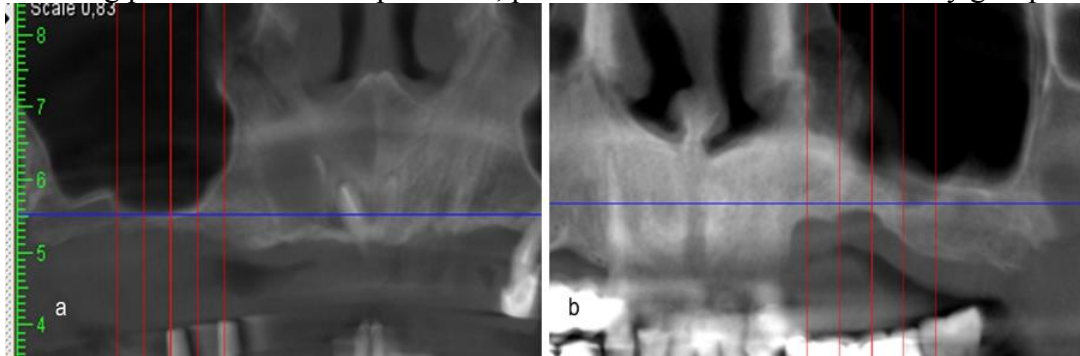
Patients included in the study corresponded to SA3 class (5-8 mm) and SA4 (< 5 mm). These criteria allowed the determination of the possibility of inserting implants simultaneously with the procedure of elevating the maxillary sinus floor or in a delayed manner. Depending on the feasibility of inserting dental implants concurrently with the sinus-lifting procedure, patients were allocated to the control group (simultaneous) or the study group (those requiring two separate procedures). Thus, in situations where there was a possibility of stabilizing the implants in the residual subantral bone, patients were assigned to the control group (Fig. 3).





**Figure 3. Patient G. Evaluation of the residual subantral bone based on CT and planning of the implant position in relation to the existing bone and the required prosthetic position.**

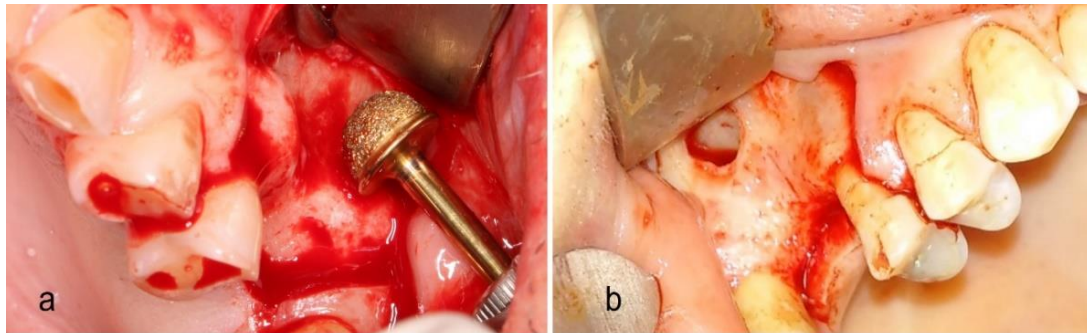
In cases where bone atrophy was due to either the process of excessive pneumatization of the maxillary sinus (Fig. 4a) or alveolar ridge atrophy (or both, Fig. 4b), and the possibility of securing the implants in the residual subantral bone concurrently with the sinus lifting procedure was compromised, patients were allocated to the study group.



**Figure 4. CT Sections: residual subantral bone atrophy due to maxillary sinus pneumatization (a), vertical atrophy of the alveolar ridge (b)**

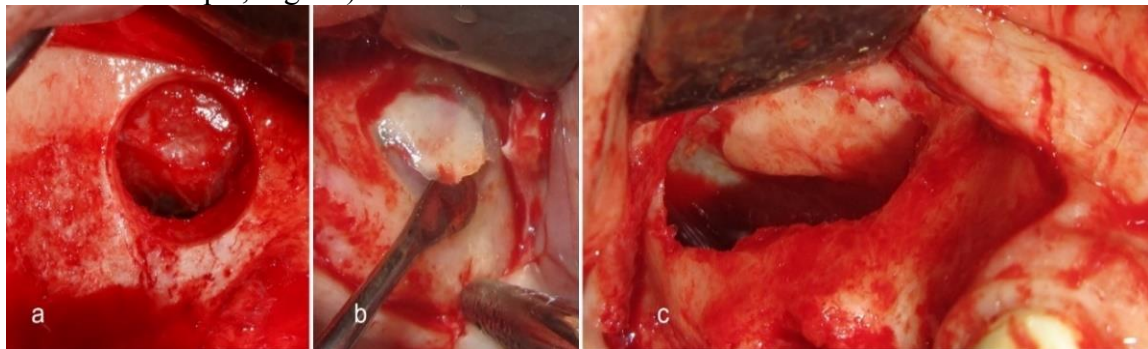
### **2.3. Surgical Protocol Applied to Patients in the Control Group**

All patients undergoing surgical treatment were subjected to scaling and pre-operative brushing procedures. Before the surgical intervention, the external mouth area was treated with a 70% alcohol solution, followed by a 30-second oral cavity rinse with 0.05% chlorhexidine gluconate solution. Infiltrative anaesthesia was administered using articaine with adrenaline (1:100000). After anaesthetizing the surgical field, an incision was made, and the mucoperiosteal flap was elevated. The design of the flap was determined so that its base was more comprehensive than the incision line at the alveolar ridge level, and the relieving incisions were at least 5 mm away from the access window to the maxillary sinus. In cases where the access window was near adjacent teeth (single-tooth defects), the flap was created as necessary, involving at least one mesial and distal tooth to ensure sufficient mobility and visibility (Figure 5a,b). The technique for creating the window was planned in advance and also influenced the flap size.



**Figure 5. Creation of the trapezoidal flap involving a mesial tooth (a), mesial and distal teeth (b)**

After the elevation of the mucoperiosteal flap and exposure of the lateral wall of the maxillary sinus, the margins of the access window were marked. The window was then created using a large diamond bur (Fig.5a) for the window scraping technique (grind-out, Fig. 5b), or with extra-hard and small-sized diamond burs in the case of the window removal technique (out-fracture, Fig. 6b), as well as conventional antrostomy (reverse window technique, Fig. 6c).



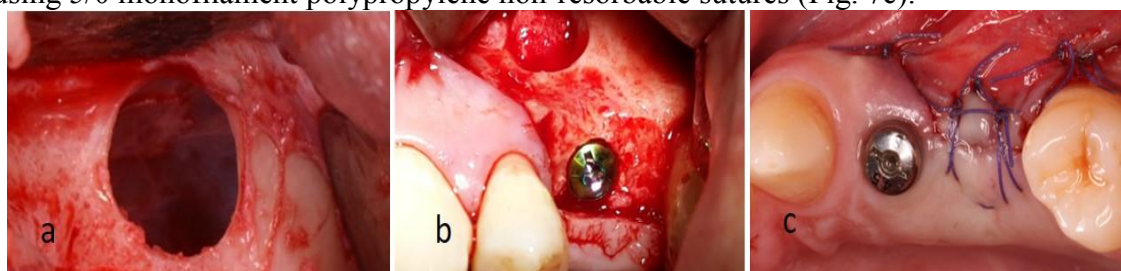
**Figure 6. Techniques for accessing the maxillary sinus: window scraping (a), window removal (b), reverse window technique (c).**

After creating access to the maxillary sinus membrane, it was gently elevated using specific elevators, maintaining constant contact with the maxillary sinus walls. After elevation, the increased height at the vestibular and palatal levels was checked (which must be at least equal to the height of the implant portion penetrating the sinus), and then at the mesial and distal ends. If the membrane was perforated, the size of the perforation was evaluated, and the possibility of repairing it with platelet-rich fibrin (PRF) membranes and collagen membranes was determined. In cases where the perforation size was too large, it was repaired by suturing and isolating with collagen membranes as feasible, and patients were excluded from the study to avoid erroneous results. The number of perforation cases was included in the statistical analysis.

Following the membrane integrity evaluation (Fig. 7a), the elevated space was augmented with collagen sponges and hydroxyapatite (Colapol KPLM). PRF membranes were also used for enhanced regeneration. The drilling of the implant sites was conducted according to the manufacturer's recommendations. Additionally, the height of the residual subantral bone was considered, and under-preparation of the sites was performed as necessary to ensure a primary stability of at least 15Ncm.

The study used removable implants ranging from 4 to 5 mm in diameter and 8-12 mm in length. To ensure primary stability, dental implants with a non-aggressive thread and with an expanded platform were used (sandblasted and acid-etched surface, conical and hex connection). After inserting the implants into the prepared sites, their platforms were irrigated with isotonic solution, and healing screws were applied to assess Periotest values,

which were later replaced with cover screws (Fig. 7b). The flap was sutured without tension using 5/0 monofilament polypropylene non-resorbable sutures (Fig. 7c).

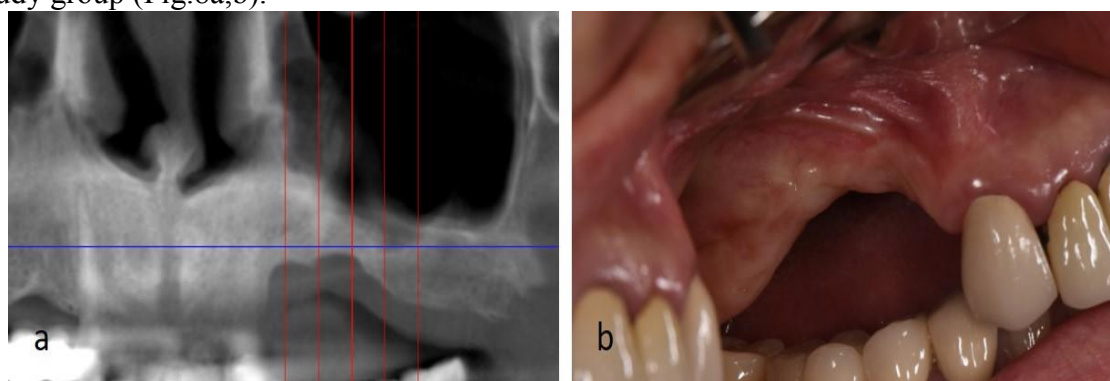


**Figure 7. Intraoperative stages: checking the membrane after elevation (a); verifying the sinus window after augmentation and implant insertion (b); suturing the mucoperiosteal flap (c)**

Postoperatively, all patients were treated with antimicrobial, anti-inflammatory, and antiseptic medication. For the prophylaxis of inflammatory complications, amoxicillin 0.875g with clavulanic acid 0.125g was prescribed twice a day for 7 days (treatment initiated on the day of the surgery, preoperatively). To reduce postoperative pain, ibuprofen 0.4g or 0.6g was used 2-3 times a day for 3-5 days. As a local antiseptic remedy, rinses with 0.12% chlorhexidine solution were recommended. To enhance sinus compliance, steroid anti-inflammatories in the form of a nasal spray were indicated. All patients underwent postoperative paraclinical evaluation through OPG or CT.

#### **2.4. Surgical Protocol Applied to Patients in the Study Group**

In cases where patients presented with residual subantral bone (SA4 class according to Misch) [33] less than 3 mm thick, which did not allow for the stabilization of implants and/or placement of the platform at the level of the alveolar ridge, either due to sinus pneumatization and/or vertical atrophy of the ridge, these patients were included in the study group (Fig.8a,b).

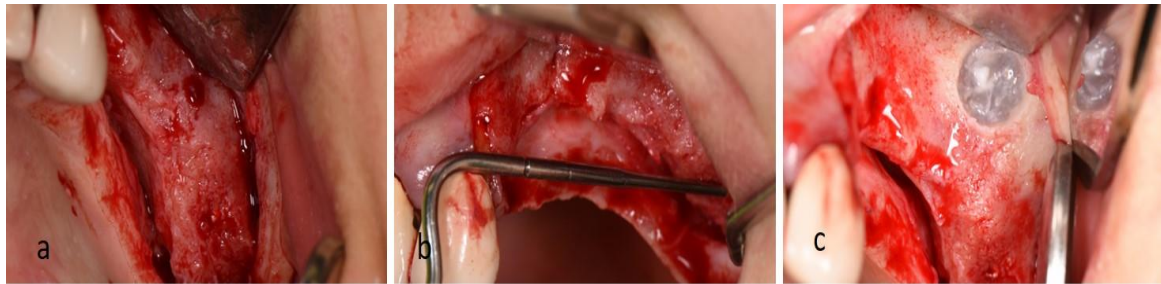


**Figure 8. Patient B. Pneumatization of the maxillary sinus and vertical atrophy of the alveolar ridge: CT fragment (a); intraoral view – mirror image (b)**

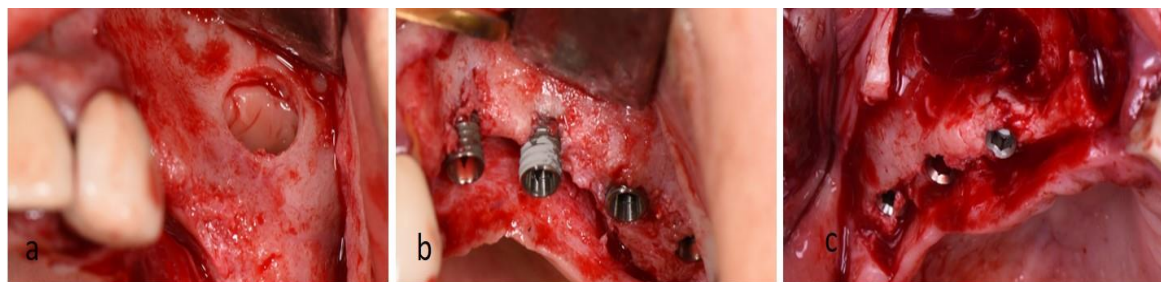The surgical intervention was conducted following the same surgical principles, however, unlike the control group, the final stage of the intervention was modified for these patients to ensure the stability of the implants. After the elevation of the mucoperiosteal flaps and creating access to the maxillary sinus, augmentation of the elevated space was performed similarly to the study group (Fig. 9, 10a).

Drilling of the implant sites was carried out considering the diameter of the implants, which were inserted at speeds of 20-30rpm until the platform was correctly positioned biomechanically (in cases of vertical atrophy, these remained extraosseous (Fig. 9b and 10b). In situations where vertical atrophy was insignificant, the implant platforms were positioned juxtacrestally, to avoid propelling the implant into the augmented intrasinus space (Fig. 10c).





**Figure 9. Stages of the surgical intervention: elevation of the mucoperiosteal flap (a); evaluation of the vertical atrophy of the alveolar ridge (b); creating access to the maxillary sinus membrane (c)**

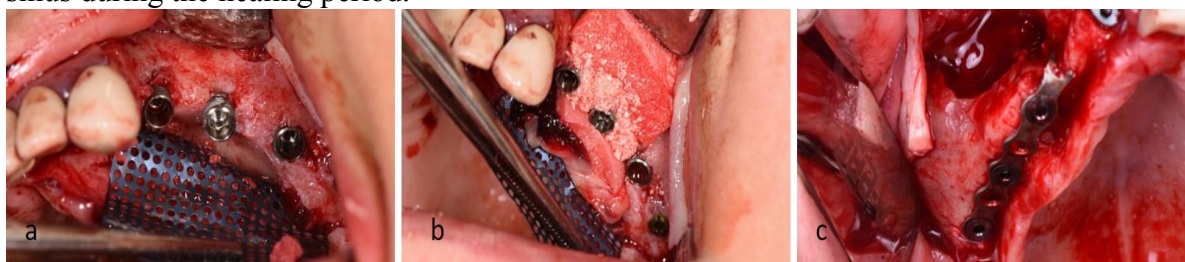

**Figure 10. Etape de augmentare a sinusului maxilar (a) și inserarea implanturilor cu plasarea platformelor extraos (b) și juxtacrestal (c)**

In situations where the implant platforms were positioned extraosseously, after assessing their stability, titanium meshes were used for vertical bone augmentation. These were fixed to the bone plane using titanium screws and served as a framework for guided bone regeneration (ROG) (Fig. 11a,b). In cases where the insertion force of the implants was below 10-15Ncm, for additional stabilization, they could be consolidated with the titanium membrane using cover screws (in such cases, the membrane was perforated at the implant platforms and was interposed between the implant and the cover screw).

In situations where the bone atrophy was due only to sinus pneumatization and the residual subantral bone did not allow for the stabilization of the implants, they were additionally fixed using an intraoperatively adjusted titanium miniplate. The miniplate was also connected to the implants via the cover screws (Fig. 11c).

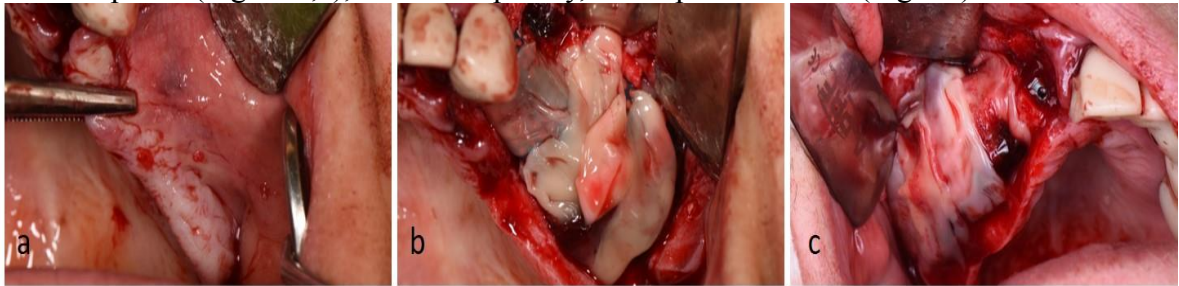These additional implant fixation techniques aimed to create the possibility of simultaneous implant insertion and reduce the risk of implant migration into the maxillary sinus during the healing period.



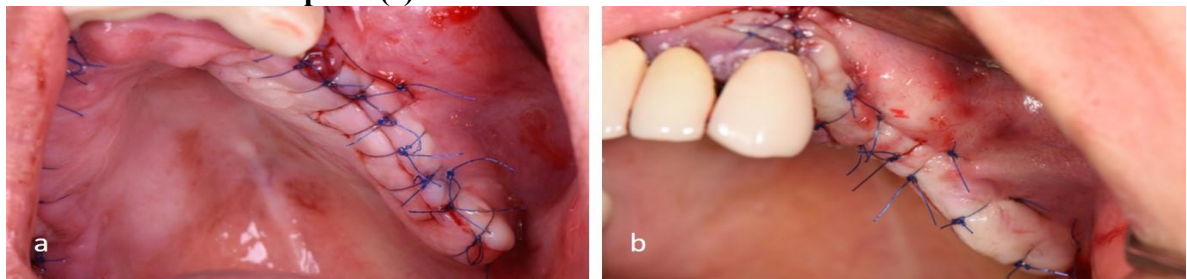
**Figure 11. Use of special systems for guided bone regeneration and additional implant fixation: application of the titanium mesh and bone addition (a,b); consolidation of implants through a titanium miniplate fixed with healing screws (c).**

Both bone regeneration using titanium meshes and consolidation with titanium miniplates required procedures for mobilizing the mucoperiosteal flap to cover the wound without tension (Fig. 12a). To reduce the risk of wound dehiscence and facilitate tissue

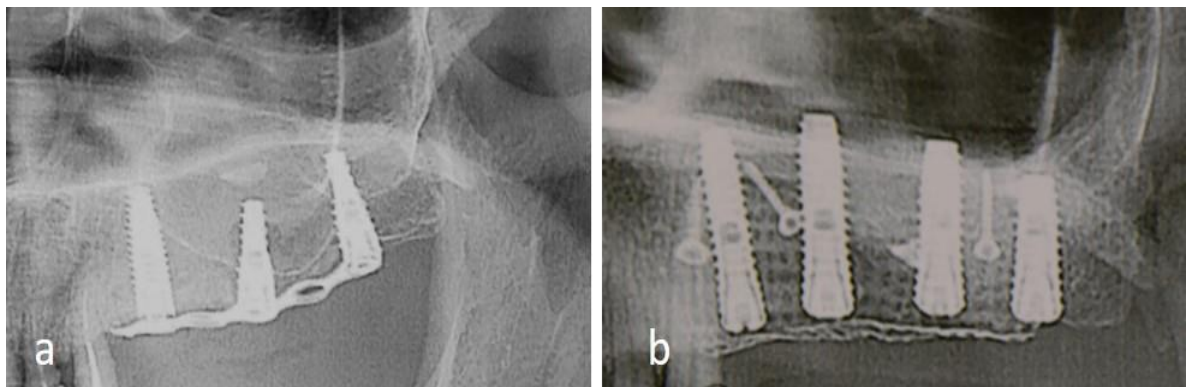
regeneration, PRF (platelet-rich fibrin) membranes were applied over the titanium mesh and miniplates (Fig. 12b,c), and subsequently, the flap was sutured (Fig. 13).



**Figure 12. Fragments of the intraoperative stages: mobilization of the flap and checking its elasticity (a); application of PRF membranes over the titanium mesh (b) and the titanium miniplate (c).**



**Figure 13. Suturing the wound without tension: from a transverse view (a), from a vestibular view (b). The postoperative radiographic evaluation and medical treatment were performed similarly to the control group (Fig. 14).**



**Figure 14. Postoperative Paraclinical Evaluation, OPG Fragments: Miniplate (a) and Titanium Mesh**

### **2.5. Patient Evaluation During the Healing Period**

Postoperatively, all patients were regularly monitored through follow-up visits (at 1, 3, 7, and 14 days, 1, 3, and 6 months postoperatively). During these visits, the following parameters were evaluated: postoperative swelling, healing of the postoperative wound, presence or absence of wound dehiscence, peri-implant dehiscence, and other local inflammatory processes or at the level of the maxillary sinuses. All these were recorded in the patients' medical records and included in the statistical analysis. At the end of the healing stage, the dental implants were exposed, and healing screws were applied. For the study group patients, titanium meshes and miniplates were removed, the macroscopic appearance of the peri-implant tissues was evaluated, and healing screws were applied. The secondary stability of the implants was assessed based on periotestometry. Radiological control was conducted to evaluate the condition of the newly formed peri-implant and

intrasinusal bone. After the regeneration of soft tissues, provisional or definitive prosthetic treatment was performed as necessary.

## **2.6. Statistical Processing Methods for Results**

The data collected were processed using SPSS26 software. For continuous (numerical) parameters, the minimum value, maximum value, mean with standard deviation, and median with the 25th and 75th percentiles were estimated, all as part of descriptive statistics. Comparative evaluations for continuous variables were calculated using non-parametric tests according to the number of groups formed (the Mann-Whitney-Wilcoxon test for two dependent/independent groups or the Friedman test for three dependent groups, with multiple comparisons (non-parametric methods) applied as needed, with Bonferroni corrections). Visualization was achieved through histograms or boxplot graphs.

For qualitative variables, we estimated absolute frequencies, relative frequencies, completed with 95% confidence intervals, ensuring a comprehensive understanding of the data. Visualization was performed using barplot graphs, a method that offers a clear and intuitive representation of the data. Null hypothesis testing regarding the absence of associations was conducted using Pearson's Chi-square test (Monte Carlo version), a rigorous method that provides reliable results.

Correlational analysis was performed using Spearman's  $\rho$  test, a non-parametric test, which, unlike the Pearson test, does not require specific conditions for application.

In regression analysis, calibration indicators (Hosmer and Lemeshow test), discrimination indicators (sensitivity and specificity, organized in tables), and Nagelkerke R Square (determination coefficient) were estimated. In addition to these features, coefficients for the mathematical expression of the obtained results were estimated; formulas were necessary to apply validated or developed scores in practice. These were complemented by the odds ratio (OR) with confidence interval—a fundamental indicator for interpreting parameters included in the model.

For all statistical tests applied in the current study, we adhered to the widely accepted threshold value ( $\alpha$ ) of 0.05, ensuring the reliability and validity of our findings.

## **3. OBTAINED RESULTS**

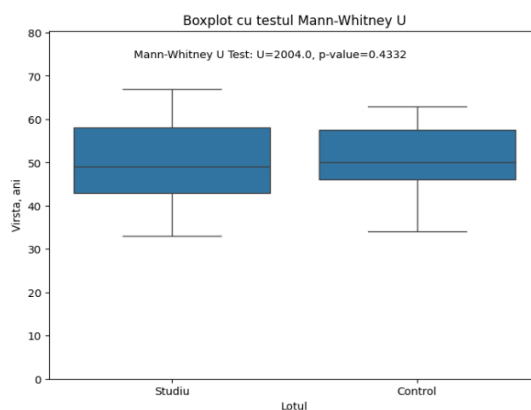
### **3.1. General Results of the Study Groups**

The data was meticulously analyzed, and in the control group patients, according to paraclinical data (CT), a residual subantral bone corresponding to SA3 and SA4 classes according to Misch and Judy's classification [33] was established.

The respondents in the control group were categorized based on their age, ranging from 34 to 63 years, with an average age of 51 and a standard deviation of 8 years. The established median age was 50, and the interquartile range, between the 25th and 75th percentiles, was between 34 and 58 years, respectively. In this group, males predominated at 54.1% (95% CI 42.7-65.1), with females having a relative frequency of 45.9% (95% CI 34.9-57.3).

The research group, had respondents aged between 33 and 67 years, with an average age of 50 and a standard deviation of 9 years. The median age was 49 years, and the interquartile range varied from 43 years (25th percentile) to 58 years (75th percentile). This detailed age distribution provides a comprehensive understanding of the study's sample.

The Mann-Whitney U test, a robust statistical tool, was employed to determine if there was a significant difference in the age of the patients included in the study between the two research groups. The result,  $U = 2004.0$ , was statistically insignificant ( $p = 0.43$ ). This indicates that there is no significant difference in the distribution of patients included in the study by age, as observed in the histogram (Fig. 15), thereby validating the study's design and methodology.



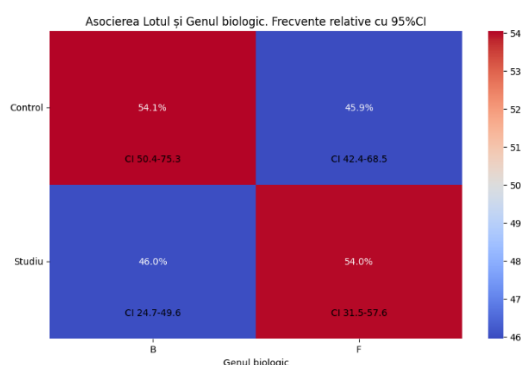
**Figure 15 Comparative analysis of age distribution in the study groups.**

The gender distribution of the respondents in the study group was represented by 54.0% (95% CI 40.3-67.3) females and 46% (95% CI 32.7-59.7) males.

After analysing the research groups and correlating with gender, the result obtained after applying the continuity correction was statistically insignificant ( $\chi^2 = 0.486$ ;  $p = 0.48$ ). Therefore, there is no statistically significant association between gender and the applied treatment method. This is also observed in the histogram from (Fig. 16), where the distribution by gender in the research groups shows no difference.

P-value: 0.4858

Chi-squared: 0.49



**Figure 16. Comparative analysis of gender distribution in the research groups.**

### 3.2. Evaluation of Post-Extraction Periods in the Researched Groups

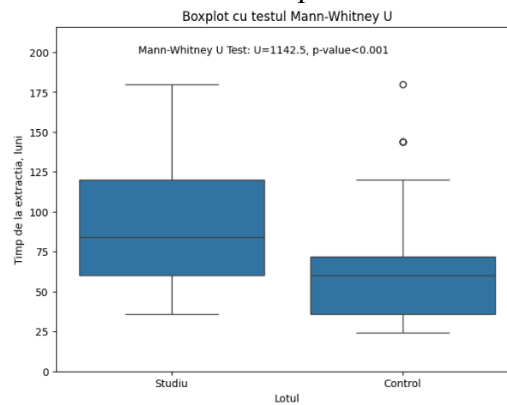
Considering that the maxillary sinus undergoes dimensional changes throughout a patient's lifetime, and dental extractions increase the chances of its pneumatization, insufficient bone supply for implant placement can be found both at the molar and premolar levels.

The time from extraction, whether reserved for necessary dental manipulations before an implant or prolonged due to other patient-induced reasons, is often not in the patient's favour. In the current study, the time from dental extraction varied considerably, ranging from a minimum of 36 months to a maximum of 180 months for the study group, with an average of 94 months and a standard deviation of 42 months. The median was 84 months, and the interquartile range was between 60 and 120 months. In the control group, the average time from extraction was 69 months, with a variation range of 24 to 180 months and a standard deviation of approximately 40 months. The recorded median was 40 months, and the interquartile range was between 36 and 72 months.

After evaluating the post-extraction periods, a statistically significant difference in data distribution was observed in the research groups following the Mann-Whitney U test



calculation = 1142.0 ( $p < 0.001$ ). Analyzing the histogram from (Fig. 17), it is evident that a shorter period from the moment of extraction predominates in the control group.



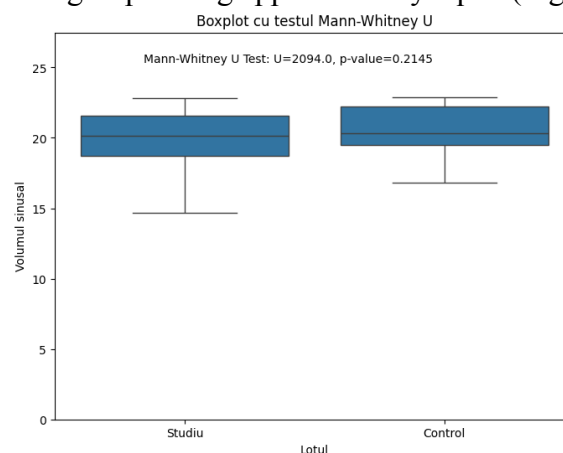
**Figure 17. Comparative analysis of distribution by time from extraction measured in the study groups.**

### 3.3. Evaluation of Sinus Shape, Volume, and Grafting Materials in Patients Included in the Study

The shape and volume of the maxillary sinus play a significant role in developing the treatment plan, choosing the access method, and selecting the types of biomaterials and postoperative regeneration terms. Consequently, these were also studied and described in the study groups. In the study group, the maxillary sinus values ranged from a minimum of 14.7 to a maximum of 22.8, with an average of 20.1 and a standard deviation of 1.7. The median value was 20.2, and the interquartile range was between 18.7 and 21.6. In the control group, the sinus volume values ranged from a minimum of 16.8 to a maximum of 22.9, with an average of 20.6 and a standard deviation of 1.5. The median value series was 20.4, with an interquartile range between 19.5 and 22.2.

The analysis of the shape and volume of the maxillary sinus (in "U" or "V" shape), the calculated Mann-Whitney U test shows that there are no significant differences in data distribution between the research groups  $U = 2094.0$  ( $p = 0.21$ ). However, in both research groups, cases are predominant with a large sinus volume (Fig. 18).

Besides volumetric parameters, the analysis of the maxillary sinus shape based on the Pearson Chi-square test to check for a correlation between the sinus shape and applied treatment (comparison between groups), after using the continuity correction yielded 0.56, a result that was not statistically significant ( $p = 0.45$ ). In other words, there is no statistically significant association between the sinus shape and implant outcomes, with frequencies in the research groups being approximately equal (Fig. 19).

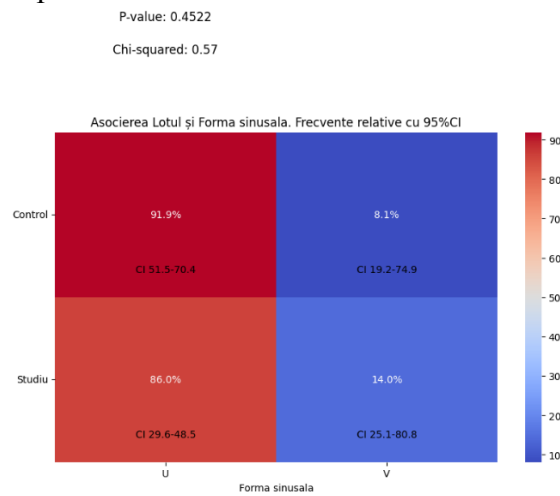


**Figure 18. Comparative analysis of sinus volume distribution in the study groups.**



Considering the "V" or "U" shape of the maxillary sinus (as per the data in Table 19) and the fact that the vestibulo-oral dimension of the maxillary sinus can vary, thus affecting the degree of its pneumatization, various augmentation materials were used for maxillary sinus floor elevation procedures. Given their properties, the most favourable material for augmentation remains the blood clot and its derivatives due to their osteoconductive and osteoinductive properties. However, the retraction and resorption of the clot present a high degree of postoperative pneumatization, making it unfavourable as a biomaterial in sinuses with large buccal and palatal dimensions. Therefore, this material was only used in sinuses with small dimensions (buccal palatal ) to reduce the risk of pneumatization.

Another favourable material for interventions performed in the study was collagen-based grafts with hydroxyapatite due to their sponge-like structure, which is gentle on the sinus membrane and does not pose a risk of perforation during the postoperative period. Additionally, it can be easily soaked with blood or PRF to facilitate the postoperative regeneration process. A disadvantage is the same tendency in pneumatic sinuses to reduce the height of the grafted space.

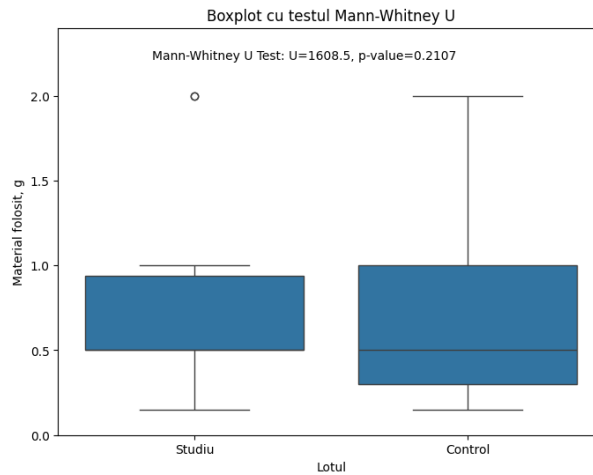


**Figure 19. Evaluation of the distribution of the sinus shape in "V" or "U" within the research groups**

The quantity of material used for ensuring primary stability ranged from a minimum of 0.15 g to a maximum of 2.00 g for both groups included in the study. The average was 0.63 g with a standard deviation of 0.39 g for the first study group and 0.64 g with a standard deviation of 0.50 g for the study group. The median of the data series for both groups was 0.50 g, with an interquartile range of 0.50 g and 1.00 g for the first group and 0.30 and 1.00 for the second group.

The type of material used was of 3 categories: collagen sponges with hydroxyapatite, xenograft + autologous bone, and blood clot and its derivatives. The collagen sponge-based material was used at a rate of 60.0% (95% CI 46.2-72.7) in the study group and 47.3% (95% CI 36.2-58.6) in the control group. Xenograft + autologous bone was used at a lower frequency of 34.0% (95% CI 22.1-47.7) in the first lot (study) and 25.7% (95% CI 16.8-36.4) in the control group. The blood clot was administered in only 6.0% (95% CI 1.7-15.2) in the study group and 27.0% (95% CI 17.9-37.9) in the control group.

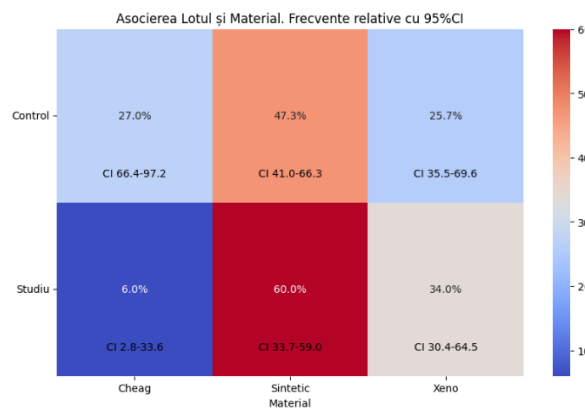
The quantity of material used did not show differences in distribution across the research groups. The calculated Mann-Whitney test ( $U = 1608.5$ ) demonstrates a statistically insignificant difference ( $p = 0.2$ ) in the data distribution in both the study and control groups. In the histogram from (Fig.20), a uniform distribution of the used material is observed in both groups.



**Figure 20. Comparative analysis of distribution by the quantity of material used measured in the study groups.**

A statistically significant result was obtained after the Pearson Chi-square test to determine if there is an association between the type of material used and the applied methods (8.74,  $p = 0.013$ ). Thus, a statistically significant association exists between the material used and the research group. A higher frequency of collagen-based material used in the study group than in the control group is noted (Figure 21), and more frequent blood clots are used in the control group.

P-value: 0.0126  
Chi-squared: 8.74



**Figure 21. Comparative analysis of distribution by type of material used in the study groups.**

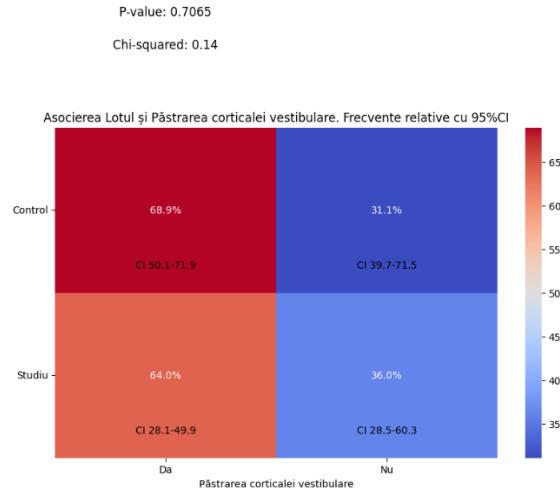
This is because in the control group, there is a greater quantity of residual subantral bone compared to the study group, and the space augmented with blood derivatives was maintained both by the graft itself and by implants (the cort phenomenon). Additionally, considering that in the study group the bone supply did not allow for stable dental implant placement and the maxillary sinus predominantly in "U" shape, the use of xenografts + autologous bone was more frequently used due to their increased resistance to reneumatization forces.

### 3.4. Evaluation of the Influence of Access Windows on Research Outcomes.

As described in Chapter 2, access to the maxillary sinus was achieved through multiple techniques. For small defect sizes (1-3 teeth) to reduce the defect of the vestibular wall, the window scraping technique was chosen, which reduced operative time. For larger

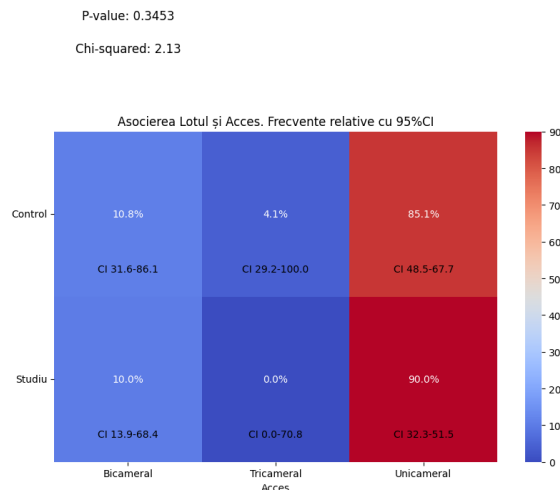
edentulous areas (over 3 teeth) and the need to augment a larger volume, bicameral access creation or the reverse window technique (conventional antrostomy) was opted for.

The comparative analysis of the type of access reflected a statistically insignificant distribution (Pearson Chi-square 0.142,  $p = 0.70$ ) of access paths in both research groups, which indicates the lack of impact of the augmentation technique (study or control group) on the type of access to the maxillary sinus (Fig. 22).



**Figure 22. Access is distributed through scraping or repositioning the window (red) and the reverse window (blue) in both research groups.**

After analyzing the number of windows created for access to the maxillary sinus, following the application of the Pearson Chi-square test, a statistically insignificant result was obtained (2.12,  $p = 0.34$ ). Both research groups predominantly used the unicameral access method, with a few cases of tricameral access in the control group (Fig. 23).



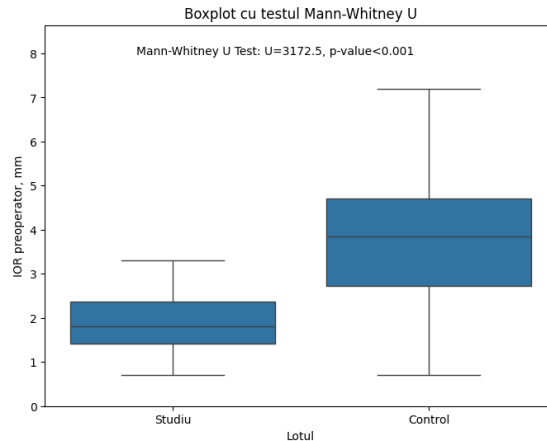
**Figure 23. Evaluation of the number of access windows to the maxillary sinus in both research groups.**

In the clinical case analysis, bicameral and tricameral accesses were used more frequently due to incomplete but prominent secondary septa in some instances. The bicameral accesses allowed for the avoidance of perforating the sinus membranes during their elevation.

### 3.5. Evaluation of Residual Subantral Bone and Evolution of the Augmented Space During the Healing Period

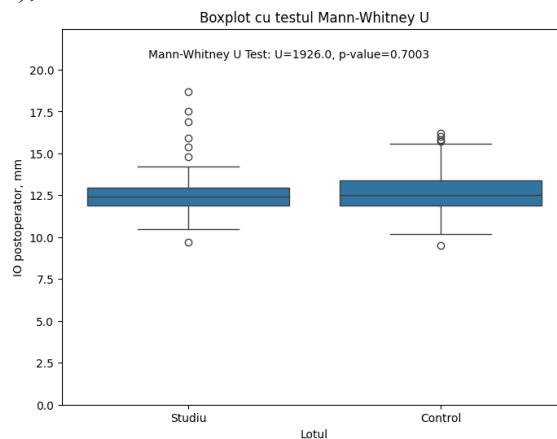
A fundamental aspect of the rehabilitation of patients within the study was the creation of peri-implant bone supply, particularly in height. Following paraclinical evaluations, the

comparative evolution of the residual subantral bone and the formation of new bone at the end of the healing period both within and between groups were analyzed. The pre-operative height of the residual bone determined based on CBCT scans varied significantly in both research groups. This was demonstrated by the result of the Mann-Whitney U test = 3172.5 ( $p < 0.001$ ), which had quite significant statistical power. It is evident that cases with greater residual bone height predominated in the control group compared to the study group (Fig.24). From the data reflected in the histogram (Fig.24), it can be seen that the pre-implant bone supply is greater in the control group than in the study group, supporting the possibility of implant stabilization following the procedure (in the control group) compared to implants placed in the study group.



**Figure 24. Comparative analysis of distribution by height of the residual subantral bone in both lots.**

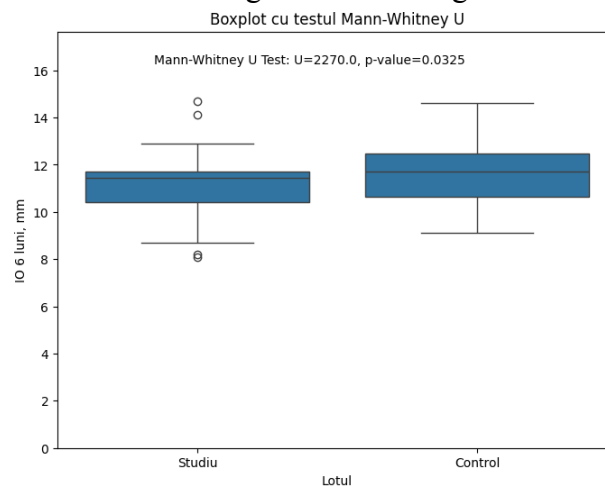
The values of the residual bone immediately post-operatively in the study group were recorded in a range with a minimum of 9.70mm and a maximum of 18.70mm, the average being 12.74mm, and the standard deviation was 1.69mm from the average in the first research lot. The median was approximately equal to the average, precisely 12.40mm, and the interquartile range between 11.90mm and 13.00mm. In the control group, this parameter immediately post-operatively fluctuated in a range with a minimum of 9.50mm and a maximum of 16.20mm, the average being 12.72mm, and the values deviated from this by 1.44mm. The median of the data series was 12.50mm, and the interquartile range was between 11.90mm and 13.40mm. The residual bone and graft height calculated immediately after the procedure did not vary significantly in the research lots. The Mann-Whitney U test resulted in a statistically insignificant  $U = 1926.0$  ( $p = 0.69$ ). Thus, in the histogram from (Fig. 25), it can be seen that there are no differences in distribution by lots.



**Figure 25. Comparative analysis of the distribution by total bone height immediately after surgery, measured in the study groups.**

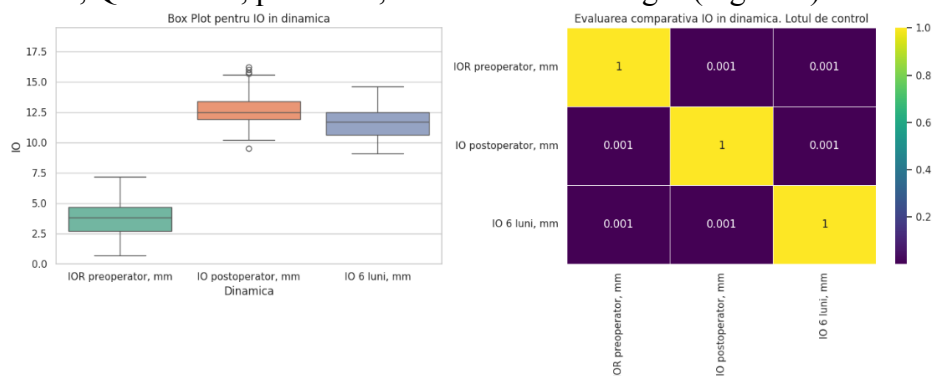
The lack of statistical difference between determined heights aligns with the fact that the distribution of implants between groups by height also showed no statistical differentiation (augmentation was proportional to the degree of implant penetration into the elevated space).

Bone height data at 6 months ranged from a minimum of 8.1mm to a maximum of 14.7mm in the first (study) group, with an average of 11.2mm and a standard deviation of 1.3mm. The median was 11.5mm, and the interquartile range was between 10.4mm and 11.7mm. In the second (control) group, bone height at 6 months was within a range from a minimum of 9.1mm to a maximum of 16.20mm, the average and median of the data series being 11.7mm, with deviations from this average of 1.3mm. The interquartile range was between the 25th percentile at 10.6mm and the 75th percentile at 12.5mm. At the end of the healing period, the differences in the distribution of bone height were statistically insignificant, with the Mann-Whitney U test reflecting a U value of 2270.0 ( $p = 0.03$ ). This indicates a predominance of cases with greater bone height in the control group (Fig. 26).

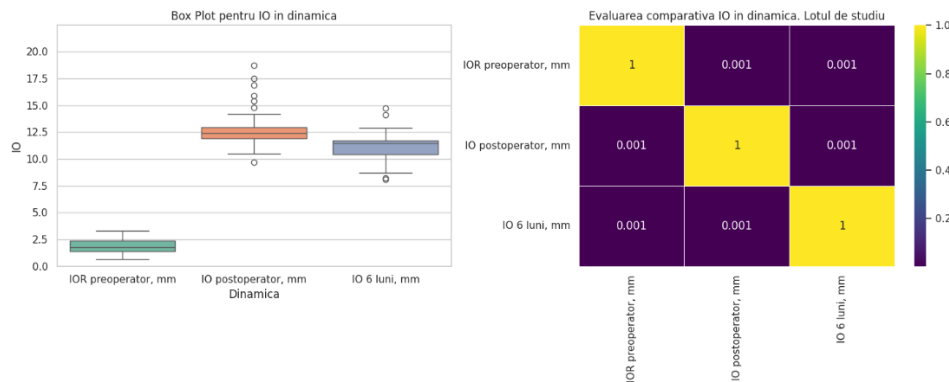


**Figure 26. Comparative analysis of the distribution by total peri-implant bone height after healing, measured in the study groups.**

Bone dynamics analysis within the control group reflected a statistically significant change (Friedman test,  $Q = 98.04$ ,  $p < 0.001$ , at all evaluation stages), which can also be observed in the histogram from (Fig. 27a). A similar result was observed in the study group (Friedman test,  $Q = 146.02$ ,  $p < 0.001$ , at all evaluation stages (Fig. 27b)).



**Figure 27a. Evolution of bone height at preoperative, postoperative, and end of integration period stages for the control group.**



**Figure 28b. Evolution of bone height at preoperative, postoperative, and end of integration period stages for the study group.**

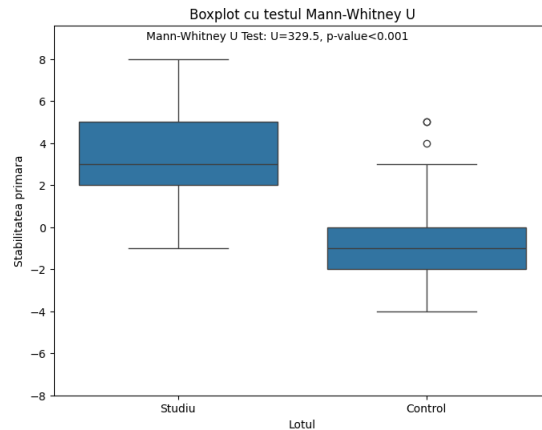
From the obtained data, it can be observed that the evolution of the bone has an oscillating dynamic, from a significant postoperative increase due to the augmentation process to a slight (yet statistically significant) decrease during the healing period. This latter phenomenon is due to several factors. According to data from Topalo and Mostovei [30,52], postoperative swelling shows a greater volume (radiologically) than the augmented space itself (in the case of using collagen grafts and blood derivatives, which are less opaque than xenografts and match the density of the sinus membrane).

On the other hand, the decrease in graft height during the augmentation period is due to the force of intrasinus repneumatization, which tends to compress the grafted volume toward the floor. Given that collagen grafts and blood derivatives were used in this study, this force ultimately led to a reduction in bone height during the integration of the grafts. This phenomenon is observed in both groups. Similar results regarding the evolution of intrasinus bone height have been published by other authors [3, 30, 52]. In such cases, implants, which act as the "tent pole" in maintaining the level of the intrasinus graft, are of significant importance. In their absence (according to the delayed implant placement protocol), along with the disadvantage of an increased number of interventions and associated risks, this phenomenon may be more pronounced.

### 3.6. Evaluation of Implant Stability

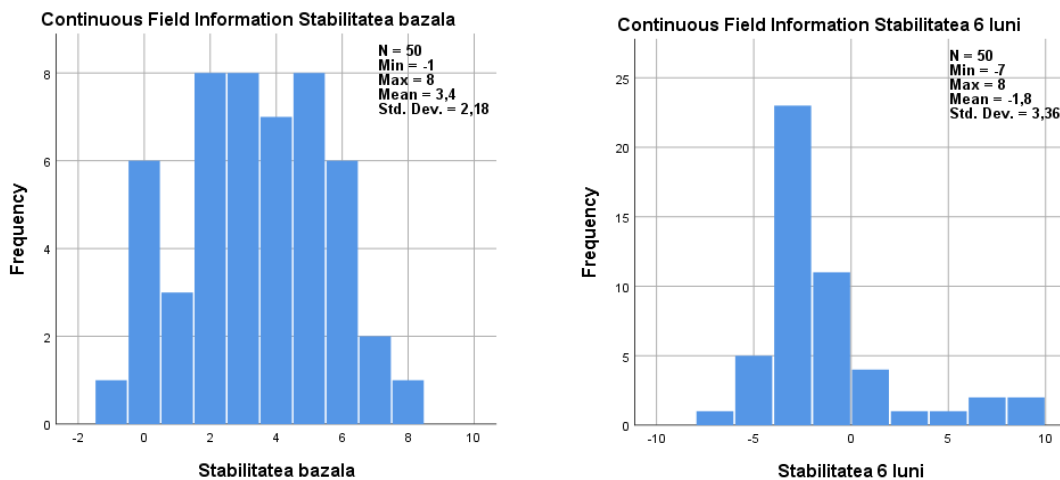
A criterion for the success of the treatment was the presence of newly-formed peri-implant bone at the end of the integration period, evaluated radiologically. However, this parameter does not necessarily indicate the functional demand capability of the implants, considering that the bone obtained must also meet qualitative parameters. Thus, the dynamics of both primary and biological stability of the implants (based on periotestometry) were analyzed, which were considered both a parameter of osseointegration and determined the prosthetic approach after the osseointegration period.

The primary stability values observed in the study group, which ranged from -1 to 8 with an average of 3, and a deviation from the average of 3, are of significant importance. This data, along with the median of the data series also being 3, and the interquartile range recorded between 2 and 5, provides a comprehensive understanding of the implant's performance in the study group. In comparison, the control group recorded slightly different values, with the primary stability values ranging from a minimum of -4 to a maximum of 5, and an average of -1. The standard deviation was 2, and the median of the data series was the same as the average, i.e., -1, with the interquartile range established between the 25th percentile = -2 and the 75th percentile = 0. The comparative analysis of primary stability between groups reflected a different distribution in the study lots  $U = 329.5$  ( $p < 0.001$ ), with a predominance of cases with greater primary stability in the control group (Fig. 29).



**Figure 29. Comparative analysis of primary stability between groups**

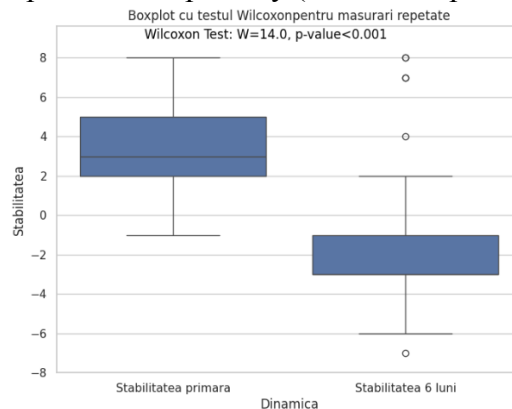
It's crucial to Consider the manufacturer's recommendations (Periotest, Siemens AG, Bensheim Germany) when assessing implant stability. According to these guidelines, the necessary values for the implants should be between 0 and -8. However, our study's data differ from these recommendations. This discrepancy is due to the operating principle of the periotest, namely the "damping" effect. In the case of implants inserted into post-extraction sockets and maxillary sinuses, the support point of the implant is either not at the level of its neck or is very small, which significantly alters the lever. For this reason, the values of primary stability recorded in the study group differ from those recommended and, at the same time, cannot be considered unfavourable (Fig. 30).



**Figure 30. Evaluation of the distribution of primary (left) and secondary (right) stability values of the implants in the study group**

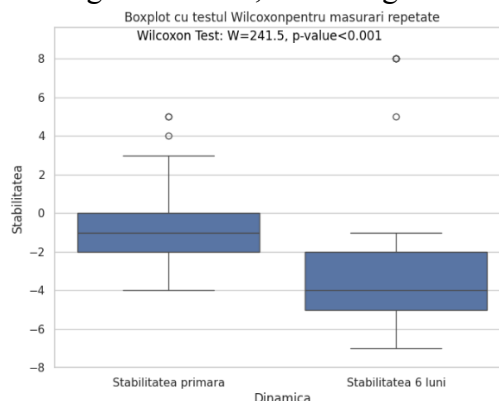
The comparative evaluation based on the Wilcoxon test calculated to determine if the stability measured at 6 months (secondary) is significantly different from the primary stability in the study group ( $W = 14.0$ ,  $n = 50$ ,  $p < 0.001$ ) shows a statistically significant difference in favour of the secondary stability, with a predominance of negative values (Figure 30). In the histogram from (Figure 31), it is observed that the majority of the implants (45 out of 50) had a trend towards negative values, reflecting an increase in the stability of the implants with the formation of new intrasinusal bone during the healing period. Only 4 implants analyzed in this group showed a loss of primary stability. The obtained data confirm that in evaluating the stability of implants inserted concurrently with the elevation of the maxillary sinus floor in insufficient residual subantral bone, the manufacturer's recommendations regarding preferred values of primary stability (less than

0) are not current for this type of intervention. On the other hand, the treatment method in the study group reflected a favourable dynamic of implants with significant improvement in secondary stability compared to the primary (which was practically absent).



**Figure 31. The evolution of stability towards positive and negative values on the periost in the study group.**

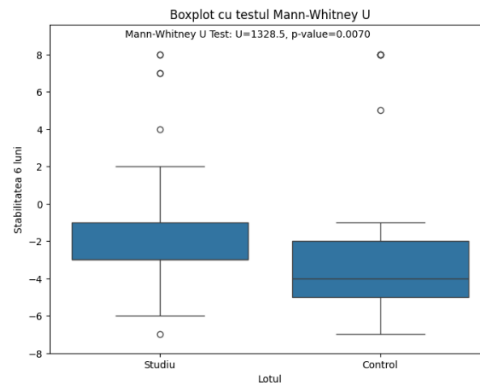
In the control group, the calculated Wilcoxon test to determine if the secondary stability measured at the end of the integration period was significantly different from the primary stability reflected a statistically significant difference in implant stability in favour of the secondary (W = 241.5, n = 74, p < 0.001). This finding is crucial as it underscores the importance of secondary stability in the long-term success of dental implants. Thus, in the histogram from (Figure 32), it can be observed that in this group as well, the stability of the implants has shifted towards negative values, indicating an increase.



**Figure 32. The evolution of implant stability in the control group.**

Stability after 6 months ranged from a minimum of -7 to a maximum of 8, for both research lots. The average for the study group was -2 with a standard deviation of 3, while the average for the control group was -3 with a standard deviation equal to that of the first lot. The median of the value series in the first (study) lot was -1, with an interquartile range from -3 to -1. In the control group, it recorded a value of -4 and an interquartile range between -5 and -2. These precise measurements, obtained through rigorous periostometry, provide a clear picture of the stability trends. Following the analysis of periostometry determined at the end of the integration period and postoperatively, it can be observed that implant stability values significantly increased after the osteointegration period, moving considerably towards negative values. This is due to the increase in the volume of peri-implant bone. Based on the Mann-Whitney U test = 1328.5 (p = 0.007), the result of comparing secondary stability between groups demonstrated a statistically significant difference in distribution of stability at 6 months in the research lots. In the histogram from (Figure 33), there is a higher cumulative frequency of better stability in the control group.





**Figure 33. Comparative analysis of the distribution of secondary stability measured in both lots.**

The statistical difference is because in the control group, there was a sufficient native bone substrate for the stabilization of implants suitable for their placement, while in the study group – there was a higher ratio of the graft to native bone; hence, at the end of the healing period, the implants were surrounded by more newly-formed bone (in the study group). Furthermore, in both the study and control groups, the obtained periostometry values are negative but closer to 0 than to -8. This indicator is because the newly-formed peri-implant bone has a lower density compared to situations where implants are installed in mature bone, such as in the mandibular sectors. Another peculiarity that impacts the stability of the implants is that the superior jaw presents a lower density compared to the inferior jaw.

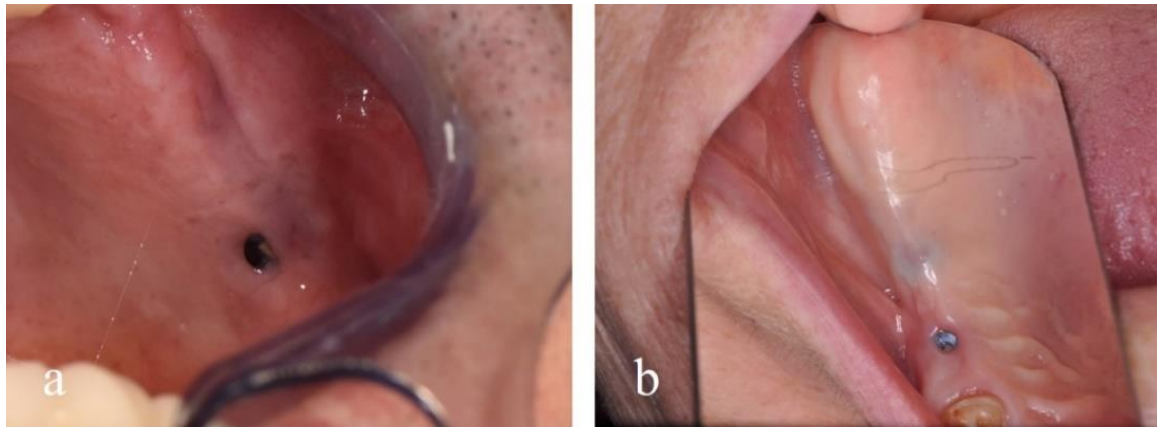
### 3.7. Evaluation of Accidents and Complications Encountered in the Research Groups

The complications observed in the implant-prosthetic rehabilitation of patients, both in the study and control groups, are of significant importance to our research.

These manifested as:

- The complications in the study and control groups included perforation of the maxillary sinus membrane, with 2 cases in the control group and 1 in the study group. dehiscence of the postoperative wound in the study group (3 cases of titanium mesh exposure and 2 cases of miniplate exposure),
- migration of the implant into the maxillary sinus (1 case in the study group), and
- Failure of implant integration (2 implants in the control group and 6 in the study group).

Early failure was also associated with exposure to the titanium mesh in one of the cases in the study group (2 failed implants). However, it's important to note that the other cases of mesh exposure did not disrupt the treatment, as they occurred at the end of the healing period. The exposure of the titanium miniplate occurred in 2 cases at the end of the integration period without affecting the completion of the treatment (Fig.34).



**Figure 34. Exposure of the titanium miniplate at the end of the healing period in 2 cases: from a distal view (a) and from a mesial view (b)**

In the control group, one intentional perforation of the maxillary sinus membrane was also recorded to remove an implant that migrated into the sinus during the healing period. Accidental perforations during the procedure (in both groups) were minor and did not require a change in the treatment plan due to their small size and the possibility of management by using PRF and collagen membranes. Early failures characterized by the failure of dental implant integration were not associated with infections of the grafting material. The failed implants were removed, and other implants were inserted after a 3-5 month regeneration period. Only in 1 case in the control group was a sinusotomy performed to remove the migrated implant in the sinus. Even in this case, the patient did not exhibit symptoms of maxillary sinus inflammation. Thus, the failures recorded in the study were observed with 6 implants in the study group and 2 implants in the control group.

#### **4. SYNTHESIS AND INTERPRETATION OF OBTAINED RESULTS**

##### **4.1. Correlational Analysis of the Studied Lot**

Results of Spearman correlation coefficients for determining the level of association between various factors studied during the research show that the evolution of the implant had a statistically insignificant correlation with the Study Lot (CC = 0.52, 95% CI -0.13, 0.22, p = 0.56), with Patient Age (CC = -0.03, 95% CI -0.16, 0.08, p = 0.7), with Intra-Operative Room (IOR) (CC = 0.07, 95% CI -0.13, 0.26, p = 0.4), with Sinus Volume (CC = -0.12, 95% CI -0.21, -0.03, p = 0.15), with Time from Extraction (CC = -0.10, 95% CI -0.29, 0.14, p = 0.27), with Length (CC = -0.01, 95% CI -0.13, 0.09, p = 0.8), and with Implant Diameter (CC = 0.01, 95% CI -0.14, 0.16, p = 0.9).

However, between Implant Evolution, Primary Stability (CC = -0.26, 95% CI -0.40, -0.07, p = 0.003) and Stability at 6 Months (CC = -0.43, 95% CI -0.55, -0.27, p < 0.001), the coefficient showed a weak, negative, and statistically significant correlation.

The Study Lot has a weak and statistically insignificant correlation with Patient Age (CC = 0.07, 95% CI -0.12, 0.26, p = 0.43), with Used Material (CC = 0.11, 95% CI -0.28, 0.06, p = 0.21), with Sinus Volume (CC = 0.11, 95% CI -0.60, 0.28, p = 0.1), with Length (CC = 0.14, 95% CI -0.03, 0.31, p = 0.11), and Implant Diameter (CC = 0.13, 95% CI -0.05, 0.28, p = 0.15). Subsequently, a strong negative and statistically significant correlation was observed between the Study Lot and Primary Stability (CC = -0.70, 95% CI -0.78, -0.61, p < 0.001).

Stability at 6 Months had a minor impact on the Study Lot, with a correlation coefficient of -0.24 (95% CI -0.40, -0.07, p = 0.006), yet statistically significant. A strong positive correlation was established between the Study Lot and Intra-Operative Room (IOR) (CC = 0.61, 95% CI 0.49, 0.41, p < 0.001).

Time from Extraction had a weak negative and statistically significant correlation with the Study Lot (CC = -0.32, 95% CI -0.48, -0.16,  $p < 0.001$ ). Patient Age correlated weakly, but statistically significantly with Stability at 6 Months (CC = 0.17, 95% CI 0.01, 0.32,  $p = 0.04$ ).

Sinus Volume (CC = 0.31, 95% CI 0.13, 0.46,  $p < 0.001$ ) and Time from Extraction (CC = 0.26, 95% CI 0.07, 0.43,  $p = 0.003$ ) both show statistically significant correlations. Primary Stability had a moderate, positive, and statistically significant correlation with Stability at 6 Months (CC = 0.53, 95% CI 0.38, 0.67,  $p < 0.001$ ). A strong, negative, and statistically significant correlation was observed between Primary Stability and Intra-Operative Room (IOR) measures with a coefficient (CC = -0.66, 95% CI -0.75, -0.54,  $p < 0.001$ ). Subsequently, a weak, positive, and statistically significant correlation was found between Primary Stability and Time from Extraction (CC = 0.25, 95% CI 0.07, 0.40,  $p = 0.004$ ). Stability at 6 Months shows a weak, negative, and statistically significant correlation with IOR (CC = -0.27, 95% CI -0.42, -0.11,  $p = 0.002$ ). The material used in the study correlated weakly, negatively, but significantly with IOR (CC = -0.30, 95% CI -0.45, -0.13,  $p = 0.001$ ). Additionally, a correlation as weak but positive and statistically significant was determined between the Material used during the study, Sinus Volume (CC = 0.32, 95% CI 0.16, 0.47,  $p < 0.001$ ), and Time from Extraction (CC = 0.24, 95% CI 0.08, 0.39,  $p = 0.006$ ).

The Height of Residual Bone showed a weak, negative, and statistically significant correlation with Time from Extraction (CC = -0.44, 95% CI -0.56, -0.28,  $p < 0.001$ ) and a weak, positive correlation with Implant Diameter (CC = 0.22, 95% CI 0.05, 0.37,  $p = 0.01$ ). Sinus Volume was weakly, positively, and significantly correlated with Implant Diameter (CC = 0.28, 95% CI 0.12, 0.43,  $p = 0.001$ ). A very weak but statistically significant correlational influence was observed between Time from Extraction and Implant Diameter (CC = -0.17, 95% CI -0.01, -0.61,  $p = 0.05$ ).

#### **4.2. Analysis of the Results of Implant-Prosthetic Rehabilitation**

Implant-prosthetic rehabilitation in the posterior sectors of the maxilla involving the maxillary sinus presents numerous challenges for both clinicians and patients. These challenges, which are often overlooked, can significantly impact the quality of life for patients, causing discomfort and prolonged rehabilitation periods. According to the classic rehabilitation options for patients involving the sinus, proposed by Misch and Judy in 1998 [33] in severe atrophies (SA4, under 5 mm of residual subantral bone), bone augmentation is performed with delayed insertion of dental implants, after a period of 6-8 months.

The integration period for these implants also requires time. However, the proposed solutions to reduce rehabilitation timelines and interventions offer a glimmer of hope. These solutions aim to make the process more efficient, which is increasingly less acceptable to patients. On the other hand, the increased number of interventions (augmentation, implant insertion, implant exposure) intensifies pain syndrome, increases the risks of failure in each intervention, and accordingly increases morbidity, as noted by other researchers [24].

Considering the cases within the study lot where vertical bone addition was also performed in addition to elevating the sinus floor, the number of interventions and rehabilitation timelines were further reduced from 3-4 interventions to 1-2 interventions. These findings offer valuable insights into potential strategies for reducing patient discomfort and improving rehabilitation efficiency.

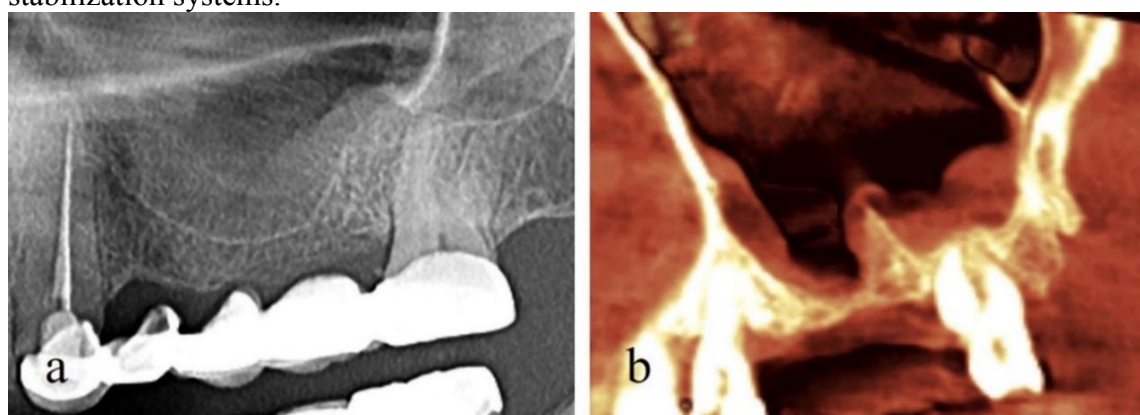
From the initial interventions of maxillary sinus floor elevation (performed from the palatal aspect) to the present day, numerous access techniques to the sinus (such as lateral window technique, crestal approach, and transcristal approach), biomaterials used (such as

autogenous bone, allografts, xenografts, and synthetic materials), and implants (such as standard implants, short implants, and zygomatic implants) that can facilitate rehabilitation in shorter terms have been proposed.

According to the study data, the post-extraction periods play a crucial role in the early rehabilitation of patients with such pathologies. According to the obtained data, the degree of maxillary sinus pneumatization and alveolar ridge atrophies increases with time elapsed after dental extraction (according to the Mann-Whitney U test = 1142.0,  $p < 0.001$ ). For this reason, in the study group, the post-extraction periods are much more extended than in the control group. This phenomenon is due to several factors. The first relates to the tendency of the maxillary sinus to pneumatize over time and the second to post-extraction alveolar ridge atrophy. From the evaluation of the tomographies of patients included in the study, a high degree of pneumatization was observed in the edentulous areas and the maintenance of the level of the maxillary sinus floor in areas where teeth are present (Fig. 35a), as also noted by other authors [4, 25]. Therefore, this allows the conclusion that maxillary sinus pneumatization is accelerated in edentulous sectors.

This can be due to the absence of transmission of masticatory forces to the bone tissue, a force that could counteract the pneumatization process. This phenomenon can also lead to the f. 35b).

Given these peculiarities, the study group of the conducted research corresponds to extreme cases where the degree of pneumatization of the maxillary sinus does not allow for the concurrent insertion of implants with the sinus lifting procedure without using special stabilization systems.



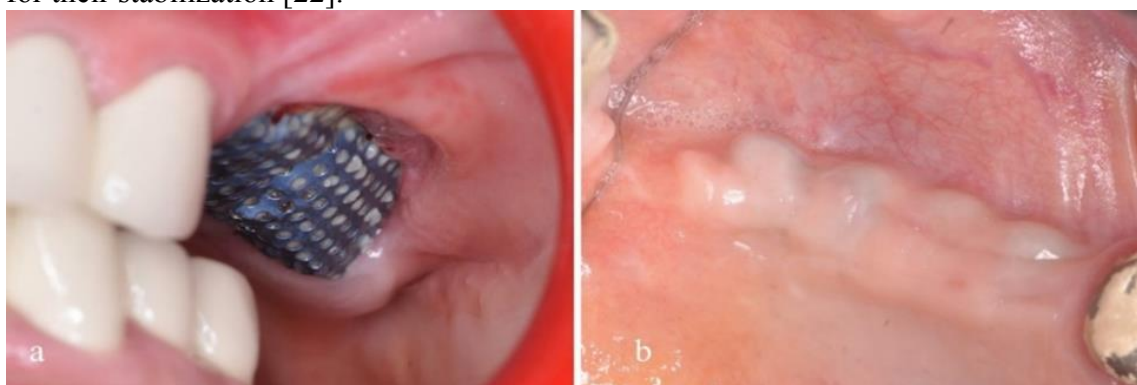**Figure 35 Maxillary sinus pneumatization in the edentulous sector (a), presence of secondary septa (b)**

In determining the access routes to the maxillary sinus, according to the study data, in most cases, access was made without preserving the bony cortex (window scraping technique). In the case of the window reversal technique (conventional antrostomy), the cortical bone remains attached to the Schneiderian membrane and can serve as a new floor for the maxillary sinus while also presenting osteogenic potential.

Despite these advantages, such techniques require creating larger surface windows to avoid perforating the sinus mucosa, and the time required to perform this is longer compared to the scraping technique. Thus, in this research, the window scraping technique predominated in both groups (Pearson Chi-square – 2.12,  $p = 0.34$ ), which facilitated access to the sinus membrane and also allowed for obtaining much smaller access windows compared to the conventional technique.

Following the evaluation of implant-prosthetic rehabilitation techniques, it was observed that implants can successfully integrate even in the absence of their stability, if they are fixed by implants that have sufficient stability. The use of fixation devices based on titanium mini-plates requires practical skills and additional experience. Moreover, based

on the number of failure cases using mini-plates (6 implants out of 50 evaluated), we can affirm that the survival rate of implants at the end of the integration period is 88%, which is comparable with data from the literature for implants inserted under conditions sufficient for their stabilization [22].



**Figure 36. Exposure of the titanium mesh (a) and contouring of the miniplate shape under the mucosa (b)**

Another aspect concerning the risks associated with using special systems such as mini-plates and titanium meshes is the occurrence of dehiscences. The failure in this case is indicated by the appearance of dehiscence in the immediate postoperative period until a stable osteoid substrate is formed underneath (the first 12 weeks). In the study group, dehiscences were observed in vertical bone additions using titanium meshes (Figure 36a) and in 2 cases with minor exposure of the miniplate. If these occurred towards the end of the integration period, the exposure of the mesh or miniplate did not jeopardize the integration of the implants, and the treatment could be completed. In the case of mini-plates that fixed unstable implants, 2 such cases were recorded, and thinning of the mucosa and contouring of the shapes of the underlying mini-plates were observed (Figure 36b).

Despite the meticulous attention given to the implant installation process and the individualized treatment provided to patients, complications were still recorded intra- and postoperatively. These included perforation of the maxillary sinus membrane, dehiscence of the postoperative wound in the study group, migration of the implant into the maxillary sinus, failure of the implants' integration associated with the exposure of the titanium mesh and exposure of the titanium mini-plate. These challenges underscore the complexity of the procedure and the need for careful consideration of the risks involved.

The post-extraction periods depend on two main factors: the degree of maxillary sinus pneumatization and the alveolar ridge's post-extraction atrophy. However, implant insertion using stabilization devices offers a significant advantage—a substantial reduction in the number of surgical interventions and the timelines for patient rehabilitation. Grafting based on collagen with hydroxyapatite is much more advantageous than using bone sawdust in sponge form. The use of xenografts + autologous bone, in that the use of collagen membranes does not require protection of the sinus mucosa, and at the end of the healing period, the radiologic appearance of the newly formed bone has a structure similar to that of native bone. In contrast, the use of xenograft shows increased radiopacity compared to the structure of native bone.

The main disadvantage of the collagen-based graft lies in the material's physical properties, which, being soft, increases the risk of pneumatization of the maxillary sinus. However, our study has shown that successful integration of the implants can occur even in the absence of their stability by fixing them to implants with sufficient strength. The use of fixation devices based on titanium mini-plates resulted in an implant survival rate of 88% at the end of the integration period, providing reassurance about the potential for successful outcomes.



## 5. GENERAL CONCLUSIONS

1. From the analysis of the data obtained, it was observed that patients who had the most extended post-extraction periods showed the slightest offer of residual subantral bone (enrolled in the study group), with a statistically significant difference compared to those in the control group, whose periods after tooth extraction were shorter, and the bone offer was greater (Mann-Whitney U test = 1142.0,  $p < 0.001$ ). According to the study data, the process of maxillary sinus pneumatization in the post-extraction period is continuous and can lead to total loss of alveolar crest height.
2. The techniques we propose allow for the simultaneous insertion of implants with the elevation of the maxillary sinus floor, even in compromised residual subantral bone as little as 1-4 mm. In cases of 3-4 mm bone offers, if an insertion force of the implants (at least 10-15Ncm) sufficient to maintain them during the healing period is achieved, implantation is performed without implant stabilization systems.
3. From the evaluation of the results in the study group, it was demonstrated that implant stabilization systems through titanium mini-plates allow osseointegration of implants without their primary stability in the residual bone bed. The dynamics of implant stability demonstrated a statistically significant evolution towards negative values of periostometry in the study group (Wilcoxon  $W = 14.0$ ,  $n = 50$ ,  $p < 0.001$ ), similar to the dynamics of those in the control group. Also, evaluating stability and peri-implant bone indicates the need to avoid definitive functional loading at the end of the integration period and apply provisional prosthetic treatment to allow gradual bone remodelling. The analysis of the type of access to the maxillary sinus did not reflect an impact on the evolution of tissue regeneration in both the study and control groups ( $p > 0.05$ ).
4. The evaluation of the type of material used reflected a relatively uniform distribution of all types of graft used in both lots. No correlation was determined between the treatment evolution and the graft type used. The dynamics of bone volume reflected a statistically significant change by decreasing the initial volume created after intervention towards the end of the healing period (Friedman test,  $Q = 98.04$ ,  $p < 0.001$ , at all evaluation stages). This evolution was similar in both lots, indicating that the intrasinus regeneration process proceeds with a repneumatization phenomenon.

## PRACTICAL RECOMMENDATIONS

1. Initially, in planning implant-prosthetic rehabilitation, it is essential to perform a Cone Beam Computed Tomography (CBCT) scan to evaluate the condition of the maxillary sinus mucosa, the permeability of the ostiomeatal complex, the presence or absence of foreign bodies in the sinus, as well as periapical processes of remaining teeth that could cause reactions in the maxillary sinus.
2. It is recommended to install dental implants using the developed method for maxillary sinus floor elevation and stabilization. This reduces the duration and cost of implant-prosthetic treatment in individuals with edentulism in the atrophied posterior sectors of the maxilla
3. It is necessary to individually assess the appropriate timing for initiating the prosthetic phase by determining the biological stability of the dental implants.
4. Given their significant practical importance, the refinement of implant-prosthetic rehabilitation methods for patients with severe atrophies in the lateral areas of the superior jaw remains a current issue.
5. Displacement and migration of implants into the maxillary sinus is a rare but potentially severe complication, hence the necessity of understanding each practitioner's surgical experience limits.

## BIBLIOGRAPHY

1. ATAMNI, F., TOPALO, V. Alternative implantation methods to avoid sinus grafting. In: *Medicina stomatologică*. 2013, nr. 3, pp. 29-41. ISSN 1857-1328.
2. ATAMNI, F. Implantația dentară în sectoarele posterioare ale maxilei. *Teză de doctor habilitat în științe medicale*. Chișinău, 2017, p. 256.
3. ATAMNI, F. Complications in oral implantology associated with maxillary sinus lifting. In: *Curierul Medical*. 2013, 56(3), pp. 3-15. ISSN 1875-0666.
4. ALKAABI, S.A., ALSABRI, G.A., NATSIR KALLA, D.S., ALAVI, S.A., NURRAHMA, R., FOROUZANFAR, T., et al. Regenerative graft materials for maxillary sinus elevation in randomized clinical trials: A meta-analysis. In: *Advances in Oral and Maxillofacial Surgery*. 2022, vol. 8, p. 100350. ISSN 2667-1476.
5. AL-ALMAIE, S., KAVARODI, A.M., ALORF, A., ALZHRANI, S.A. Split-mouth design comparison for lateral and crestal sinus lift techniques with dental implants placements: Short communication. In: *Open Dent J*. [online] 2017, 30(11), pp. 603-608. DOI: 10.2174/1874210601711010603. [citată 11.010.2020]. Disponibil: <https://www.ncbi.nlm.nih.gov/pmc/articles/PMC5738746/pdf/TODENTJ-11-603.pdf>.
6. BECKER, W., DAHLIN, C., LEKHOLM, U., BERGSTROM, C., VAN STEENBERGHE, D., HIGUCHI, K., et al. Five-year evaluation of implants placed at extraction and with dehiscences and fenestration defects augmented with ePTFE membranes: results from a prospective multicenter study. In: *Clin Implant Dent Relat Res*. 1999, 1(1), pp. 27-32. DOI: 10.1111/j.1708-8208.1999.tb00088.x.
7. CHELE N. Factorii determinanți ai osteointegrării în implantologie. In: *Medicina stomatologică*. 2015, nr. 3(36), pp. 29-32. ISSN 1857-1328.
8. CHELE, N. Implantarea imediată: Riscuri și beneficii. Studiu preliminar. In: *Medicina stomatologică*. 2014, nr. 3(32), pp. 56-64. ISSN 1857-1328.
9. CHELE, N., **DABIJA, I.**, MOSTOVEI, M., CHELE, D., MOSTOVEI, A. Reabilitarea implanto -protetică în atrofii severe ale maxilarelor. In: *Medicina stomatologică*. 2020, nr. 3(56), pp. 92-96. ISSN 1857-1328.
10. CHELE, N., ONEA, E., TOPALO, V. Argumentarea morfologică a instalării timpurii a implantelor dentare endoosoase. In: *Medicina stomatologică*. 2012, nr. 2(23), pp. 46-51. ISSN 1857-1328.
11. CHELE, N., TOPALO, V., SÎRBU, D. Instalarea imediată ghidată a implantelor dentare de stadiul doi. In: *Medicina stomatologică*. 2015, nr. 2(35), pp. 33-38. ISSN 1857-1328.
12. CHELE, N., ZĂNOAGĂ, O., MOSTOVEI, A., **DABIJA, I.**, MOTELICA, G., CUCEREAVÎI, N. Crearea ofertei osoase în zona laterală a maxilarului superior cu inserția imediată a implantelor dentare endoosoase. In: *Medicina stomatologică*. 2015, nr. 3(36), pp. 32-35. ISSN 1857-1328.
13. CORREIA, F., GOUVEIA, S.A., POZZA, D.H., FELINO, A.C., FARIA-ALMEIDA, R. A randomized clinical trial comparing implants placed in two different biomaterials used for maxillary sinus augmentation. In: *Materials (Basel)*. [online]. 2023, 16(3), p. 1220. DOI: 10.3390/ma16031220. [citată 07.02.2022]. Disponibil: <https://www.mdpi.com/1996-1944/16/3/1220>.
14. **DABIJA, I.** Endo-sinus bone gain in lateral sinus floor elevation with simultaneous implant placement without grafting material. The 7<sup>th</sup> International Medical Congress for Students and Young Doctors. In: *Abstract Book*. Chisinau, 2018, p. 244. ISBN 978-9975-47-174-9.
15. **DABIJA, I.**, CHELE, N., TOPALO, V., MOSTOVEI, A. et al. Endo-sinus bone gain in case of lateral sinus floor elevation with immediate implant placement without grafting material. In: *Clin. Oral Impl*. 2016, 27 (13), p.230.
16. DOBROVOLSCHI, O. Aspecte de chirurgie menajantă în implantologia orală. *Teză de doctor în științe medicale*. Chișinău, 2010, p. 34-39.

17. FARIAS, I.O.B., BAHIA, R.R.C., BARRETO, M.A., PINTO, F.S., FERNANDES, A.C.S. Lateral window maxillary sinus lift surgery: case report. In: *RGO, Rev Gaúch Odontol.* [online]. 2022, p. 70:e20220031. [accesat 14.04.2023]. Disponibil: <http://dx.doi.org/10.1590/1981-86372022003120210042>.
18. FERMERGARD, R., ASTRAND, P. Osteotome sinus floor elevation and simultaneous placement of implants—a 1-year retrospective study with Astra Tech Implants. In: *Clin Implant Dent Relat Res.* 2008, vol. 10, p. 62-69.
19. FERREIRA, P.W., NOGUEIRA, P.J., NOBRE, M.A.A., GUEDES, C.M., SALVADO, F. Impact of mechanical complications on success of dental implant treatments: A case-control study. In: *Eur J Dent.* 2022, 16(1), pp. 179-187. DOI: 10.1055/s-0041-1732802.
20. GHEȚIU, A., SÎRBU, D., JURJIU, V. Evaluarea defectelor osoase ale crestei alveolare la maxilarul superior. In: *MJHS.* 2020, 25(4), pp. 35-50. ISSN 2345-1467.
21. GHEȚIU, A., SÎRBU, D., CHELE, N., BRAN, S., JURJIU, V., NOSACI, A. Crearea ofertei osoase a maxilarului superior cu atrofie avansata in reabilitarea implanto-protetica prin greafa osoasa autogena din creasta iliaca. In: *Medicina stomatologică.* 2019, nr. 4(53), pp. 9-18. ISSN 1857-1328.
22. JAMCOSKI, V.H., FAOT, F., MARCELLO-MACHADO, R.M., MOREIRA MELO, A.C., GASPARINI KIATAKE FONTÃO, F.N. 15-year retrospective study on the success rate of maxillary sinus augmentation and implants: influence of bone substitute type, presurgical bone height, and membrane perforation during sinus lift. In: *BioMed Research International.* [online]. 2023, vol. 2023, Article ID 9144661, 13 p. [accesat 03.01.2024]. Disponibil: <https://doi.org/10.1155/2023/9144661>.
23. JOHANSSON, L.A., ISAKSSON, S., ADOLFSSON, E., LINDH, C., SENNERBY, L. Bone regeneration using a hollow hydroxyapatite space - maintaining device for maxillary sinus floor augmentation - A clinical pilot study. In: *Clin Implant Dent Relat Res.* 2012, vol. 23, p. 28-34.
24. LIAW, K., DELFINI, R.H., ABRAHAMS, J.J. Dental implant complications. In: *Semin Ultrasound CT MR.* 2015, 36(5), pp. 427-433. DOI: 10.1053/j.sult.2015.09.007.
25. LYU, M., XU, D., ZHANG, X., YUAN, Q. Maxillary sinus floor augmentation: a review of current evidence on anatomical factors and a decision tree. In: *Int J Oral Sci.* 2023, 15(1), p. 41. DOI: 10.1038/s41368-023-00248-x.
26. LIN, Z.Z., XU, D.Q., WANG, Y., GAO, X., CAI, Q., DING, X. Factors impacting new bone formation in transcrestal sinus floor elevation followed by implant placement: a cross-sectional study. In: *BMC Oral Health.* 2022, 22(1):319. DOI: 10.1186/s12903-022-02352-6.
27. LOMBARDI, T., LAMAZZA, L., BERNARDELLO, F., ZIĘTEK, G., STACCHI, C., TROIANO, G. Clinical and radiographic outcomes following transcrestal maxillary sinus floor elevation with injectable xenogenous bone substitute in gel form: a prospective multicenter study. In: *Int J Implant Dent.* 2022 Jul 22;8(1):32. DOI: 10.1186/s40729-022-00431-5.
28. MOSTOVEI, A. Evaluarea integrării implantelor dentare endoosoase de stadiul doi instalate într-o ședință prin chirurgia fără lambou. *Teză de doctor în științe medicale.* Chișinău, 2014.
29. MOLINA, A., SANZ-SÁNCHEZ, I., SANZ-MARTÍN, I., ORTIZ-VIGÓN, A., SANZ, M. Complications in sinus lifting procedures: Classification and management. In: *Periodontol 2000.* 2022, 88(1), pp. 103-115. DOI: 10.1111/prd.12414.
30. MOSTOVEI, A. Instalarea implanturilor dentare într-un timp chirurgical cu elevarea planșeului sinusului maxilar prin acces lateral. In: *Medicina stomatologică.* 2019, nr. 4(53), pp. 53-61. ISSN 1857-1328.
31. MENCHINI-FABRIS, G.B., TOTI, P., CRESPI, G., COVANI, U., CRESPI, R. Distal displacement of maxillary sinus anterior wall versus conventional sinus lift with lateral



- access: A 3-year retrospective computerized tomography study. In: *Int J Environ Res Public Health*. 2020, 17(19):7199. DOI: 10.3390/ijerph17197199.
32. MANEV, G.S., POPOVA, C. Sinus floor augmentation with bone block grafting and simultaneous implant placement. In: *Journal of IMAB - Annual Proceeding (Scientific Papers)*. 2013, vol. 19, issue 4, p. 348-354.
  33. MISCH, C.E. *Contemporary implant dentistry*. 3-rd edition. Publisher Mosby, 2007. 1102 p. ISBN-13 978-0323043731.
  34. MISCH, C.E., JUDY, K.W. Classification of partially edentulous arches for implant dentistry. In: *Int J Oral Implantol*. 1987; 4(2), pp. 7-13.
  35. NAFFIZUDDIN, M., KRISHNA, B., LOKANATHAN BALAJI, D., RAM SUNIL, C.H., SUJANA, V., MADHU KIRAN NAIK, K. Maxillary Alveolar Bone Dimensional Changes of Post -Extraction Sockets in Humans. In: *J Ora Med*. 2021, Vol.5 No. 4:126.
  36. NKENKE, E., EITNER, S., RADESPIEL-TRÖGER, M., VAIRAKTARIS, E., NEUKAM, F.W., FENNER, M. Patient-centred outcomes comparing transmucosal implant placement with an open approach in the maxilla: a prospective, non-randomized pilot study. In: *Clin Oral Implants Res*. 2007, vol.18, no.2, pp. 197-203.
  37. NAFFIZUDDIN, M., KRISHNA, B., LOKANATHAN BALAJI, D., RAM SUNIL, C.H., SUJANA, V., MADHU KIRAN NAIK, K. Maxillary Alveolar Bone Dimensional Changes of Post -Extraction Sockets in Humans. In: *J Ora Med*. 2021, Vol.5 No. 4:126.
  38. ONIȘOR-GLIGOR, F., JUNCAR, M., BĂCIUȚ, G., BRAN, S., JUNCAR, R.I., DUMITRAȘCU, D.I., et al. Subantral Augmentation with a 1/1 Alloplastic and Autologous Material Mixture. Histological Characteristics and Dimensional Stability of the Newly Formed Bone. In: *Clujul Med*. 2015, 88(1), pp. 69-72. DOI: 10.15386/cjmed-400.
  39. PAGNI, G., PELLEGRINI, G., GIANNOBILE, W.V., RASPERINI, G. Postextraction alveolar ridge preservation: biological basis and treatments. In: *INT J DENT*. 2012, p. 2012:151030. DOI: 10.1155/2012/151030.
  40. PANDIT, A., CHOPRA, S. Maxillary sinus floor elevation: review of anatomy and lateral sinus lift technique. In: *Journal of Dental and Medical Sciences (IOSR-JDMS)*, 2016, 15 (1), pp. 29-33. p-ISSN: 2279-0861. e-ISSN: 2279-0853. DOI: 10.9790/0853-15142933.
  41. PJETURSSON, B.E., TAN, W.C., ZWAHLEN, M., LANG, N.P. A systematic review of the success of sinus floor elevation and survival of implants inserted in combination with sinus floor elevation. In: *J Clin Periodontol*. 2008, 35(8 Suppl), pp. 216-240. DOI: 10.1111/j.1600-051X.2008.01272.x. PMID: 18724852.
  42. PERELLI, M., ABUNDO, R., CORRENTE, G., SACCONI, C., ARDUINO, P.G. Sinus floor elevation with modified crestal approach and single loaded short implants: a case report with 4 years of follow-up. In: *Case Rep Dent*. 2017; 2017:7829179. DOI: 10.1155/2017/7829179.
  43. PAVLICOVA, G., FOLTAN, R. ET AL. Piezosurgery in oral and maxillofacial surgery. In: *International Journal of Oral and Maxillofacial Surgery*. 2011, vol. 40, p. 451-457.
  44. RAWAT, A., THUKRAL, H., JOSE, A. Indirect sinus floor elevation technique with simultaneous implant placement without using bone grafts. In: *Ann Maxillofac Surg*. 2019, 9(1), pp. 96-102. DOI: 10.4103/ams.ams\_11\_19.
  45. RAINA, A., GULEDGUD, M.V., PATIL, K. Infraorbital ethmoid (Haller's) cells: a panoramic radiographic study. In: *Dentomaxillofac Radiol*. 2012, 41(4), pp. 305-308. DOI: 10.1259/dmfr/22999207.
  46. RYSZ, M., BAKOŃ, L. Maxillary sinus anatomy variation and nasal cavity width: structural computed tomography imaging. In: *Folia Morphol (Warsz)*. 2009, 68(4), pp. 260-264.
  47. SPINATO, S., BERNARDELLO, F., GALINDO-MORENO, P., ZAFFE, D. Maxillary sinus augmentation by crestal access: a retrospective study on cavity size and outcome correlation. In: *Clin Oral Implants Res*. 2015, 26(12), pp. 1375-1382. DOI: 10.1111/clr.12477.

48. SÎRBU, D., ENI, S., STRÎȘCA, S., TOPALO, V. Implanturile zigomatice în reabilitarea pacienților edentați cu atrofie severă a maxilarului superior. In: *Arta Medica*. 2020, nr. 2(75), pp. 4-13. ISSN 1810-1852. DOI: 10.5281/zenodo.3979631.
49. SÎRBU, D., MIGHIC, A., GHEȚIU, A., STRÎȘCA, S., SOBEȚCHI, A., VOLOC, C., et al. Aspecte chirurgicale ale reabilitării implant-protetice utilizand implantele cu design-ul spirelor knifethread®, nanostructurate, cu calciu incorporat pe suprafață. In: *Medicina stomatologică*. 2018, nr. 1(46), pp. 32-44. ISSN 1857-1328.
50. SONTHEIMER, M. One - stage sinus lifting using implant stabilizers - A report on everyday practice. In: *Dent Implantology*. 2000, vol. 4, p. 294-303.
51. TOPALO, V., ATAMNI, F., CHELE, N., SÎRBU, D., MOSTOVEI, A., ZĂNOAGĂ, O. Evaluarea la distanță de 3 ani a osului periimplantar la instalarea implantelor dentare prin metodă miniinvazivă de elevație transcresală a planșeului sinusului maxilar/Peri-implant bone evaluation 3 years after implant placement by minimally invasive method of transcrestal maxillary sinus floor elevation. In: *Revista de Științe ale Sănătății din Moldova*. 2016, nr. 4(10), pp. 17-39. ISSN 2345-1467.
52. TOPALO, V., MOSTOVEI, A., CHELE, N., SÎRBU, D., SUHARSCHI, I., ATAMNI, F., et al. Metodă de evaluare a remanierilor osoase periimplantare. In: *Medicina stomatologică*. 2015, nr. 1(34), pp. 43-46. ISSN 1857-1328.
53. WHYTE, A., BOEDDINGHAUS, R. The maxillary sinus: physiology, development and imaging anatomy. In: *Dentomaxillofac Radiol*. 2019, 48(8):20190205. DOI: 10.1259/dmfr.20190205.
54. YOO, S.Y., KIM, H.J., KIM, S.K., HEO, S.J., KOAK, J.Y., PARK, J.M. Quality of life in patients in South Korea requiring special care after fixed implants: a retrospective analysis. In: *BMC Oral Health*. [online]. 2023, 23(1):1002. DOI: 10.1186/s12903-023-03753-x. [citat 09.01.2024]. Disponibil: <https://bmcoralhealth.biomedcentral.com/articles/10.1186/s12903-023-03753-x>.

## INFORMATION REGARDING THE VALORIZATION OF RESEARCH RESULTS

- **Articles in accredited national scientific journals:**

- ✓ **articles in category B journals**

1. ZĂNOAGĂ, O., CHELE, N., MOSTOVEI, A., **DABIJA, I.** Tratatamentul pacienților cu chisturi odontogene ale maxilarelor. Chistectomia versus chistotomia. În: *Medicina Stomatologică*. 2017, nr. 1-2(42-43), pp. 29-31. ISSN 1857-1328.
2. MIGHIC, A., SÎRBU, D., MOSTOVEI, A., **DABIJA, I.** Lateral sinus floor elevation with simultaneous mucosal cysts management. În: *Moldavian Journal of Health Sciences*. 2023, 10(2), pp. 32-39. ISSN 2345-1467.

- ✓ **articoles in category C journals**

3. CHELE, D., CHELE, N., MOTELICA, G., MOSTOVEI, A., **DABIJA, I.**, ZUGRAV, V., BELINIUC, S. Inserarea timpurie tip 2, fără lambou a implanturilor dentare într-un timp chirurgical. Evaluarea la distanță de 5 ani. În: *Medicina Stomatologică*. 2023, 2(63), pp. 11-24. ISSN 1857-1328.
4. CHELE, D., MOTELICA, G., CHELE, N., **DABIJA, I.**, SOCOLAN, D., BADEA, F., MOSTOVEI, A. Rolul fenotipului gingival în remanierele osoase peri-implantare timpurii. În: *Medicina Stomatologică*. 2023, 2(63), pp. 188-173. ISSN 1857-1328.
5. **DABIJA, I.**, MOSTOVEI, A., CHELE, D., MOTELICA, G., ZUGRAV, V., CIOBANU, V., GORAȘ, A., CHELE, N. Evaluarea intergrării implanturilor dentare în urma intervențiilor de sinus lifting cu perforarea membranei sinusale. În: *Medicina Stomatologică*. 2023, 2(63), pp. 158-167. ISSN 1857-1328.
6. VETRILA, C., CHELE, D., DANDARA, M., CEBOTARI, M., MOTELICA, G., **DABIJA, I.**, LEHTMAN, S., MOSTOVEI, A., CHELE, N. Particularitățile adenomului pleomorf de glandă parotidă. Date statistice pentru perioada 2017-2022. În: *Medicina Stomatologică*. 2023, 2(63), pp. 174-182. ISSN 1857-1328.
7. ZUGRAV, V., CHELE, D., MOTELICA, G., MOSTOVEI, A., **DABIJA, I.**, CHELE, N. Membrana biopolimerică – un nou concept în regenerarea osoasă ghidată. Serie de cazuri. În: *Medicina Stomatologică*. 2023, 1(62), pp. 76-81. ISSN 1857-1328.
8. **Dabija, I.** Utilizarea sistemelor speciale de fixare a implantelor dentare în zona laterală a maxilarului superior cu atrofii severe. În: *Medicina stomatologică*. 2023, 3(64), pp. 20-27, ISSN 1857-1328

- **Articles in international scientific collections:**

9. DOBRESCU, M.L., CARAIANE, A., RAFTU, GH., Chele, N., **Dabija, I.**, Chele, D., and al. Alpha tumor necrosis – As predictive factor in dental implant management. In: *Romanian Journal of Oral Rehabilitation*. 2022, nr. 3, vol. 14, p. 91-95. ISSN 2066-7000, ISSN-L 2601-4661. (IF 0.645). Disponibil:  [aici https://rjor.ro/alpha-tumor-necrosis-as-predictive-factor-in-dental-implant-management/](https://rjor.ro/alpha-tumor-necrosis-as-predictive-factor-in-dental-implant-management/).
10. DOBRESCU, M.L., CARAIANE, A., RAFTU, GH., Chele, N., **Dabija, I.**, and al. *Pathogenic bacterial species – As causal relationship and risk factor in peri-implantitis progression*. In: *International Journal of Medical Dentistry*, 2022, nr. 3, vol. 26, pp. 494-498. ISSN 2066-6063. Disponibil  [aici https://ijmd.ro/2022/pathogenic-bacterial-species-as-causal-relationship-and-risk-factor-in-peri-implantitis-progression/](https://ijmd.ro/2022/pathogenic-bacterial-species-as-causal-relationship-and-risk-factor-in-peri-implantitis-progression/).

- **Abstracts/theses submitted at national or international scientific conferences**

11. CHELE, N.; TOPALO, V.; MOSTOVEI, A.; CUCU, G.; **DABIJA, I.**; SIRBU, D. Immediate implant placement after teeth extraction and cystectomy: Preliminary results. In: *The 25th Annual Congress of European Association for Osseointegration, Clinical Oral Implants Research*. 28 September – 01 October, Paris, France. 2016, 27 (Suppl. 13), p. 526. ISSN 0905-7161.

12. **DABIJA, I.**; CHELE, N.; TOPALO, V.; MOSTOVEI, A.; ATAMNI, F. Endo-sinus bone gain in case of lateral sinus floor elevation with immediate implant placement without grafting material. In: *The 25th Annual Congress of European Association for Osseointegration, Clinical Oral Implants Research*. 28 September – 01 October, Paris, France. 2016, 27 (Suppl. 13), p. 230. ISSN 0905-7161.
  13. **DABIJA, I.**; Endo-sinus bone gain in lateral sinus floor elevation with simultaneous implant placement without grafting material In: *Abstract book The 7th International Medical Congress for Students and Young Doctors MedEspera*, 3-5 May Chisinau, 2018, p. 244. ISBN 978- 9975-3028-4-5.
  14. MOSTOVEI, A.; TOPALO, V.; CHELE, N.; **DABIJA, I.**; ZĂNOAGĂ, O.; MOTELICA, G. Lateral sinus floor elevation and simultaneous implants placement in one surgical step. In: *The 27<sup>th</sup> Annual Congress of European Association for Osseointegration, Clinical Oral Implants Research*. 11-13 October, Vienna, Austria. 2018, vol. 29, 17 (suppl.), p. 457. ISSN 0905-7161.
  15. CHELE, N.; TOPALO, V.; MOSTOVEI, A.; ZANOAGĂ, O.; SÎRBU, D.; **DABIJA, I.** Immediate one- step flapless placement of two- piece dental implants with and without grafting. In: *The 26th Annual Congress of European Association for Osseointegration, Clinical Oral Implants Research*. 5-7 October, Madrid, Spain., 2017, vol. 28 (Suppl S14), p. 449. ISSN 0905-7161.
  16. CUCU, GH.; SIRBU, D.; CHELE, N.; TOPALO, V.; GHETIU, A.; MIGHIC, A.; **DABIJA, I.**; STRISCA, S. Implant retained prosthodontic rehabilitation in patients with extensive cystic lesions in the upper and lower jaws. . In: *The 27th Annual Congress of European Association for Osseointegration, Clinical Oral Implants Research*. 11-13 October, Vienna, Austria.. 2018, vol. 29, 17 (suppl.), p. 462. ISSN 0905-7161.
  17. GHETIU, A.; SIRBU, D., TOPALO, V.; CHELE, N.; MIGHIC, A.; **DABIJA, I.**; STRISCA, S. The utilisation of biomaterial combination in the alveolar bone crest reconstruction. Case report. In: *The 27th Annual Congress of European Association for Osseointegration, Clinical Oral Implants Research*. 11-13 October, Vienna, Austria. 2018, vol. 29, 17 (suppl.), p. 445. ISSN 0905-7161.
  18. MOSTOVEI, A.; TOPALO, E.; TOPALO, V.; CHELE, N.; CIOBANU, S.; **DABIJA, I.** The influence of implants platforms contamination during insertion upon bone loss during healing period. In: *The 27th Annual Congress of European Association for Osseointegration Clinical Oral Implants Research.*, 11-13 October, Vienna, Austria. 2018, vol. 29, 17 (suppl.), p. 409. ISSN 0905-7161.
  19. MOSTOVEI, A.; TOPALO, V.; CHELE, N.; **DABIJA, I.**; ZĂNOAGĂ, O.; MOTELICA, G. Lateral sinus floor elevation and simultaneous implants placement in one surgical step. In: *The 27th Annual Congress of European Association for Osseointegration, Clinical Oral Implants Research*. 11-13 October, Vienna, Austria. 2018, vol. 29, 17 (suppl.), p. 457. ISSN 0905-7161.
  20. TOPALO, E.; TOPALO, V.; MOSTOVEI, A.; CHELE, N.; DABIJA, I. The incidence of fistula and early implants exposure around implants with antibiotic treated and nontreated platforms. In: *The 28th Annual Congress of European Association for Osseointegration, Clinical Oral Implant Research*, 26-28 September, Lisbon, Portugal. 2019, vol 30, S 19 (issue), p. 331. ISSN 0905-7161.
- **Invention patents, patents, registration certificates, materials at invention salons**
    21. CHELE, N.; TOPALO, V.; **DABIJA, I.**; CHELE, D. *Metodă de a augmentare ghidată pe verticală în atrofii severe cu instalarea simultană a implanturilor dentare endoosoase*. Brevet de invenție Nr. 1445. 2019-12-17.

22. CHELE, N.; TOPALO, V.; **DABIJA, I.**; CHELE, D. *Metodă de instalare și stabilizare a implanturilor dentare endoosoase în atrofi severe în zonele laterale ale maxilei.* Brevet de invenție Nr. 1446. 2019-12-17.
23. **DABIJA I.**; CHELE N.; MOSTOVEI A.; ZĂNOAGĂ O.; CHELE D. *Metoda de utilizare a sistemelor speciale de fixare a implantelor dentare în zona laterală a maxilarului superior cuatrofii sever.* Certificat de inovator Nr.186. 2023-12-05.
24. **DABIJA I.**; CHELE N.; MOSTOVEI A.; ZĂNOAGĂ O.; CHELE D. *Metoda de suturare a membranei sinusale în urma perforării ei în intervenția de sinuslifting lateral.* Certificat de inovator Nr.187. 2023-12-05

- **Participation with communications at scientific forums:**

- ✓ **National**

25. **DABIJA,I.** Tehnici atipice de stabilizare a implantelor în sinus lifting lateral. Conferința științifico-practică națională cu participare internațională consacrată aniversării a 90 de ani de la nașterea ilustrului savant Nicolae Testemițanu. Chișinău, Republica Moldova, 29 septembrie, 2017.
26. **DABIJA, I.** Utilizarea sistemelor speciale de fixare a implantelor în sinus liftingul lateral. Conferința științifică anuală a Institutului de Medicină Urgentă a tinerilor specialiști „Actualități și controverse în managementul urgențelor medico-chirurgicale”. Chișinău, Republica Moldova, 10 noiembrie, 2017.
27. **DABIJA, I.** Tehnici atipice de stabilizare a implantelor în sinus lifting lateral. Conferință științifică cu participare internațională în memoria distinsului savant, profesor universitar Valentin Topalo. Chișinău, Republica Moldova, 28 aprilie 2023.