

contingentului de bolnavi cu utilizarea ne semnificativă a controlului voluntar al posturii. Aplicarea metodelor de biofeedback cu implicarea controlului voluntar poate crește eficiență în reeducarea tulburărilor posturale la acești pacienți. Astfel, aplicarea testului cu sarcini cognitive în cadrul stabilografiei computerizate poate fi propusă drept o metodă informativă și simplă în utilizare pentru evidențiere particularităților controlului voluntar al posturii la pacienții cu hemipareză post AVC.

Bibliografie

1. Dubost V, Kressig RW, Gonthier R, et al. Relationship between dual-task related changes in stride velocity and stride time variability in healthy older adults, *Hum May Sci* 2006;25:372-82.
2. Ehrenfried T, Guerraz M, Thilo KV, Yardley L, Gresty MA. Posture and mental task performance when viewing a moving visual field. *Brain Res Cogn Brain Res.* 2003 Jun;17(1):140-53.
3. Horak, FB, Macpherson, JM. Postural orientation and equilibrium. In: Rowell, LB, Shepherd, JT eds., *Handbook of physiology, Sec 12, Exercise: regulation and integration of multiple systems*, Oxford University Press, New York, 1996; pp 255-292.
4. Jacobs JV, Horak FB. Cortical control of postural responses. *J Neural Transm* 2007;114: 1339–1348.
5. Horak F. Assumption underlying motor control for neurologic rehabilitation. In.: *Contemporary management of motor control problems. Proceeding of the II Step Conference.* Alexandria, VA: APTA, 1991: 11-27.
6. Maki BE, McIlroy WE. Cognitive demands and cortical control of human balance-recovery reactions. *J Neural Transm.* 2007; 114(10):1279-96.

CLINICAL AND NEUROPHYSIOLOGIC FEATURES OF SPINAL CORD MENINGIOMAS

M.Gavriliuc, V.Lisnic, Nina Istrati, Liubovi Munteanu

Department of Neurology, State Medical and Pharmaceutical University “N. Testemitanu”
Institute of Neurology and Neurosurgery

Summary

We present the longitudinal clinical and electrophysiological study of 27 patients with spinal meningioma. All cases were confirmed by MRI and histological examinations. Electrophysiological examination included needle electromyography of muscles: *paravertebralis, vastus lateralis, biceps femoris, tibialis anterior* and *gastrocnemius medialis*. Clinical and electrophysiological findings were assessed in each case together with the level of spinal lesion.

Electrophysiological abnormalities were founded in 100% of cases. Based on statistical analysis of the results, electrodiagnostic criteria were elaborated for the discrimination of each clinical syndrome of spinal meningioma. In addition to this data were founded that compressive damage of spinal cord tissue causes the morphofunctional reorganization of motor units and segmentar neuro-muscular apparatus. Moreover, as a result of neuronal plasticity at this level of nervous system news programs of motor function are established.

The general conclusion of this study is that multimodal electrophysiological investigation as a consciously extension of clinical examination is very important in the positive and differential diagnosis of spinal meningioma. An electrophysiological examination is also useful for the prognosis of tumoral spinal cord process and for the control of neurosurgical treatment efficacy.

Rezumat

Simptomele clinice și neurofiziologice ale meningiomului spinal

Studiul clinic și electrifiziologic s-a bazat pe investigație a 27 de pacienți cu meningiom spinal. Toate cazurile au fost confirmate prin RMN și examenul histologic. Examenul electrofiziologic a constatat din EMG cu ac-electrod al mușchilor: *paravertebralis*, *vastus lateralis*, *biceps femoris*, *tibialis anterior* and *gastrocnemius medialis*. Rezultatele examenului electrofiziologic și clinic în fiecare caz au fost corelate cu nivelul de leziune spinală.

Dereglările electrofiziologice au fost detectate în 100% de cazuri. Basându-se pe analiza statistică, criteriile electrofiziologice au fost elaborate pentru a determina fiecare sindrom al meningiomului spinal. Adăugător acestor rezultate au fost stabilite: dereglări compresive ale cordului spinal, reorganizarea morfofuncțională a unităților motorii și aparatului segmentar neuro-muscular. Ca rezultatul plasticității neuronale la acest nivel al sistemului nervos au fost stabilite programe noi de conductabilitate motorie.

Concluzia generală acestui studiu este că examinarea electrofiziologică multimodală în contuitatea examenului clinic neurologic este foarte importantă în diagnosticul pozitiv și diferențial al meningiomului spinal. Studiul electrofiziologic este foarte util și în prognozarea procesului tumoral spinal și pentru controlul eficacității tratamentului neurochirurgical.

Introduction

The annual incidence of primary spinal neoplasms ranges from 0.8 to 2.5 per 100,000 population (Fogelholm et al 1984). In hospital neurosurgical practice, intraspinal neoplasms generally account for approximately 15% of all primary tumors of the central nervous system. A large series of 1322 primary intraspinal tumors, reported from the Mayo Clinic, recorded an incidence of 29% schwannomas, 25.5% meningiomas, 22% gliomas, and almost 12% sarcomas (Slooff et al 1964). Meningiomas in the spinal canal are far less frequent than those within the cranial cavity (Elsberg 1925; Slooff et al 1964; Russell and Rubinstein 1989).

The majority of spinal meningiomas present in the older population, with a peak in the sixth decade. Meningiomas are rare in children and young adults. In this age group there is an increase of malignant variants when compared to adults and a higher association with neurofibromatosis (Deen et al 1982; Nakamura and Becker 1985). Familial occurrence of meningiomas, usually multiple, is found largely in the context of von Recklinghausen disease (Delleman et al 1978).

Spinal meningiomas have a female preponderance of up to 90% (Nittner 1976; Solerno et al 1989; Roux et al 1996; King et al 1998).

The high diagnostic-prognostic value reached by the clinical neurophysiology investigations has contributed to bring the clinical neurophysiologist in the forefront. Patterns of referral for clinical neurophysiology investigation have changed greatly over the past ten years, the most interesting datum being a steady rise in the number of electromyography (EMG) requests. At the present time, most clinical neurophysiology studies in spinal meningioma are faced with operational deficits, evidencing significant discrepancies between EMG reimbursable costs and operating costs. The corrective strategies empirically adopted until now, have paradoxically produced effects opposite to those expected.

AIMS

There appears to be need to carry out a systematic, in-depth analysis of the clinical – imagistic – EMG analysis of spinal meningiomas, which will require the commitment collaboration of neurologist, neurosurgeon, neuroimagist and neurophysiologist.

The continuous increase in the demand for neurophysiological diagnostic testing and the consequent diagnostic flourishing of a not always qualitatively homogeneous supply in spinal meningioma, indicate the need for the following actions:

- to proceed to the development of clinical practice guidelines for the diagnosis of the spine cord compression, establishing the minimum qualitative criteria required;

- to construct a reference table with the time required to perform EMG diagnostic tests, keeping in mind the standards of quality.

Materials and methods

Twenty seven patients who met the diagnostic criteria for spinal meningioma were included in the study. All of the patients were evaluated in our hospital over a period of 5 years (2001-2006) according to a predefined protocol. At the time of diagnosis, all patients underwent: clinical evaluation, MRI examination and electrophysiologic examinations. In all 27 patients diagnosis was confirmed by morphological examination.

Clinical evaluation

Patient disability was assessed at baseline, after six and 12 months, and at the end of follow-up, according to a modified Rankin scale scores were: 0 = asymptomatic; 1 = nondisabling symptoms that do not interfere with lifestyle; 2 = minor symptoms that lead to some restriction in lifestyle, but do not interfere with patients' capacity to look after themselves; 3 = moderate symptoms or prevent totally independent existence; 4 = moderately severe symptoms that clearly prevent independent existence, although patient does not need constant attention; 5 = severely disabled, totally dependent, requiring attention.

Electrophysiologic examination

All patients had needle electromyographic examination of the *paravertebralis*, *vastus lateralis*, *biceps femoris*, *tibialis anterior* and *gastrocnemius medialis* muscles. Conduction studies were performed using standard techniques. Motor conduction of median, ulnar, peroneal and tibial nerves was assessed. For motor nerves, F response latencies, compound muscle action potential (CMAP) amplitudes and duration, conduction velocities, distal latencies, and the proximal/distal CMAP amplitude ratios were evaluated. Sensory nerve action potentials (SNAPs), and amplitude and conduction velocities (onset latencies) were recorded from the median or ulnar nerves and from the sural nerves. All twenty seven patients had repeat electrophysiologic examinations.

Results

Clinical features and disease and disease course are summarized in Table 1. Clinical disability was mild (Rankin ≤ 2) in 67% of patients, moderate (Rankin = 4) in 8%.

Fourteen patients had both motor and sensory involvement, twenty one had predominant motor deficit, while nine had mainly sensory symptoms. Lower limbs were predominantly involved in 15 cases, all limbs were resulted similarly affected in 22 cases, and upper limbs were mainly affected in 3 patients.

Table 1 Characteristics of the 27 spinal meningioma patients

Clinic syndrome	Level			Total
	<i>cervical</i>	<i>thoracic</i>	<i>thoracic –lumbar</i>	
Radicular	-	2	-	2
Hemisection of the cord (Brown / Séquard)	6	11	-	17
Complete transverse lesion	-	7	1	8

Electrophysiological evaluations of the patients with spinal meningiomas showed persistent and disperse spontaneous muscular activity like fibrillation potentials, fasciculations and sharp waves in the all examined muscles unrelated with medullar lesions (fig.1).

Fibrillation potentials and sharp waves in the next muscles: *paravertebralis*, *vastus lateralis*, *biceps femoris*, *tibialis anterior* and *gastrocnemius medialis*, didn't correlate with neurological manifestations, being registered in the paraparesis and paraplegia phases as well. Any relations between expression of spontaneous muscular activity, spasticity degree and severity of medullar lesion determined by MRI-exam were established.

In 12 patients EMG abnormalities had been solved in 8-11 weeks parallel with restoration of voluntary control of the affected muscles after performed surgical treatment. Statistical analysis revealed approach of the medium values of the fibrillation potentials amplitudes and sharp waves in the patients with ischemic medullar strokes, these values constituted 112 and 126 mV.

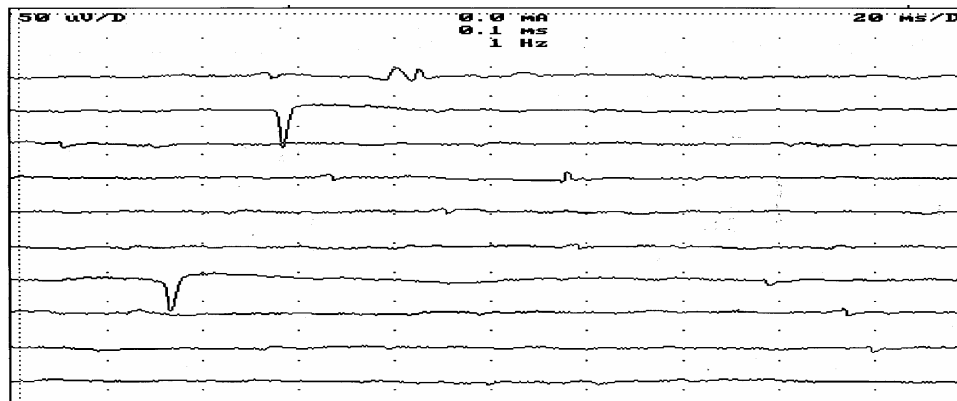


Fig. 1. EMG examination showing a denervation activity: positive sharp waves.

Motor units potentials (MUP) with abnormal duration values and amplitudes were noticed at least in too muscles of all the patients with spinal meningiomas. Finding of this deviation from normal values was performed by comparison of obtain results with MUP values in the group control. Comparative analysis of the basic components of the motor units in the patients with chronic vascular myelopathy showed direct connection between duration values and amplitudes, basic potentials amplitudes and summary amplitude of MPU ($r=0,95$, $P<0,001$). These results were compared with the evolution stage of the pathological process. Obtained results showed that next studies of the denervation-reinervation process configuration of the basic component remain the same, but variability of the duration and total surface of the MPU is determined by the unstable components and satellit-potentials. MPU with unstable components at the end of potential predominate in the early phase of the reinervation, which is the first week after neurosurgical treatment. By the time as reinervation process is extended in the interior of the muscle, unstable components are changed by satellit-potentials; in the advanced stages of the reinervation-denervation process, clinically expressed by subcompensated-decompensated phase, basic component of the MPU is constant associated with Jitter phenomenon (fig. 2). The scientific group of Wakeling recently discussed this phenomenon.

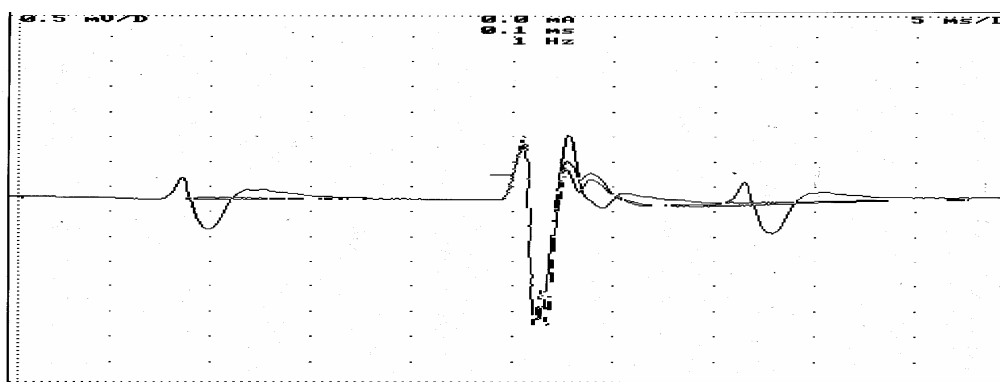


Fig. 2. Jitter phenomena registered from the left *tibial anterior* muscle at the patient with spinal meningioma of Th6-Th9 spinal cord level after surgical remove.

In the motoneuron innervated by chronically compressed medullar segments by the neoplastic process number of the motor unit's polyphasic potentials was elevated constantly. Signs of the peripheral motoneuron lesions in the case of the polyphasic MUP are:

- from the total number of the registered potentials polyphasic ones are more than 16%
- internal and external aspects of the polyphasic potential is modified as well;
- amplitude and duration of the polyphasic potential increase in correlation with denervation-reinnervation process.

Statistical analysis didn't establish conclusive correlation between phases number of polyphasic MUP and denervation-reinnervation process phase ($p > 0,05$), as well as percentage of the polyphasic MUP and evolutive stage of the spinal meningiomas ($p < 0,1$).

Second exam of the MUP in 16 patients with motor disturbances in the muscles of the upper and lower extremities permitted to establish three classes of survived motor units: 1) MUP which are controlled voluntarily with the same level of the excitability as in the control group; 2) MUP with spontaneous involuntary activation, number of which is varying upon the expression of the paresis or paralysis; 3) MUP which can be activated slowly and weakly.

Between class of survived MUP in the spinal meningiomas patients were observed 3 subgroups additionally: a) MUP of the regular form (2-4 phases); b) polyphasic MUP (5 or more phases); false polyphasic MUP-special type of MUP with regular number of phases, but with additional oscillations in the positive and/or negative portions that don't come to isoelectric level. (fig. 3)

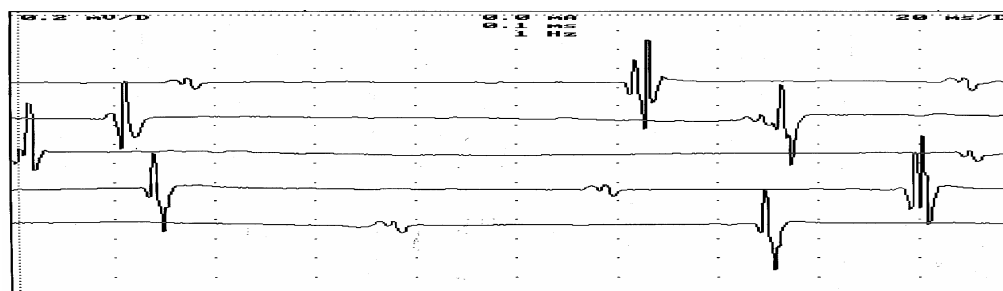


Fig. 3. Polyphasic potentials with „turnover” of MUPs after one week post-surgical remove of spinal meningioma registered from the *vastus lateralis dexter* muscle at the patient with spinal meningioma of thoracic level.

In all the patients with severe paresis predominate the class of the motor units that can be slowly and weakly activated (from 43 to 76% from all survived MUP). This kind of patient have being told to stop voluntary activity realized the request in 5-10 sec. In case of the activation these potentials can be registered and analyzed constantly.

Conclusions

1. Complex utilization of the clinical, imagistical examination (CT-myelography, MRI, selective spinal angiography) and needle-EMG enhances knowledge of the muscular denervation process pathogeny by chronic progressive medullar compression, allows functional evaluation of the spinal cord and patients monitoring in the early and late post-surgery stage.
2. Persistent spontaneous muscular activity like fibrillations and sharp waves registered by needle-EMG is typical electrophysiological phenomenon in spinal meningiomas patients with different localization
3. Slowly progressive spinal meningioma leads to morpho-functional reorganization of the motor units and segmentar neuro-motor apparatus with installation of the specific potentials for different phase of the medullar compression evolution. Needle-EMG exam of the muscles innervated by medullar segments adjacent to ischemic process revealed existence of three classes between survived motor units potentials (MUP).

References cited

1. Calogero J.A., Mossy J., *Extradural spinal meningiomas. Report of four cases.* J Neurosurg, 1972, 37: 442-447.
2. Harkey H.L., Crockard H.A., *Spinal meningiomas: Clinical features.* In Al-Mefty O. (ed): Meningiomas Raven Press, New York, 1991: 593-601.
3. Jenny B., Rilliet B., May D., et al., *Abord transthoracic transvertebral pour resection d'un méningiome calcifié de situation antérieure.* Neurochirurgie 2002, 48: 49-52.
4. Klekamp, Samii, *Spinal meningiomas.* Surg. Neurol, 1999, 52: 552-562.
5. Nittner K., *Spinal meningiomas, neurinomas and neurofibromas and houglass tumors.* In: Vinken P.J., Broyn G.W. (eds). Handbook of clinical Neurology, vol. 20. Amsterdam. North-Holland Publishing, 1976: 179-322.
6. Raez M.B., Hussain M.S., Mohd-Yasin F., *Techniques of EMG signal analysis: detection, processing, classification and applications.* Biol Proced Online, 2006, 8:11-35.
7. Russel D., Rubinstein L.J., *Pathology of Tumours of the Nervous System.* London: Edward Arnold LTD, 1959.
8. Solero C.L., Fornari M., Giombini S., et al., *Spinal meningiomas: review of 174 operated cases.* Neurosurgery 1989, 25: 153-160.
9. Stern J., Whelan M.A., Correll J.W., *Spinal Extradural meningiomas.* Surg. Neurol, 1980, 14: 155-159.
10. Wakeling J.M., Uehil K., Rozitis A.I., *Muscle fibre recruitment can respond to the mechanics of the muscle contraction.* J. R. Interface, 2006, 3(9): 533-544.

ASPECTUL CORELATIV AL MANIFESTĂRILOR CLINICE ȘI ELECTROENCEFALOGRAFICE ÎN EPILEPSIA CATAMENIALĂ

Victoria Duca

Centru Național Științifico-Practic Medicină de Urgență, Departamentul de Neurologie

Summary

Correlative aspect of clinical and electroencephalographic manifestation in the catamenial epilepsy

The clinical observation of the relationship between epileptic seizure and the menstruation of women, lead to a common belief that seizures, sometimes, occur more frequently in relationship to menstrual cycle. Catamenial epilepsy is considered as a menstrual cycle-related seizure disorder and is characterized by an increase in seizures during particular phases of the menstrual cycle. The relationship between seizures exacerbation and cerebral discharges is less elucidate and is controversial.

Rezumat

Corelația dintre crizele epileptice și perioada ciclului menstrual la femei a dedus ideea unui caracter mai ritmic al crizelor în dependență de faza menstruației. Epilepsia catamenială este definită ca o disfuncție dependentă de faza ciclului menstrual și se caracterizată printr-o majorare a ritmicității crizelor pe parcursul anumitor perioade a menstruației. Corelația dintre exacerbările crizelor și descărcărilor cerebrale este controversat și neelocvent.

Actualitatea

Epilepsia catamenială este definită ca „o majorare marcantă a frecvenței crizelor epileptice către menzis”.(1) Se consideră că, aceste crize sunt induse de hormonii steroizi reproductivi, estrogenul și progesteronul, care posedă proprietăți neuroactive.(4) Proprietățile neuroactive și variația ciclică a concentrației lor plasmatică sunt factori patofiziologici importanți în declanșarea procesului epileptogen. Studii recente au demonstrat și confirmat existența a 3 pattern-uri în exacerbarea crizelor catameniale: premenstrual și ovulator în ciclul menstrual