

6. Бернадский Ю.И. Основы челюстно–лицевой хирургии и хирургической стоматологии. Москва. Медицинская Литература 2007. стр. 54, 64.
7. Огороков А.Н. Диагностика болезней внутренних органов. Том 5. Москва. 2007, стр. 186-203.
8. Тимофеев А.А. Руководство по челюстно-лицевой хирургии и хирургической стоматологии. Киев: 000 «Червона Рута-Туре» 2002, стр. 163-164.

TILTED IMPLANTS AS AN ALTERNATIVE TREATMENT TO SINUS LIFT

Fahim Atamni

Clinic for Oral-Surgery and Implantology Tel-Aviv
Department of Oral and Maxillofacial Surgery, Orthopedic Stomatology and Oral Implantology
USMF “N.Testemitanu”

Abstract

The purpose of this investigation was to modify the method for implant placement in the posterior maxilla to extend fixed implant connected prosthesis further distally and to reduce the length of cantilevers in complete – arch prostheses without performing any bone graft procedures in the posterior maxilla. One hundred eighteen patients were treated with 256 maxillary implants placed in tilted positions. There were identified from a search of more than 10 years archive materials based on retrospective study reporting on implants with a follow up time from 1 to 10 years of functional loading.

The posterior implants were placed close to and parallel with the sinus walls were tilted anteriorly /posteriorly approximately 30 to 35 degree. As a result of implant tilting patients gained a mean distance of 9.5 mm of prostheses support. Panoramic radiographs and maxillary computerized tomograms had been made for all patients prior to treatments. One hundred eighteen patients with severely resorbed maxilla were included in the study. Two hundred fifty six implants (two to eight in each patient) were placed to support 118 fixed prostheses; 125 were tilted anteriorly and 131 were tilted posteriorly. The success rate of tilting implants was 97 % (250/256). Secondary stability (SS) through Periotest values (PV) were recorded. All patients had stable prostheses at the end of observation period. Patients were satisfied with comfort and stability. Satisfactory medium-term results concerning osteointegration and significant extension of prostheses support show that the method can be recommended. Anteriorly/posteriorly tilted implants in the atrophied posterior maxilla may be a viable alternative to bone grafting procedure in posterior maxilla.

Key word: tilted implants, sinus lift, implant supported prostheses, edentulous maxilla

Introduction

Rehabilitation of edentulous posterior maxilla with dental implants is often associated with problems of anatomic origin and bite forces are at their greatest further back dentition. The severely resorbed maxilla presents serious limitation for conventional implant placement. As a result, different techniques have been developed.

The most famous approaches include implant placement in either zygoma or the pterygoid process, elevation of the sinus floor with bone grafting (1, 2). Each oral bone harvesting hospitalization, increases financial costs, creates donor sites morbidity and functional limitations, including pain and neurosensory deficit. However when the amount of available bone in the maxillary alveolar crest is less than 8 mm in the vertical aspect and 4 mm in the horizontal aspect the prognosis for implant treatment is poor (3). According to the original concept for the placement of Branemark System, an atrophied completely edentulous arch, in implants are placed in a fairly upright position (4). Consequently, it is often necessary to restore a cantilever that is up to 20mm in length so as to provide the patients with good masticatory

capacity in molar regions. Alternative methods in which the residual bone in the severe resorbed posterior maxilla is used for implant placement without bone grafting have been presented and include the short implant placement (5, 6) and placement of implants in anatomic butress (7, 8). Branemark et al (48) and Penarrocho et al (9) to achieve good primary implant stability, overcome the deficiency of a thin marginal crest with palatal positionary of implants. Another alternative method to avoid the low Sinus in the severe atrophied posterior maxilla is the use of tilted implant along the anterior and posterior maxillary sinus wall (10-12). Tilting of implants head in the posterior region was used to gain support advantages and minimize cantilever length (13). Prosthesis with cantilevers of 15 mm or less survived significantly better than fixed prosthesis with a cantilever length more than 15mm. In the literature, tilting of implants in the pterygoid plate in the posterior maxilla is reported indicating that this is a predictable procedure for gaining end support for prosthesis restoration (14, 15). Those implants were found to have a slightly higher failure rate (13.7%). Balshi et al 1995 although the authors explained that the low bone quality in the area requires a good level of surgical experience by the surgeon in order to obtain optimal primary stability. The implants placed in the second molar position can be tilted into the tuberosity area. Success rates for this procedure have been reported in the past as 93% (Venturell, 15) at 21.4 month and 97.6% at 36 month. Aparicio et al (10) used the two previously described configurations and the success rate in tilted implants reached 95.2% in implants with an axial load, the success rate was found to be 91.3%. The placement of implants in anterior or posterior tilted position allows maximum use of residual bone in the severe atrophied maxilla. The purpose was to evaluate this alternative treatment and to assess patient satisfaction in a retrospective study of 118 patients.

Materials and Methods

118 patients (72 female and 46 male, mean age 60years range 34 to 86) were followed for a period from 1 year to 10 years after loading. In these patients 256 anteriorly/posteriorly tilted maxillary implants were placed in an angulation position of 30 to 35 degree to expand the prostheses site without bone grafting procedures of the sinus. Different implants with different diameters and lengths were used in those patients. The most used implants were Alpha Bio SLA screw implant 13 mm in length and 4,2 mm in diameter. All patients were operated under local anesthesia on each side of the arch. Postoperatively all patients were given Ampicillin for 7 days and rinsed their mouths with chlorhexidine for one week.

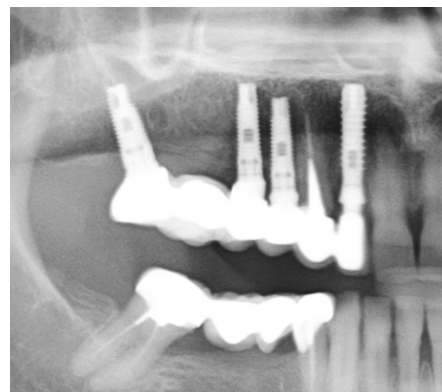
Surgical Technique

An incision on the alveolar crest from the first molar on one side to the first molar on the another side were made with bilateral releasing incision. A full thickness flap was buccally and palatally elevated. The bone surface of the maxilla was exposed. Angulation of the anterior sinus wall was visualized through a hole in the lateral wall of the sinus. The implants were placed close to an parallel with the anterior sinus wall with 30 to 35 degree tilting distally.

Figure 1.

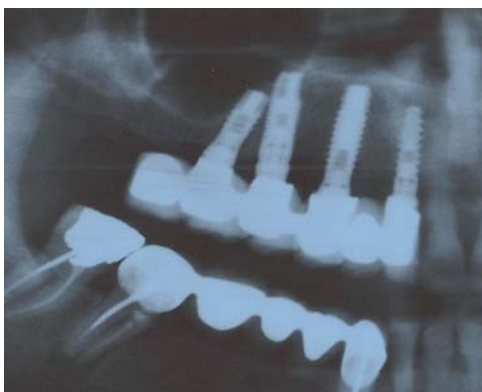

Figure 2.



Implant stability was measured and determined through Periotest Value (PV). Patients with sufficient bone in the tuberosity a similar surgery procedure placing anteriorly tilted implants close to the posterior sinus wall was performed. Flap covering and suturing were performed. Second stage was performed four months after implant placement. Abutment placement was performed. Prosthesis restoration began one week after abutment connection. At the follow up examinations the fixed prosthesis were removed and the implant stability was measured with periotest, orthopantomogram was taken to assure well integration of the implants.

Results

Two hundred fifty six anteriorly and posteriorly tilted implants were placed in 118 patients. The study involved patients with severely resorbed maxilla. Screw implants with different length and diameters were placed. The detailed implant lengths, diameters and positions were described and recorded. 118 fixed prosthesis were placed; 25 were screw retained and 93 were cemented. The opposing dentition was natural dentition or fixed prostheses on natural teeth in 35 patients, implant supported prostheses in 52 patients, a combination of these in 17 patients, and removable dentures in 14 patients. The cumulative implant success rates of the 256 implants placed in tilted position in the resorbed maxilla after a mean follow up of 6 years was 97%. In these cases, no evidence of pain or infection was observed, no mobility was noted according to PV, peri-implant radiolucencies were not seen. None of the patients showed remarkable postoperative complications or neurologic problems. Six implants failed in six patients. 4 of which were lost in the healing phase in the first three months post operatively. 1 implant failed in the 5 year and another one in the 7 year. The cumulative implant success rates are shown in Table 1.

Table 1: Cumulative success rates of tilted implants in the posterior maxilla

Time	Successful implants	Failed implants
< 1 year	44	4
1-2 years	36	-
2-3 years	37	-
3-4 years	24	-
4-5 years	33	1
>5 years	76	1

All patients were satisfied with comfort and stability, esthetics and function of the fixed prostheses. None of the patients experienced interference space between the prostheses and residual crestal bone. Patients initially seemed to have problems with cleaning distally in their mouth, regardless of whether the implant was tilted or not. The prostheses bone extension gained in the maxilla was 9, 5 mm.

Discussion

Implant tilting can allow for an increase in the inter implant distance and a reduction in cantilever length so that a better load distribution can be achieved, a possible biomechanical advantage may have been gained by using tilted implants in the rehabilitation of the completely edentulous maxilla. The clinical results of our study indicate that implant tilting seems to be both clinically and biologically advantageous (16-17). The reason for the improved situations for the tilted implants may be that they were longer and had a larger contact area with cortical bone both these improvements make the high success rate of tilted implants 96% (18). This means that implant loading was not influenced by tilting. Mattsson et al presented an alternative method, in which the maximum amount of the severely resorbed alveolar crest was used for implant placement without bone grafting. These authors described a surgical technique with fenestration of the maxillary sinus to visualize the total amount of maxillary bone, followed by tilted placement of implants along the anterior maxillary sinus wall. Rosen and Gynther placed 103

tilted implants in 19 patients with a success rate of 97% (19). One patient had difficulty biting at the front, eight patients reported speaking differently after the application of a new prosthesis, seven patients reported esthetic problems. The clinical implication of this study is that more patients can be successfully treated with tilted implants without complex grafting procedures, grafting of the maxilla. A part of the patients included in this study would not have been treated with conventional implant placement without grafting procedure. Placement of tilted implants is not considered to be more complicated than conventional implant placement.

Conclusions

Tilting implants may provide an alternative approach to the rehabilitation of atrophied maxilla reducing patient morbidity compared to conventional augmentation procedures. It leads an improved position of the support and allows for placement of longer implant or improved anchorage in dense bone. Biomechanical measurements show that the tilting does not have a negative effect on the load distribution when it is a part of prosthesis support. The advantages of tilting implants are: 1. Possible use of longer posterior implants which had a larger contact area with cortical bone, and improved bone anchorage. 2. Avoid the need for such advanced grafting techniques for some patients. 3. The technique is relatively easy to perform in any private clinic by surgeon, who is not trained for advanced techniques. 4. Allows further extension of the prosthesis in posterior direction. 5. Reducing the treatment time evidently.

References

1. Sorni M, Guarinos J, Penarorocha M. Implants in anatomical buttresses of the upper jaw. *Med oral Patol Oral Cir Bucal* 2005 ;10 :163-168.
2. Aghabeigi B, Bousdras VA. Rehabilitation of severe maxillary atrophy with zygomatic implants. *Clinical report of four cases. Br Dent J* 2007;202:669-675.
3. Mattsson T, Kondell PA, Gynther GW, Fredholm U, Bolin A. Implant treatment without bone grafting in severely resorbed edentulous maxillae. *J Oral Maxillofac Surg* 1999;57:281-287
4. Branemark PL, Adell R, Albrektsson T, Lekholm U, Lindstrom J, Rockler B. An experimental and clinical study of osseointegrated implants penetrating the nasal cavity and maxillary sinus. *J Oral Maxillofac Surgery* 1984; 42, 497-505.
5. Misch CE, Steigenega I, Barboza E et al: Short dental implants in posterior partial edentulism: a multicenter retrospective 6-year case series study, *J Periodontol* 77:1340-1345, 2006.
6. Misch CE, short dental implants: a literature review and rationale for use, *Dem Today* 24:64-68, 2005.
7. Valeron JF, Valeron PF. Long-term results in placement of screw-type implants in the pterygomaxillary-pyramidal region. *Int J Oral Maxillofac Implants* 2007;22:195-200
8. Malevez C, Abarca M, Durdu F, Daelemans P. Clinical outcome of 103 consecutive zygomatic implants: A 6-48 months follow-up study. *Clin Oral Implants Res* 2004;15:18-22
9. Penarrocha M, Uribe R, Garcia B, Marti E. Zygomatic implants using the sinus slot technique: Clinical report of a patient series. *Int J Oral Maxillofac Implants* 2005;20:788-792.
10. Aparicio C., Perales P., Rangert B. Tilted implants as an alternative to maxillary sinus grafting: a clinical, radiologic, and periosteal study. *Clin. Implant. Dent. Res.* 2001;3: 39-49.
11. Capelli M, Zuffetti F, Del Fabbro M, Testori T. Immediate rehabilitation of the completely edentulous jaw with fixed prostheses supported by either upright or tilted implants: a multicenter clinical study. *Int. J. Oral. Maxillofac. Implants* 2007; 22: 639-44
12. Krekmanov L., Kahn M., Rangert B., Lindstrom H. Tilting of posterior mandibular and maxillary implants for improved prosthesis support. *Int. J. Oral. Maxillofac. Implants.* 2000; 15: 405-14/

13. Becker C.M. Cantilever fixed prostheses utilizing dental implants: a 10 year retrospective analysis. *Quintessence Int.* 2004;35:437-41.
14. Balshi T.J., Lee H.Y., Hernandez R.E. The use of pterygomaxillary implants in the partially edentulous patient: a preliminary report. *Int. J. Oral. Maxillofac. Implants* 1995; 10: 89-98.
15. Venturelli A. A modified surgical protocol for placing implants in the maxillary tuberosity: clinical results at 36 months after loading with fixed partial dentures. *Int. J. Oral. Maxillofac. Implants.* 1996; 11: 743-9
16. Krekmanov L. Placement of posterior mandibular and maxillary implants in patients with severe bone deficiency: clinical report of procedure. *Int. J. Oral. Maxillofac. Implants.* 2000; 15: 722-30.
17. Malo P., Rangert B., Nobre M. All-on-4 immediate-function Concept with Branemark System implants for completely edentulous maxillae: a 1 year retrospective clinical study. *Clin Implant Dent Relat Res.* 2005 ; 7 Suppl 1 :88-94.
18. Testori T., Del Fabbro M., Capelli M., Zuffetti F., Francetti L., Weinstein R.L. Immediate occlusal loading and tilted implants for the rehabilitation of the atrophic edentulous maxilla. One year interim results of a multicenter prospective study. *Clin Oral Implants Res* 2008;19:227-232
19. Rosen A, Gynther G. Implant treatment without bone grafting in edentulous severely resorbed maxilla: A long-term follow-up study. *J Oral Maxillofac Surg* 2007; 65: 1010-1016.

SHORT IMPLANTS AS A ALTERNATIVE TO LATERAL SINUS LIFT

Fahim Atamni

Clinic of Oral-Surgery and Implantology Tel-Aviv

Department of Oral and Maxillofacial Surgery, Orthopedic Stomatology and Oral Implantology
USMF "N. Testemitanu"

Abstract

The present studies evaluated short implants placement in the posterior maxilla with less than 10mm residual bone height to avoid invasive surgery such as maxillary sinus augmentation through a lateral approach. Two different surgical techniques; flapless surgical technique and flap opening technique were performed. Patients had been treated between the years 2000 to 2009 with different screw implants.

624 short implants, 8 mm in length and different diameters were placed in the partially or completely edentulous maxilla of 156 patients in the posterior maxilla and all patients were restored with fixed prosthesis. The patients mean age was 57 years (range 30 to 84 years) (92 females, 64 males). During stage II surgery and before loading, 25 short implants (4%) were not osseointegrated and were removed. After a mean loading period of 5 years 2 additional short implants were lost. Altogether 27 implants of 624 implants were removed; survival rates were also recorded. The secondary stability (SS) of implants was also evaluated immediately after implant exposures and then each year after first examination. This study showed a cumulative survival rate of 95% for short implants placed in the posterior maxilla.

Key words: short implants, survival rate, fixed prosthesis, sinus lift.

Introduction

The anatomy of the posterior maxilla presents many limitations to implant placement. These anatomic factors include poor bone quality and decreased bone quantity (1), location of the atrium. Because of these anatomic factors and some biomechanical factors (2), one would expect the success rate for implants placed in the posterior maxilla to be lower than that for other locations. In 1991, Reiger (3) recommended using a larger number of implants in the posterior maxilla to compensate for the decreased predictability for osseointegration in that area. Langer et