

# THE CLINICAL AND FUNCTIONAL DATA IN CHILDREN WITH CHRONIC OTITIS MEDIA WITH EFFUSION

Ion Ababii, Svetlana Diacova, Angela Chiaburu, Diana Chirtoca, Raghid Jened

Catedra Otorinolaringologie USMF «Nicolae Testemițanu»

## Summary

We described and compared the clinical and functional data of children suffering from Chronic Otitis Media with Effusion, who were under our supervision. The impedance audiometry is a single objective method of appreciation of the middle ear status. The indications for impedance audiometry testing are: irritability, difficulties in communications with other children, non adequate reaction on parents call, sleep disorders, periodically moodiness without any reasons, loudness in talking and delay of the speech formation, frequent respiratory tract infection, allergy reactions, periodical intestinal disorders, neurological pathology, recurrent or chronic pathology of the nose and pharynx, any otoscopic abnormalities detected by the family doctor in a child in the first 5 years of life.

## Rezumat

Am descris și comparat date clinice și funcționale la copii cu Otită Medie Exsudativă Cronică care au fost sub supravegherea noastră. Impedansmetria este o metoda unică obiectivă de apreciere a stării urechii medii. Indicațiile pentru impedansmetrie sunt: iritabilitatea, dificultăți în comunicare cu alți copii, reacția neadecvată la adresarea părinților, dereglările somnului, periodic lipsa dispoziției copilului fără o cauză evidentă, vorbirea foarte tare și retardul vorbirii, infecțiile frecvente ale tractului respirator, reacțiile alergice, tulburări intestinale periodice, patologii neurologice, patologia recidivantă sau cronică ale nasului și faringelui, orice anomalii otoscopice detectate de către medicul de familie la copil în primii 5 ani de viață.

## Introduction

Otitis Media with Effusion (OME) is a subclinical inflammation of the middle ear and presence of liquid in the tympanic cavity. [1, 2] Recurrent infection of upper respiratory tract, allergic changes in nasopharynx in early childhood provoke accumulation of pathological liquid in nasopharynx. Some anatomical features of the Eustachian tube in children predispose to reflux of pathological liquid from nasopharynx to the middle ear through this tube. Absence of the adequate treatment at the beginning of OME leads to formation of chronic otitis media with effusion, recurrent otitis media, adhesive otitis media, and chronic otitis media with cholesteatoma formation. Therefore the timely diagnosis of OME is very important for beginning of adequate treatment and prevention of further evolution of otitis media.

Chronic Otitis Media with Effusion (COME) is a persistent inflammation of the middle ear and presence of sticky fluid in the tympanic cavity for more than 3 months. [3, 4, 5] In the majority of cases the OME has relatively asymptomatic course which complicates diagnosis at time. [6, 7]

The ORL doctors are using pneumatic otoscopy and tympanometry for the detection of otitis media with effusion, but the functional diagnostic methods are not always available for medical practitioners (family doctors) who are responsible for diagnosis and treatment of otitis media.

## Purpose

The purpose of our research is to describe and compare the clinical and functional data in children suffering from Chronic Otitis Media with Effusion.

## Material and methods

Our research was carried out in the pediatric ORL Clinic of the Department of Otorhinolaryngology, “Em. Cotaga” Republican Hospital for children. The study involved 35

patients at the age from 1 to 18 years with Chronic Otitis Media with Effusion (COME). The final diagnosis was based on the data of surgical findings and morphological examination of the middle ear mucosa.

The Work Up included anamnesis, anterior and posterior rhinoscopy, oropharyngoscopy and pneumatic otoscopy, otomicroscopy, conventional audiometry, impedance audiometry otomicroscopy during surgery, examination of surgical findings. [6, 7]

Various background characteristics were recorded for the purpose of identifying risk factors associated with COME. These included information on the following: socio-economic status of parents, their age, presence of chronic diseases and ORL - pathology in parents and other children in the family; some points of nutrition and development of infant during first year of life, beginning of the disease; history of otitis media, respiratory tract infection, intestinal disorders, neurological disorders; antibiotic therapy; some points of child behavior, sleeping; level of speech and other information.

The routine ORL examination was carried out with the scope to identify the acute and chronic inflammation of the nose and paranasal sinuses, presence of the inflammation or hypertrophy of nasopharyngeal and palatine tonsils, etc.

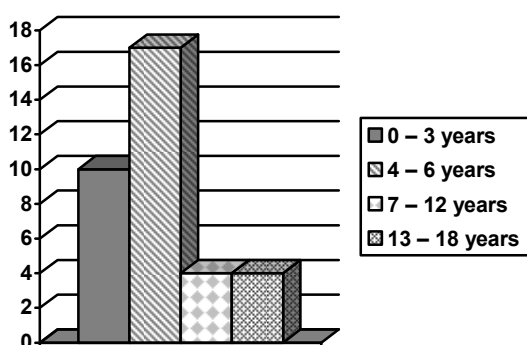
During the pneumatic otoscopy we registered color, thickness, transparency of the tympanic membrane, visibility of main points, mobility of tympanic membrane and we compared these data with the most precise examination – otomicroscopy during surgery.

The hearing assessment of the patients was performed using conventional audiometry test and play audiometry test (according to age and child behavior).

Impedance audiometry which included tympanometry and acoustical reflex registration was performed for evidence of the middle ear compliance.

## Results

We included in our work 35 children with the diagnosis otitis media with effusion; the total number of ears was 61 (in 9 patients only 1 ear was affected). Age distribution at the time of surgery performed for OME is presented on Fig.1. Ten patients were operated for OM during their first three years of life, 17 patients were operated at 4 to 6 years of age, and 8 patients were operated at 7 to 18 years of age.



Age groups of patients	No of patients
0 – 3 years	10
4 – 6 years	17
7 – 12 years	4
13 – 18 years	4
Total	35

Fig. 1. Age distribution of patients with COME

## Anamnesis

The onset of OME began early in the majority of the patients. The mean age of otitis media onset was 3.74 years (SD 1.63).

Detailed analysis of the disease history revealed presence in all children of at least 2 signs from the list: irritability, difficulties in communications with other children, non adequate reaction on parents call, sleep disorders, periodically moodiness and tearfulness, loudness in talking and lay of the speech formation.

Parents of 27 children have noted frequent respiratory tract infection. Allergy reactions were characteristic for 13 children. Periodical intestinal disorders were registered in 9 patients. Some neurological pathology was diagnosed in 23 children.

ORL examination.

All children had recurrent or chronic pathology of the nose and pharynx. (Table 1) The adenoid hypertrophy and adenoiditis were registered in majority of the cases.

Table 2

ORL pathology in children with COME

ORL pathology	No of patients
Adenoid hypertrophy	32
Adenoid infection	27
Tonsil hypertrophy	25
Tonsil infection	18
Nose and sinus infection	15

Otoscopy

Tympanic Membrane was relatively intact during conventional otoscopy (grey, or grey yellowish color), mild retraction of the tympanic membrane or on the contrary – dullness, flattening of the main points, changes of light reflex – enlargement, disappearance, abnormal shape and position, etc.

Pneumatic Otoscopy revealed: dullness, opacity, thickness, low visibility of main points, enlargement of vessels and changes of light reflex – enlargement, disappearance, abnormal shape and position.

Test mobility of tympanic membrane: we were able to perform this test in children older than 5 years (21 ears). Tympanic Membrane mobility was absent in all cases.

Audiometry

In all patients we registered mild conductive hearing loss and the mean hearing level before surgery was 35 dB.

Impedance audiometry

Impedance audiometry test confirmed presence of otitis media in all cases. Type B of tympanogram was registered in 96 % of ears, Type C<sub>2</sub> - in 4 %. No any Acoustical Reflex was registered.

Otomicroscopy

Otomicroscopy during surgery revealed dullness, opacity, thickness, low visibility of main points, enlargement of vessels, changes of light reflex – enlargement, disappearance, abnormal shape and position, retraction pockets and thin-film adhesion.

Effusion was present practically in all ears, thick, glue-like effusion was found in 49 ears, serous liquid was aspirated in 6 ears and purulent effusion was noted in 6 ears. All these patients were older than 6 years of life.

Case Study.

A three years old boy with the history of poor school progress, slight speech delay, irritability, and disturbances of sleeping was examined at our Clinic. From his history we knew that he had had some allergic reactions and repeated courses of acute otitis media in past.

The Otoscopy examination revealed a dull, opaque, retracted eardrum, which moved sluggishly, did not transmit light and was retracted.

Examination of the nasopharynx showed presence of Hypertrophy of Adenoids and Adenoiditis.

The Impedance audiometry displayed type B of the tympanogram, and absence of Acoustical Reflex.

Audiometry showed hearing loss bilaterally 35 – 40 dB.

On the basis of these data we diagnosed Otitis Media with Effusion, Hypertrophy of Adenoids and Adenoiditis.

The child was prescribed 2 consecutive courses of conservative treatment during 1 month which consists of antibiotic treatment, antihistamine therapy, mucolytics, and glucocorticosteroids. The effect after this treatment was appreciated by the results of otomicroscopy and functional examination in dynamics. The first month after the treatment we registered some positive changes – good nasal respiration, no any discharge from the nose and functional examination of ears showed better results: otoscopy - tympanic membrane practically normal; impedance audiometry - type C<sub>2</sub> of the tympanogram, without any acoustical reflex. But in 2 weeks clinical and functional examination of nose and ears demonstrated pathological changes characteristic for Chronic Otitis Media with Effusion, Hypertrophy of Adenoids.

We performed surgical treatment which included Myringotomy with Tympanostomy tube insertion and adenoidectomy. Our surgery confirmed the diagnosis and its chronic course (presence of thick mucous fluid behind the tympanic membrane bilaterally).

### Discussion

The age of OME onset in our patients was first 3 years of life. The disease developed on the base of nasopharyngeal pathology hypertrophy of adenoids, adenoiditis, sinusitis, tonsillitis, etc. This middle ear inflammation manifests with only one single symptom – mild, sometimes undulating, hearing loss. These hypoacusis is not evident for the child and his parents because of early age of the child. Some changes in a child behavior on the basis of hearing loss in the majority of cases are appreciated by parents as some psycho-neurological pathology. Therefore parents go to neurologist and family doctor. Some parents check their child ears in family doctor office with the otoscope. But simple otoscopy examination is not helpful for diagnosis of OME because of enough minimal changes of the tympanic membrane. Therefore the correct and precise diagnosis is delayed. The impedance audiometry is a single objective method of appreciation of the middle ear status.

The indications for impedance audiometry testing are:

1. irritability, difficulties in communications with other children, non adequate reaction on parents call, sleep disorders, periodical moodiness and tearfulness, loudness in talking and lay of the speech formation,
2. frequent respiratory tract infection, allergy reactions, periodical intestinal disorders, neurological pathology
3. recurrent or chronic pathology of the nose and pharynx
4. any otoscopic abnormalities detected by family doctor

### Bibliography

1. Daly KA, Hunter LL, Levine SC, Lindgren BR, Bruce R, Giebink GS. Relationships between otitis media sequelae and age. *Laryngoscope* 1998;108(9):1306-10.
2. Ababii I., Diacova S., Chiaburu A. Tratamentul chirurgical al otitelor medii la copii // Buletin de Perinatologie, N 1, 2002, p. 46 - 48.
3. Chalmers D., Stewart I., Silva Ph., Mulvena A. - Otitis media with effusion in children. The dunedin study. // *Mac Keith Press. London.* 1989, P. 1 - 167.
4. van Cauwenberge P, Watelet JB, Dhooge I. Uncommon and unusual complications of otitis media with effusion. *Int J Pediatr Otorhinolaryngol* 1999;49 Suppl 1:119-25.
5. Diacova S., Ababii I. - Our experience in diagnosis, treatment and follow up of otitis media with effusions in infancy. // *6<sup>th</sup> International Conference on Physiology and Pathology of Hearing.* September 14-16, 1999, Mikolajki, Poland. Abstracts. P. 125 - 126.
6. Diacova S., McDonald T., Beatty Ch., Wei J. - Ear drops in preventing otorrhea associated with tympanostomy tubes insertion in children // *4<sup>th</sup> European Congress of Oto-Rhino-Laryngology Head and Neck Surgery.* May 13 - 18, 2000. ICC Berlin, Germany. Abstracts. P. 56.

7. Diacova S., McDonald T. A comparison of outcomes following tympanostomy tube placement or conservative measures for management of otitis media with effusion // *Ear Nose Throat J* 2008, V.86:552-4

## **PAPILOMATOZA LARINGIANĂ. TENDINȚE ACTUALE ÎN TRATAMENT**

**Ion Ababii, Vladimir Popa, Alexandru Sandul, Victor Osman,  
Boris Chirtoacă, Ludmila Guțuleac**

Catedra Otorinolaringologie USMF ” Nicolae Testemițanu ”

### **Summary**

#### ***Laryngeal papillomatosis. News in the treatment***

Laryngeal papillomatosis is a disease consisting of tumors that grow inside the larynx (voice box), vocal cords, or the air passages leading from the nose into the lungs (respiratory tract). Laryngeal papillomatosis affects infants and small children as well as adults. It is caused by HPV types 6 and 11. The papillomas may vary in size and grow very quickly. Without treatment it is potentially fatal as uncontrolled growths could obstruct the airway. These tumors can reoccur frequently, may require repetitive surgery, and may interfere with breathing. The disease can be treated with surgery and antivirals.

### **Rezumat**

Papilomatoza laringiană se prezintă sub forma unor multiple formațiuni tumorale papilare la nivelul corzilor vocale, de unde se pot extinde spre benzile ventriculare, epiglotă și în cazuri rare spre trahee și bronhii. Afectează atât copiii, cât și adulții. Agentul etiologic este HPV, subtipurile HPV 11 și HPV 6. O evoluție agresivă a patologiei în condițiile unor bolnavi nesupravegheați poate provoca blocarea căilor respiratorii. Este recunoscută ca o afecțiune gravă, recidivantă. Algoritmul de tratament constă în ablația chirurgicală și medicația antivirală.

### **Actualitatea temei**

Papilomatoza laringiană este o maladie gravă, cu o rată înaltă a recidivelor. Frecvent întâlnită la copii, incidența fiind de 0,2 -0,7 la 100 mii locuitori, dar poate debuta și la adulți, astfel încât 1/3 din cazurile de papilomatoză laringiană debutează după vârsta copilăriei.

La adulți se determină o predominanță masculină, vârsta clasică de debut fiind 20-30 ani, dar poate fi prezent și un debut tardiv.

Un studiu epidemiologic danez arată o incidență a patologiei de 3,94 la 100 mii locuitori adulți [5].

Studiu efectuat de specialiștii americani arată o incidență a patologiei de 1,8 la 100 mii locuitori adulți [5].

Algoritmul de tratament al papilomatozei laringiene este în continuă cercetare, pînă în prezent fiind definite următoarele metode:

- laringoscopia suspendată cu ablația papiloamelor
- vaporizarea Laser CO2 a patului restant
- tratamentul cu interferon
- autoimunoterapia
- terapia fotodinamică
- folosirea LASER-ului PDL (pulsed dye LASER).

### **Obiectivele lucrării**

Familiarizarea cu patologia papilomatoza laringiană, efectuarea unei sinteze a metodelor contemporane de tratament.