

# IN VIVO EVALUATION OF XENOGENEIC ACELLULAR BOVINE FASCIA GRAFTS IN THE RECONSTRUCTION OF ABDOMINAL WALL DEFECTS IN SWINE EXPERIMENTAL MODEL

**Negru I.**

*Public Institution State University of Medicine and Pharmacy "Nicolae Testemițanu",  
PMSI Mother and Child Institute, Chisinau, Republic of Moldova*

## ABSTRACT

In this study autor purpose to evaluate the feasibility of using bovine fascia in the experimental substitution of the fascial plan for the reconstruction of major anterior abdominal wall defects in the experimental model.

Plastic reconstruction of the surgically induced abdominal wall defect using decellularized bovine fascia grafts was performed on 5-week-old Landrace pigs (3 animals) in which the abdominal wall defect of 10x5.0 cm was surgically induced with the involvement of all layers, including the peritoneum. The animals were subsequently euthanized 90 days after the intervention. For decellularization, sterile 0.5% SDS solution (HiMedia) was used in volume required to obtain acellular tissues. The solution was changed every 24 hours for 72 hours.

The preventive results of the histopathological examination allowed the author to conclude that the use of decellularized bovine fascia grafts in the experimental model is characterized by the dominance of active regenerative processes with tissue remodeling and host cell invasion, the xenogeneic implant tissues being subjected to gradual degradation and substituted with the neoformed host connective tissue, the rationale of the usefulness of this biological material requiring additional comparative and clinical immunological studies.

The results of this experimental study allow us to conclude the following that the usage of bovine fascia acellular grafts as an alternative xenogeneic biological implant in reconstructive surgery of abdominal wall defects, this option requiring additional comparative and clinical immunological studies.

*Key words:* bioimplant, acellular grafts, bovine fascia, reconstructive surgery

## INTRODUCTION

The use of biological implants is a new and alternative approach to the reconstruction and regeneration of soft tissues with promising results. The purpose of the study was to evaluate the feasibility of bovine fascia use in the substitution of the fascial plan for the reconstruction of the anterior abdominal wall defects in the swine experimental model.

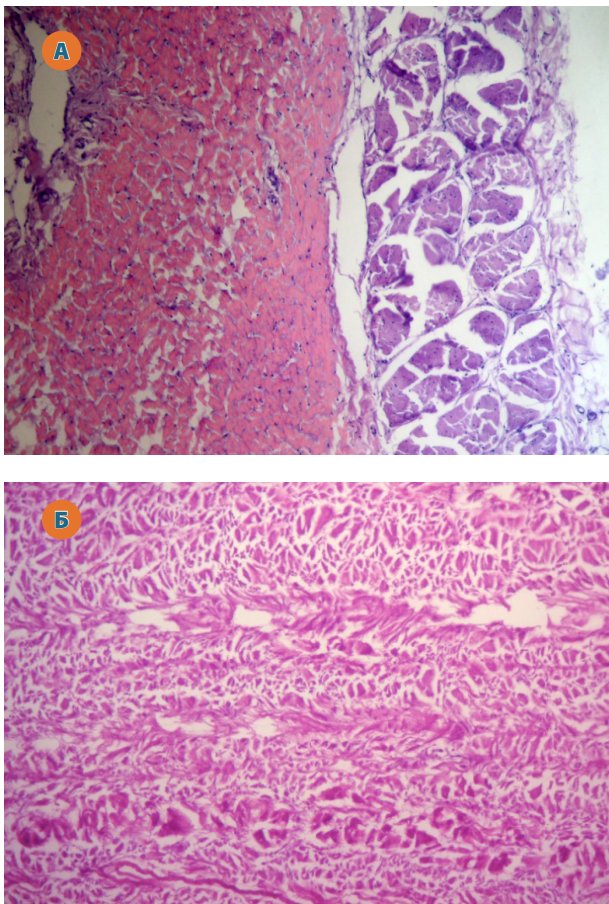
Several approaches to the reconstruction of abdominal wall defects, including the components separation technique, pedicle and free flap reconstructions, the use of synthetic and biological implants, etc., are described in the literature. These methods have as main objective the protection of the abdominal contents and the restoration of the functional support [27]. Although synthetic surgical implants are capable of providing the necessary biocompatibility and acceptable resistance in supporting abdominal cavity organs, their use is associated with the development of some adverse effects, including fibrous encapsulation, infection, erosion, net expulsion, fistula, intestinal obstruction, etc. [7, 23]. Reconstructive surgical interventions using remote musculofascial tissues are associated with

postoperative morbidity, functional disturbances and volume deficiencies in the donor region. The use of biological implants is a new and alternative approach to the reconstruction and regeneration of soft tissues with promising results, which could provide an accessible source of tissues with appropriate properties [17, 22, 24]. In order to avoid the adverse inflammatory response present in cases of the use of organ transplants, it is necessary to effectively remove cellular components and antigenic structures, efficient decellularization being extremely important, whether the source is allogeneic or xenogeneic. In this context, currently several decellularized grafts (extracellular matrices) of both human (allogeneic) and animal (xenogeneic) origin are available in the reconstruction of the abdominal wall [8, 12]; testing of the properties and efficacy of these biomaterials being under constant attention [11, 16].

The purpose of this study was to evaluate the feasibility of using bovine fascia in the experimental substitution of the fascial plan for the reconstruction of major anterior abdominal wall defects in the experimental model.

## MATERIAL AND METHODS

Plastic reconstruction of the abdominal wall defect using decellularized bovine fascia grafts was performed on 5-week-old Landrace pigs (3 animals) in which the abdominal wall defect of 10x5.0 cm was surgically induced with the involvement of all layers, including the peritoneum; the animals being subsequently euthanized 90 days after the intervention. The process of decellularization of bovine fascia allografts was preceded by decontamination for 6 hours in the antibiotic cocktail (gentamicin (KRKA), lincomycin (World Medicine), amphotericin B (World Medicine) with RPMI (HiMedia). For decellularization a sterile 0.5% SDS solution (HiMedia) was used in volume required to obtain acellular tissues. The solution was changed every 24 hours for 72 hours. After decellularization under sterile conditions, the membrane was washed thoroughly with 0.9% NaCl solution, after which it was repeatedly decontaminated for 24 hours in the antibiotic cocktail, the efficiency of decellularization being histologically confirmed (fig. 1).



**Fig. 1.** Histological appearance of the bovine pericardium before decellularization (A), with preserved differentiated fibrillary connective structure of different density with an obvious marked nuclear-cellular component.  $\times 100$  VG Colouration and after decellularization (B) highlighting arranged acellular connective tissue bundles among which the extracellular matrix appearance is attested.  $\times 25$ . H-E Staining.

For bacteriological examination to determine sterility, the solution was collected in which SDS tissues were washed, 2 ml of transport fluid and 3-4 small portions of 5x5 mm tissue from different graft sections in Thioglycolate Medium (HiMedia) and Sabouraud Dextroze Broth (HiMedia). The incubation was performed for 7-10 days to get final results. Tissues for storage at  $-86^{\circ}\text{C}$  were placed in 50% Glycerol (Alchimia) solution with RPMI (HiMedia) and stored in the freezer at  $-80^{\circ}\text{C}$ . Before use, the tissues were thoroughly washed with 0.9% NaCl solution.

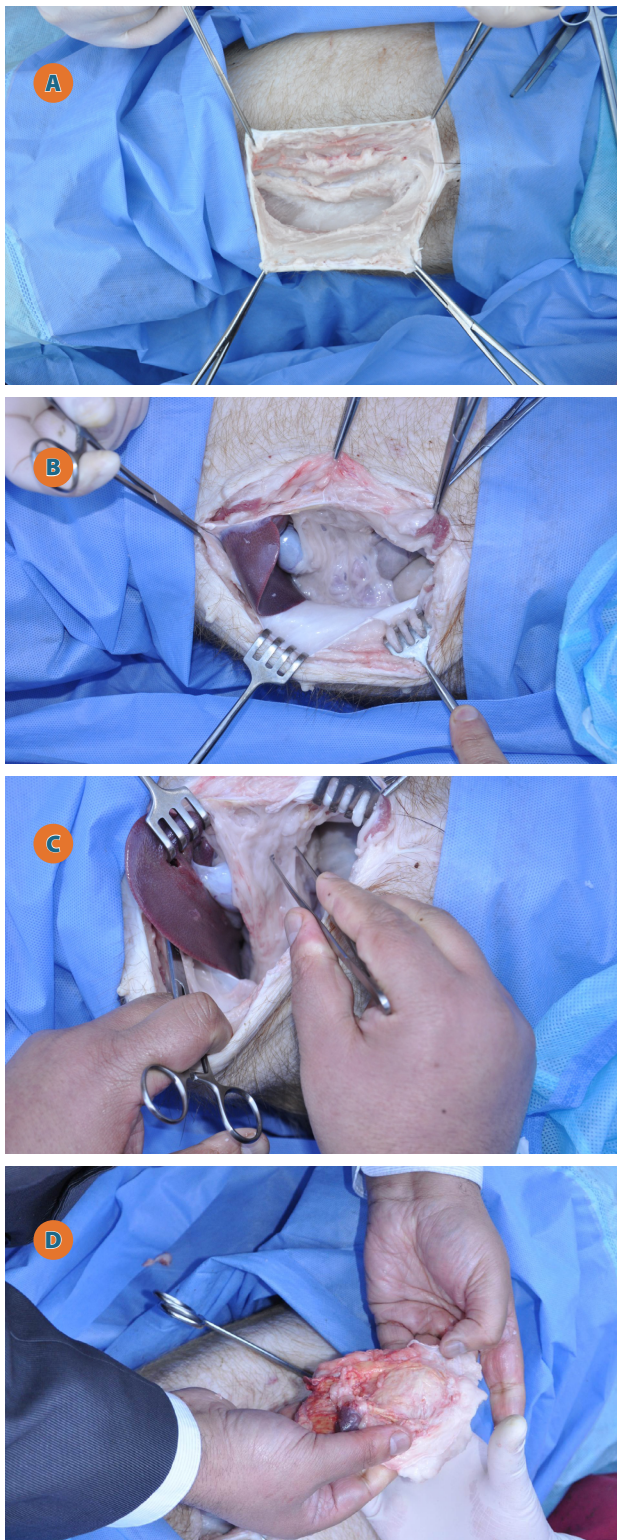
## RESULTS AND DISCUSSION

No postoperative complications or cases of ventral incisional hernia were found in the experimental animals group. In all cases, the postoperative wound scarred primarily. In the mobilization process, a dense fibrous tissue area covered with adipose tissue (fig. 2A) was detected in the abdominal wall defect region with a decellularized bovine fascia graft. Weak areas or suture line dehiscence were not found. At the abdominal cavity opening, the adherence of the omentum to the internal surface of the implant was determined (fig. 2B, C), which could easily be detached (fig. 2D). The macroscopic examination of the resected piece laterally excised within 2 cm of the suture line (fig. 3A) allowed finding a connective tissue area covered by fat tissue with musculature pretension at the periphery. The internal surface had a pale, uneven yellowish tint, in rows, with fine adhesions of the fatty tissue of the omentum (fig. 3B). In the section perpendicular to the surface, a thickness of 2.4 - 2.7 cm of the connective area could be attested (fig. 3C). The histological examination of the pieces taken at the border line between the implant and host tissues revealed a varied picture manifested by the presence of the fascia graft partially embedded in the neoformed connective tissue and in cellular-adipose tissue seconded by the presence of a polymorpho-cellular inflammatory process, with predilection a lymphocytic one with the neoformation of lymphoid pseudo-follicular structures. At the level of the connective tissue, implant calcinosis (fig. 4A) was observed, contralaterally signs of implant slipping being found, fibrotic processes being revealed in these areas, and the presence of a mature neoformed cellular connective tissue layer could be noticed (fig. 4B). At insignificant distances from the border there was found the presence of implant residues encrusted in the neoformed hypercellularized connective tissue, which contained fibroblasts, monocytic-macrophagic and symplastic elements, these being directed to the implant residues and having a significant contribution to their destruction (fig. 4C). At the level of neoformed tissue, a collagenised tissue area was observed (fig. 4D).

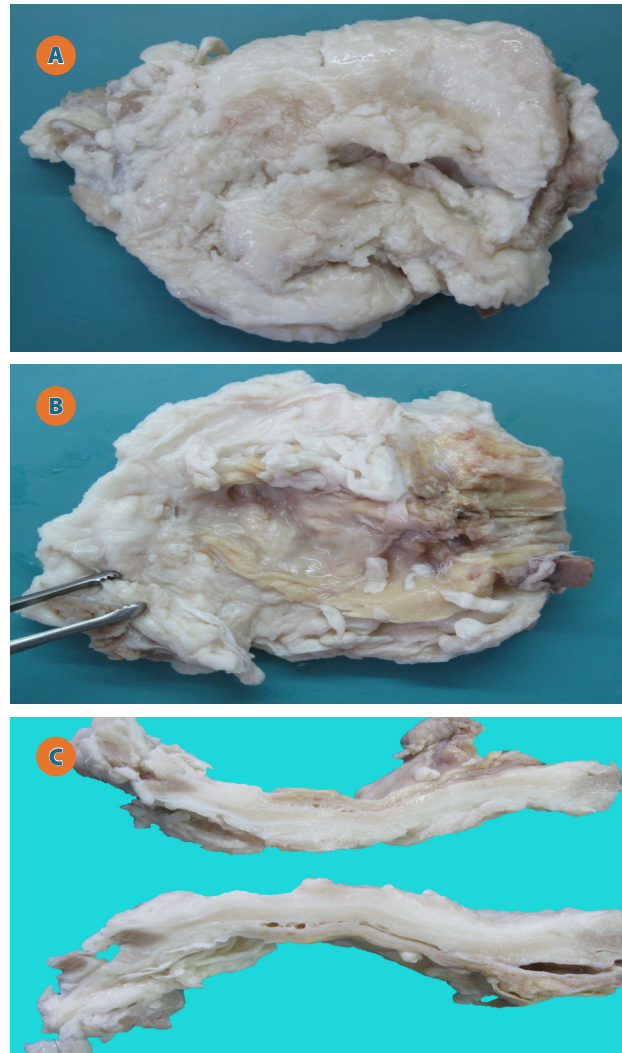
In some areas, the implant was encapsulated in the neoformed connective tissue mass, which was more fibrosing on the external surface compared to the internal areas directed to the peritoneal cavity. The winding appearance of the implant could be of-



ten observed, which may be due to the disruption of the implant in the central and eccentric areas (fig. 5A).



**Fig. 2. Macroscopic appearance of the external surface of the reconstruction abdominal wall defect area with decellularized bovine fascia graft: A - before the abdominal cavity opening; B, C - aeration of the omentum on the internal surface of the implant; D - macroscopic appearance of the internal surface of the implant after the omentum detachment**



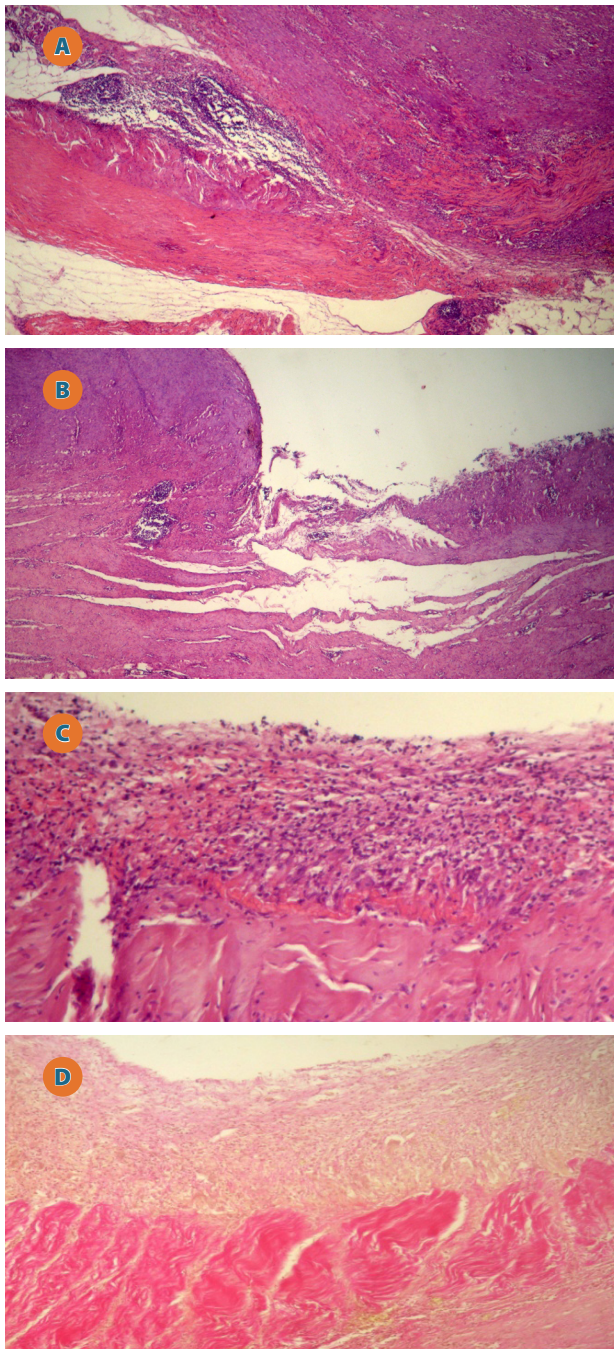
**Fig. 3. Macroscopic appearance of the external surface of the implant (A), internal surface (B) and cross-section surface (C): 1 - connective-fibrous area with graft elements; 2 - fat tissue; 3 - muscle tissue.**

In all the investigated samples, at different levels, on the implant projection in the neoformed tissue mass there were revealed implant residues attacked by the polymorphic-cellular component and polynuclear cellular symplasts, which pleads for a varied inflammatory cellular reactivity with the development of a latent and periodic fibrogenesis (fig. 5B, C, D). Adjacently, pseudofollicular and lymphoid follicular structures were present in the connective tissue area. These changes had a mosaic and chaotic appearance, including the whole area. In one case, on areas oriented towards the inner surface there were observed areas of adherence to the liver surface and implant calcinosis areas (fig. 5E).

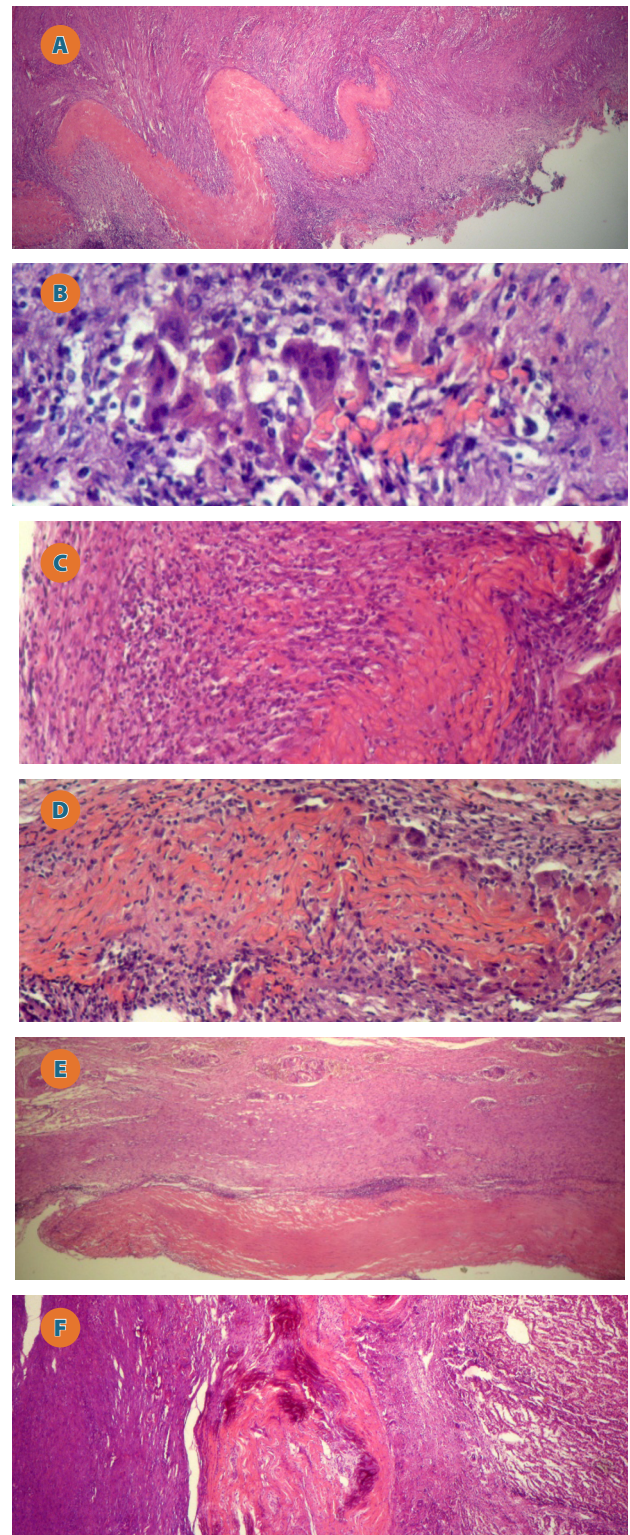
The basic role of the biomaterials used in reconstructive surgery is to provide temporary mechanical support and the development of regenerative tissue of controlled size and form [5]. Ideally, the biological material should have mechanical properties appropriate for the desired applicability, resistance to infection after implantation, it should have remodeling properties in the host tissue with mechanical and



biological properties identical to those of the missing tissue, it should have revascularization and cell infiltration properties, as well as elasticity, etc. [26].



**Fig. 4.** A - border area with the implant graft presence in the neoformed connective tissue area (1); 2 - graft sheets in the neoformed adipose tissue area; 3 - lymphoid pseudofollicular structures; B - border area with absent implant elements: 1 - neoformed connective tissue; 2 - small lymphocyte infiltrates in the neoformed tissue area; C - implant residues embedded in the neoformed connective tissue: 1 - implant residues attacked by polynuclear cellular symplasts; 2 - neoformed connective tissue with collagen fiber area; 3 - connective tissue of the peritoneal area with polymorphic cellular elements; D - external connective area with the presence of collagenized fibers (1) and internal area of neoformed connective tissue rich in cellular elements.



**Fig. 5.** A - histological appearance of the border area - an undulating implant appearance in the neoformed connective tissue area, hypercellularized by the polymorphic-cellular population; B - implant residues attacked by polymorphic-cellular macrophagal cell symplasts; C - implant residues in disjunction on account of progressive cellular polymorphic-cellular activity; D - graft residues in disjunction penetrated by fibroblasts, lymphocytes, solitary leukocytes surrounded by polymorphic-cellular cells; E - implant sheet on the peritoneal surface - granulomatous structures with giant cells in the connective tissue layer; F - implant residues between the liver capsule and the neoformed peritoneal fibrous connective tissue layer.



Several studies have found that biological implants from different sources contribute to improved tissue regeneration by revascularization, leukocyte migration and cellular repopulation, thus having a beneficial role in the abdominal wall reconstruction, theoretically minimizing the complications associated with the use of synthetic materials [2, 4].

In the literature, there are multiple reports describing the effectiveness of biological materials derived from different sources: human, swine or cattle [10, 21]. Among the biological materials of human origin, the use of human acellular dermal matrix (AlloDerm) is the most widespread option in the reconstruction of abdominal wall defects [14, 18], including congenital ones [1, 19].

Certain performances have also been found in cases of use of xenogeneic biological grafts, including: dermic swine collagen (Permacol) [9], swine intestinal submucosa matrix (Surgisis) [3], swine acellular dermal matrix [20], bovine acellular pericardium [15], acellular dermal bovine matrix, etc. [25].

In the literature, there are few studies showing the results of the use of fascia grafts as a potential biological material in reconstructive surgery, more commonly human autologous fascia lata material [6] being evaluated. Bovine fascia xenografts are not widely described as potential biological material.

There are unique experimental studies that have reported their use in the reconstruction of experimentally induced muscular and peritoneal defects, finding that this biological material has good tolerance, long resorption time, and can be used for clinical purposes [13]. In this context, the up-to-dateness of this study is undisputed.

Thus, the results of this experimental study allow us to conclude the following:

- The decellularized bovine fascia implant is characterized by a polymorphic inflammatory response, the predominance of cellular spectrum indicating the dominance of active regeneration processes with tissue remodeling and invasion of host cells, the xenogeneic implant tissues being subjected to gradual degradation and substituted by the host's neoformed connective tissue.
- The results of the experimental study justify the utility of bovine fascia acellular grafts as an alternative xenogeneic biological implant in reconstructive surgery of abdominal wall defects, this option requiring additional comparative and clinical immunological studies.

## REFERENCE

1. Alais S.M., Strauch E.D. The use of AlloDerm in the closure of a giant omphalocele. *J. Pediatr. Surg.* 2006. 41:E37-E39.
2. Beale E.W., Hoxworth R.E., Livingston E.H., Trussler A.P. The role of biologic mesh in abdominal wall reconstruction: a systematic review of the current literature. *Am. J. Surg.* 2012. 204:510-7.
3. Beres A., Christian-Lagay E.R., Romao R.L.P., Langer J.C. Evaluation of Surgisis for patch repair of abdominal wall defects in children. *J. Pediatr. Surg.* 2012. 47:917-9.
4. Caso Maestro O., Abradelo de Usera M., Justo Alonso I. et al. Porcine acellular dermal matrix for delayed abdominal wall closure after pediatric liver transplantation. *Pediatr Transplant.* 2014. 18:594-8.
5. Chena F.M., Liuc X. Advancing biomaterials of human origin for tissue engineering. *Progress in Polymer Sci.* 2016. 53:86-168.
6. Disa J.J., Klein M.H., Goldberg N.H. Advantages of autologous fascia versus synthetic patch abdominal reconstruction in experimental animal defects. *Plast. Reconstr. Surg.* 1996. 97:801-6.
7. Eberli D., Rodriguez S., Atala A., Yoo J.J. In vivo evaluation of acellular human dermis for abdominal wall repair. *J. Biomed. Mater. Res.* 2010. 93A:1527-38.
8. Harris H.W. Clinical outcomes of biologic mesh: Where do we stand? *Surg. Clin. N. Am.* 2013. 93:1217-25.
9. Hsu P.W., Salgado C.J., Kent K. et al. Evaluation of porcine dermal collagen (Permacol) used in abdominal wall reconstruction. *J. Plast. Reconstr. Aest. Surg.* 2009. 62:1484-9.
10. Iacco A., Aeyemo A., Riggs T., Janczyk R. Single institutional experience using biological mesh for abdominal wall reconstruction. *Am. J. Surg.* 2014. 208:480-4.
11. Jiang W., Zhang J., Lv X. et al. Use of small intestinal submucosal and acellular dermal matrix grafts in giant omphalocele in neonates and a rabbit abdominal wall defect model. *J. Pediatr. Surg.* 2016. 51:368-73.
12. Keane T.J., Badylak S.F. The host response to allogeneic and xenogeneic biological scaffold materials. *J. Tissue Eng. Regen. Med.* 2015. 9:504-11.
13. Komender A., Lesiak-Cyganowska E. Some biological properties of bovine trypsinized fascia xenografts. *Arch. Immunol. Ther. Exp. (Warsz)*. 1981. 29(4):485-9.
14. Lee E.I., Chike-Obi C.J., Gonzalez P. et al. Abdominal wall repair using human acellular dermal matrix: a follow-up study. *Am. J. Surg.* 2009. 198:650-7.
15. Limpert J.N., Desai A.R., Kumpf A.L. et al. Repair of abdominal wall defects with bovine pericardium. *Am. J. Surg.* 2009. 198:e60-e65.
16. Luo X., Kulig K.M., Finkelstein E.B. et al. In vitro evaluation of decellularized ECM-derived surgical scaffold biomaterials. *J. Biomed. Mater. Res. Part B.* 2017. 105B:585-93.
17. Ma J, Sahoo S, Baker AR, Derwin KA. 2015. Investigating muscle regeneration with a dermis/small intestinal submucosa scaffold in a rat full-thickness abdominal wall defect model. *J Biomed Mater Res Part B* 2015;103B:355-364.
18. Maurice S.M., Skeete D.A. Use of human acellular dermal matrix for abdominal wall reconstruction. *Am. J. Surg.* 2009. 197:35-42.
19. Sawyer A.C., Bailey K.A., Cameron B.H. The use of AlloDerm for a giant omphalocele with a ruptured sac and inadequate skin coverage. *J. Pediatr. Surg. Case Rep.* 2013. 1:267-9.
20. Siy R.W., Pferdehirt R.E., Izaddoost S.A. Non-crosslinked porcine acellular dermal matrix in pediatric abdominal wall reconstruction: a case series. *J. Pediatr. Surg.* 2017. 52:639-43.
21. Smart N.J., Bryan N., Hunt J.A. A scientific evidence for the efficacy of biologic implants for soft tissue reconstruction. *Assoc. Colopr. Gr. Brit. Irel.* 2012. 14(Suppl. 3):1-6.
22. Takanari K., Hong Y., Hashizume R. Et al. Abdominal wall reconstruction by a regionally distinct biocomposite of extracellular matrix digest and a biodegradable elastomer. *J. Tissue Eng. Regen. Med.* 2016. 10:748-61.
23. Todros S., Pavan P.G., Natali A.N. Synthetic surgical meshes used in abdominal wall surgery: Part I—materials and structural conformation. *J. Biomed. Mater. Res. Part B.* 2017. 105B:689-99.
24. Wang L., Johnson J.A., Chang D.W., Zhang Q. Decellularized musculo-fascial extracellular matrix for tissue engineering. *Biomaterials.* 2013. 34(11):2641-54.
25. Wietfeldt E.D., Hassan I., Rakin J. Utilization of bovine acellular dermal matrix for abdominal wall reconstruction: a retrospective case serie. *Ost. Wound Manag.* 2009. 55(8):52-6.
26. Zhang J., Wang G.Y., Xiao Y.P. et al. The biomechanical behavior and host response to porcine-derived small intestine submucosa, pericardium and dermal matrix acellular grafts in a rat abdominal defect model. *Biomaterials.* 2011. 32:7086-95.
27. Zhong T., Janis J.E., Ahmad J., Hofer S.O.P. Outcomes after abdominal wall reconstruction using acellular dermal matrix: a systematic review. *J. Plast. Reconstr. Sbesth. Surg.* 2011. 64:1562-71.