

## Types of extracranial branching of the facial nerve

Angela Babuci, MD, Assistant Professor

Department of Human Anatomy, Nicolae Testemitsanu State University of Medicine and Pharmacy  
Chisinau, the Republic of Moldova

Corresponding author: angela.babuci@usmf.md

Manuscript received January 28, 2019; revised manuscript March 04, 2019

### Abstract

**Background:** Interest in anatomical variability and individual specific features of the extracranial branches of the facial nerve, taking into consideration that nowadays, people are so concerned about their physical look, the knowledge of facial nerve peripheral branching is of high clinical significance. Even, if it is hardly difficult to discover something new, or unusual at the macromicroscopic level, we believe that reading this paper oncologists and oromaxillofacial surgeons will be surprised by anatomical variations of the peripheral branches of the facial nerve.

**Material and methods:** Our research project was carried out on 52 cadaveric semiheads that previously were fixed in 10% formalin solution: 36 male and 16 female; 25 of those samples were right and 27 left side semiheads. The bilateral pattern of dissection was carried out on 30 semiheads and unilateral dissection – on 22 semiheads. The dissected samples were photographed. Some samples were marked out with black papers for better contrast.

**Results:** The facial trunk on its exit from the stylomastoid foramen was descendent in 32 cases (61.54%), in 9 cases (17.3%) it ran horizontally and in 5 cases (9.62%) it had an ascending course, but in 6 cases (11.54%) the branches derived directly from the trunk in a fan-like fashion. According to the known classification of the facial nerve peripheral branching, the following percentage for each type was established: Type I (23.1%); Type II (7.7%); Type III (1.9%); Type IV (38.5%); Type V (7.7%); Type VI (9.7%). Few intermediate types have been marked out such as: Type II-III (3.8%); Type III-IV (3.8%), Type V-VI (3.8%). When dissecting the facial nerve we observed that the trunk in 37 cases divided into two primary branches and in 15 cases there were marked out diffuse types of branching.

**Conclusions:** A significant characteristics of the facial nerve is its variability and individual specific features. Among the well known classified types of peripheral branching of the facial nerve, there are intermediate types of its extracranial divisions.

**Key words:** facial nerve, trunk, landmarks, variability.

### Introduction

Why we are so interested in reviewing the morphological peculiarities of the extracranial branches of the facial nerve, nowadays, when the modern medicine has the capacity to diagnose various impairments of the nervous system, including those of the facial nerve, using high technology methods of examination?

Of course, apparently, all the anatomical structures are well known and it is very difficult to discover something new, or unusual at the macromicroscopic level, but at the same time anatomy is an amazing science, that sometimes surprises us by its variability. According to our study, morphology may be rediscovered and new data can be supplied to the anatomical background.

Why facial nerve? It is a simple question, but the substrate of this question is deeply hidden inside the human body and it depends on individual character. Lately, too many people complain of physical and psychological exhaustion and the number of those with chronic fatigue syndrome, characterized by extreme tiredness prevalence, is daily increasing.

When reading this paper, a question will arise in the reader's mind, what does the facial nerve have in common with the extreme tiredness? At a glance, there is nothing in common, but considering that tiredness and unhappiness will lead to the formation of specific facial wrinkles and corresponding physiognomy, as well as the fact that people

of the 21<sup>st</sup> century are very concerned about their intellectual development, that should not be neglected, regards the physical aspect of an individual.

Unfortunately, our daily activity is accompanied by stress, environmental pollution, improper nutrition, exposure to various harmful factors, and one of the most substantial facts is related to the genetic changes of the bacterial flora and viruses, that are increasingly affecting central and peripheral nervous system. Taking into consideration that the facial nerve is highly susceptible to various harmful factors, we decided to review its morphology through applied anatomy.

### Material and methods

Our study is a descriptive and retrospective one and according to international requirements for carrying out a research project on cadaveric material, it was approved by the Ethics Committee of Nicolae Testemitsanu State University of Medicine and Pharmacy of the Republic of Moldova.

The study was carried out on 52 adult semiheads, dissected at the Department of Human Anatomy of the named University.

The bilateral pattern of dissection was carried out on 30 semiheads and unilateral dissection was performed on 22 semiheads. For the fixation of the cadaveric material 10% formalin solution was used and the classic dissection method was applied.

As the purpose of our study was to establish the variants of branching of the extracranial part of the facial nerve, an incision of the skin of the median plan of the forehead, which continued on each side of the face around the eye, nose and lips to the end on the midline of the chin, was made. The skin of the face was removed and the landmarks of the facial nerve have been marked out. As soft tissue landmarks the posterior belly of the digastrics muscle and the stylomastoid artery were used and as bony landmarks we used the mastoid and styloid processes, the zygomatic arch, the posterior margin of the *ramus mandibulae*, the mandibular angle and mandibular margin [1, 2].

After identification of the facial nerve trunk the primary, secondary, tertiary and terminal branches of the facial nerve were dissected. The anatomical samples were examined and photographed. Some of them were marked out with black paper for better contrast. The obtained data were statistically processed.

### Results

According to our dissecting practice, the most safety way to avoid the microtraumas of the facial nerve branches in surgery is to mark out at first the trunk of the nerve at its exit orifice, using as a landmark the mastoid process, posterior belly of the digastric muscles, stylomastoid artery and the posterior margin of the *ramus mandibulae*.

Another significant issue that should be kept in mind regards the trajectory of the facial trunk, when it exits the *Fallopian canal*. Along with descending course of the trunk, in the current study there were pointed out horizontal and even ascending pathways of the facial nerve trunk when it leaves the *Fallopian canal*. From the total number of samples, the facial trunk on its exit from the stylomastoid foramen was descendent in 32 cases (61.54%), in 9 cases (17.3%) it ran horizontally, in 5 cases (9.62%) it had an ascending course, but in 6 cases (11.54%) the branches derived directly from the trunk in a fan-like fashion.

Examining the dissected semiheads we tried to classify the sample according to known types described by specialty reference sources [3, 4].

When dissecting the facial nerve we observed that the trunk in 37 cases divided into two primary braches and in 15 cases there were marked out diffuse types of branching.

It was necessary to find out why it happens so that for some people are characteristic a lot of thin divisions of the facial nerve and various connections were formed between its branches and with the regional cranial nerves, but in other cases there were not so many secondary and tertiary divisions, but very few.

When examining the right and left sides of the face on the same individuals we came upon the conclusion that on the right side of the majority of samples the branching and the connections were more obvious and abundant, but on the left one, the divisions and connections of the primary branches were not so numerous.

Among the dissected samples, even in those cases when

both semiheads belong to the same individual the divisions of the extracranial branches were different on each side of the face [5].

There barely could be found two, more or less, similar extracranial branching of the facial nerve, but nevertheless, all the dissected samples were classified according to known types of peripheral divisions of the facial nerve. An interesting issue concerning extracranial divisions of the facial nerve, that is worth mentioning, was that among the dissected samples there were identified some intermediate types of facial nerve branching.

The following types have been pointed out in our study and the percentage for each type was established: Type I (23.1%); Type II (7.7%); Type III (1.9%); Type IV (38.5%); Type V (7.7%); Type VI (9.7%) and the following intermediate types: Type II-III (3.8%); Type III-IV (3.8%), Type V-VI (3.8%). Some types of the extracranial part of the facial nerve divisions established during the study are presented in fig. 1, 2, 3 and 4 on page 44.

### Discussion

The ethiogenesis of the peripheral facial nerve paralysis is controversial and highly diverse. Nevertheless, one factor that must be kept in mind by neurologists, and especially by neurosurgeons and oromaxillofacial surgeons, is the morphology of the facial nerve. Its motor branches have a superficial location on the face and they are highly susceptible to various injures of the face and to microtraumas in facial surgery such as parotid ablation, rejuvenating procedures, aesthetic surgery and other manipulations on the facial region.

The facial nerve is involved in pathology of other cranial nerves, but mainly in pathology of the vestibulochochlear one. The traumas of the head and neck, somatic diseases and metabolic disorders and a wide range of viruses, bacteria are the cause of facial nerve impairments [6, 7, 8].

The morphological and topographical peculiarities of the facial nerve, its relations to the regional anatomical structures and connections of its extracranial branches [5] with other cranial nerves, might be an explanation of the facial nerve involvement in different pathology.

It should be mentioned that in aesthetic surgery the most susceptible to iatrogenic injures are the branches of the temporal and frontal area, due to the fact that those branches are not so much ramified and few connections are characteristic for those branches. The high risk of frontotemporal branch lesion in facelift was pointed out by [9], and explanation was given by [10], who mentioned that the precise localization of the frontal division of the facial nerve is still problematic, for there were not established high fidelity landmarks that can be used for that purpose and [10] proposed to consider as landmarks the veins of the temporofrontal area.

For facial nerve is characteristic a high degree of variability [11] and that fact was marked out as well in all our samples. An important fact that is worth mentioning is that the variability of the extracranial branches of the facial nerve does not refer to different people only, but even in the

same individual the variability was highly marked out. In our study there barely could be found two more or less similar divisions of the facial nerve and that peculiarity should be considered by surgeons. Another significant moment that should be kept in mind in surgery is that prediction of the course and divisions of the facial nerve, even, if there was carried out a surgery on one side of the face, cannot be applied on the opposite side.

High risk of iatrogenic lesions of the extracranial branches of the facial nerve can be explained by multiple variations of its branches that may be accidentally damaged in facial surgery, being one of the main causes of failure in parotid tumor ablation and other surgery of the facial region that may result in transitory peripheral facial paralysis. According to [12, 13, 14] the tight relationship between the facial nerve and the parotid gland is another high risk factor of iatrogenic microtraumas in parotid tumors surgery.

Another interesting fact was discovered regarding divisions of the marginal mandibular and cervical branches. It is known that the upper two thirds of the face receive corticonuclear pathways from both cerebral hemispheres, but the lower third from the contralateral side only. So, we tried to understand why in some cases the named above branches of the facial nerve give off a lot of secondary and tertiary divisions, but in other cases they run up to the innervated muscles almost without divisions. May be it depends on individual person's character and mimicry.

We leave this question open for future study. Some interesting things were found out in our study and as it was mentioned above anatomy is an amazing subject, but the facial nerve in our opinion is the most amazing and unpredictable cranial nerve.

### Conclusions

Our study revealed a high variability of the extracranial branches of the facial nerve and we came to the conclusion that theoretically we can classify the types of facial nerve branching, but our results should be carefully used by practitioners, because the facial nerve is one of the most subjected to individual specific features, cranial nerve.

We can conclude that there barely could be found two samples with more or less similar extracranial branching of the facial nerve.

When examining the right and left sides of the face on the same individuals, we came to the conclusion that on the right side of the majority of samples the branching and the connections were more obvious and abundant, but on

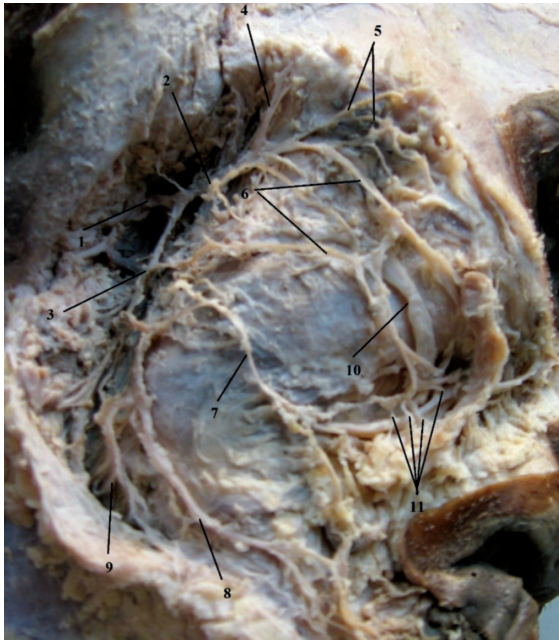the left one, the divisions and connections of the primary branches were not so numerous.

Knowledge of types of branching of the extracranial part of the facial nerve is of clinical significance and should be kept in mind in parotid ablation, OMF surgery and in aesthetic surgery. A surgeon should always be aware that one of the characteristics of the seventh pair of cranial nerves is a high variability and of its extracranial branches that finally will determine the success or the failure of a facial surgery.

### References

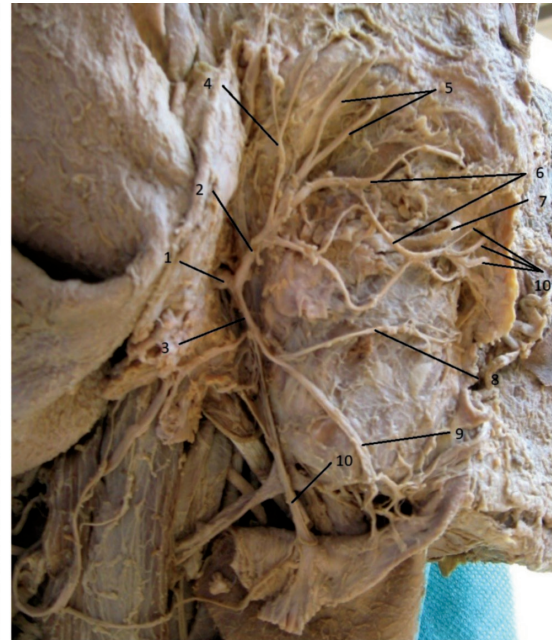1. Davies JC, Agur AMR, Fattah AY. Anatomic landmarks for localization of the branches of the facial nerve. *OA Anatomy*. 2013;1(4):33.
2. Saylam C, Ucerler H, Orhan M, Ozek C. Anatomic landmarks of the buccal branches of the facial nerve. *Surg Radiol Anat*. 2006;28(5):462-7.
3. Standring S, editor. *Gray's anatomy: the anatomical basis of clinical practice*. 40th ed. Edinburgh: Churchill Livingstone/Elsevier; 2008. ISBN: 978-0-443-06684-9, ISBN: 978-0-8089-2371-8 (International ed.). p. 495.
4. Bergman RA, Afifi AK, Miyauchi R. *Illustrated encyclopedia of human anatomic variation: Opus III: Nervous system variations in branching of facial nerve* [cited 2019 Jan 28]. Available from: <http://www.anatomyatlases.org>.
5. Babuci A. Variations of connections of the parotid plexus branches: a cadaveric study. *Mold J Health Sciences*. 2015;5(3):21-26.
6. Gherman D, Moldovanu I, Zapuhliu G. *Neurologie și neurochirurgie [Neurology and neurosurgery]*. Chisinau: Medicina; 2003. 528 p. Romanian.
7. Volk GF, Pantel M, Guntinas-Lichius O. Modern concepts in facial nerve reconstruction. *Head Face Med*. 2010;6:25. doi: 10.1186/1746-160X-6-25.
8. Gavriluc M. *Examenul neurologic [Neurological examination]*. Chișinău; 2012. p. 31-38. Romanian.
9. Friel MT, Shaw RE, Trovato MJ, Owsley JQ. The measures of face-lift patients satisfaction: the Owsley Facelift Satisfaction Survey with a long-term follow-up study. *Plast Reconstr Surg*. 2010;126(1):245-257.
10. Sabini P, Wayne I, Quatela VC. Anatomical guides to precisely localize the frontal branch of the facial nerve. *Arch Facial Plast Surg*. 2003;5:150-152.
11. Baker DC, Conley J. Avoiding facial nerve injuries in rhytidectomy. *Plast Reconstr Surg*. 1979;64(6):781-785.
12. Ataman T, Mîrșu C. Descoperirea nervului facial în porțiunea mastoidă [Disclosure of the facial nerve in the mastoid portion]. *O.R.L. [Otorhinolaryngology]*. 1998;1-2:66-68. Romanian.
13. Cristea D, Maftei O, Debita M, Firescu D. Disecția nervului facial în spațiile profunde ale feței. Manevră anatomo-chirurgicală obligatorie în patologia cervico-parotidiană [Dissection of the facial nerve in the deep spaces of the face. Mandatory maneuver in Surgical Anatomy of the cervico-parotid pathology]. *Revista Română de Anatomie funcțională și clinică, macro- și microscopică și de Antropologie [The Romanian Journal of Functional and Clinical Anatomy, Macro- and Microscopic and Anthropology]*. 2004;3(3):26-30. Romanian.
14. Kirici I, Kilic C, Kazkayasi M. Topographic anatomy of the peripheral branches of the facial nerve. *J Exp Integr Med*. 2011;1(3):201-204.





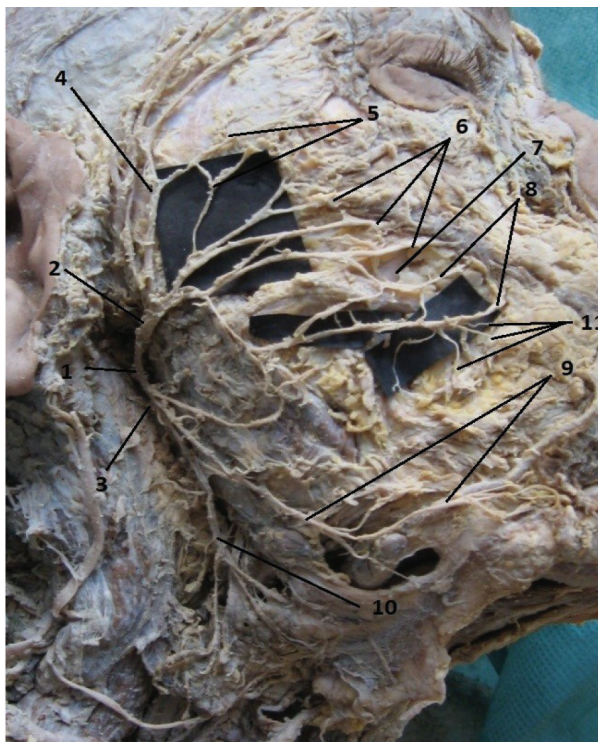**Fig. 1. Atypical branching of the extracranial part of the facial nerve. Type II.**

1 – the main trunk of the facial nerve; 2 – temporofacial branch; 3 – cervicofacial branch; 4 – temporal branches; 5 – zygomatic branches; 6 – superior buccal branches; 7 – inferior buccal branch; 8 – marginal mandibular branch; 9 – cervical branch; 10 – parotid duct; 11 – terminal branches within the muscles of facial expression.



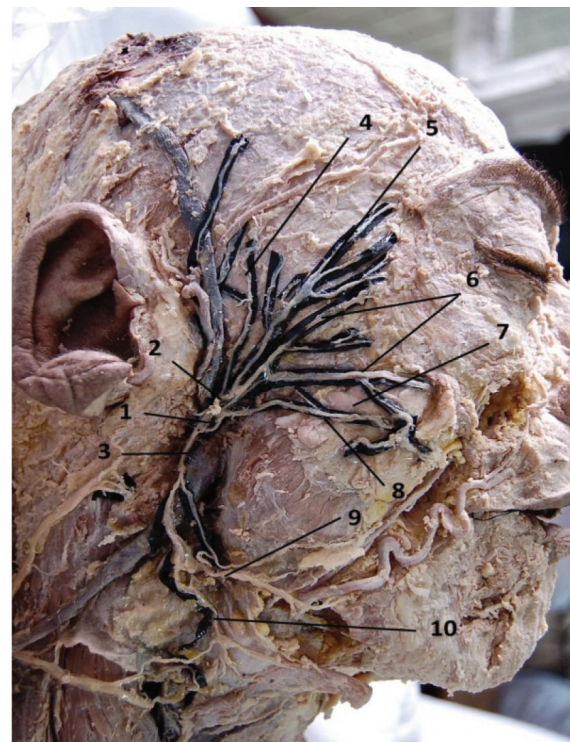
**Fig. 2. Atypical branching of the extracranial part of the facial nerve. Type IV**

1 – the main trunk of the facial nerve; 2 – temporofacial branch; 3 – cervicofacial branch; 4 – temporal branches; 5 – zygomatic branches; 6 – superior buccal branches; 7 – parotid duct; 8 – inferior buccal branch; 9 – marginal mandibular branch; 10 – cervical branch; 11 – terminal branches within the muscles of facial expression.



**Fig. 3. Branching of the extracranial part of the facial nerve. Intermediate Type V-VI.**

1 – the main trunk of the facial nerve; 2 – temporofacial branch; 3 – cervicofacial branch; 4 – temporal branches; 5 – zygomatic branches; 6 – superior buccal branches; 7 – parotid duct; 8 – inferior buccal branch; 9 – marginal mandibular branch; 10 – cervical branch; 11 – terminal branches within the muscles of facial expression.



**Fig. 4. Divisions of the extracranial part of the facial nerve. Type V.**

1 – the main trunk of the facial nerve; 2 – temporofacial branch; 3 – cervicofacial branch; 4 – temporal branches; 5 – zygomatic branches; 6 – superior buccal branches; 7 – parotid duct; 8 – inferior buccal branch; 9 – marginal mandibular branch; 10 – cervical branch; 11 – terminal branches within the muscles of facial expression.