

STUDII CLINICO-ȘTIINȚIFICE

Peripheral Neuropathy in Multiple Sclerosis: A Clinical and Electrophysiological Study

V. Lisnic¹, M. Gavriliuc², O. Odainic², O. Misić², V. Nemțan³

¹Nicolae Testemitanu State Medical and Pharmaceutical University

²Institute of Neurology and Neurosurgery

³Medical and Sanitary Department of the Information and Security Service

Neuropatia periferică în scleroza multiplă – aspecte clinice și electrofiziologice

La un lot de 50 de pacienți, cu scleroză multiplă clinic și imagistic definită, au fost studiate manifestările clinice și electrofiziologice de afectare a fibrelor nervilor periferici. Deși semnele clinice de neuropatie la acești pacienți se determină doar ocazional, examenul de stimulodectecție frecvent (în 28% din cazuri) pune în evidență existența subclinică a unei neuropatii periferice, manifestate prin diminuarea vitezei de conducere, majorarea latenței distale și latenței răspunsurilor tardive (undeii-F). Procesul patologic în cadrul sclerozei multiple nu se limitează la demielinizarea fibrelor sistemului nervos central, dar se extinde și la radiculele nervoase, fibrele motorii și sensorii ale nervilor periferici.

Cuvinte-cheie: scleroza multiplă, demielinizare, neuropatie, electrofiziologie.

Периферическая невропатия при рассеянном склерозе. Клинические и электрофизиологические аспекты

В группе из 50 больных рассеянным склерозом были исследованы клинические и электрофизиологические проявления поражения волокон периферических нервов. Несмотря на то, что у этих больных клинические признаки neuropatii определяются лишь изредка, при исследовании проведения нервных импульсов выявлено частое (в 28% случаях) доклиническое проявление периферической neuropatii, проявляющейся снижением скорости проведения, увеличением дистальной латентности и латентности поздних ответов (F-волны). Патологический процесс при рассеянном склерозе не ограничивается демиелинизацией волокон центральной нервной системы, он распространяется и на нервные корешки спинного мозга и на двигательные и чувствительные волокна периферических нервов.

Ключевые слова: рассеянный склероз, демиелинизация, neuropatia, электрофизиология.

Introduction

Multiple sclerosis (MS) is a demyelinating disease of the central nervous system (CNS). The majority of the white matter lesions are localized in the periventricular region and at the level of junction between white and gray brain matter. MS is the main cause of disability in young adults. There are approximately 1, 1 – 2, 5 million patients of MS in the world. Annually, there are registered about 10.000 new cases.

Although MS has classically been considered a CNS demyelinating disease, there have been occasional reports of peripheral nervous system (PNS) involvement. Both peripheral neuropathy [6] and radiculopathy [8] have been reported in MS patients. Subclinical pathologic [3] and electrophysiologic [7] abnormalities have also been reported in association with MS. Even though these associations are well documented, the frequency of neuropathy in MS patients has not been clearly defined. On the other hand, central demyelinating lesions have been seen by means of magnetic resonance imaging (MRI) and evoked potentials in some patients with chronic inflammatory demyelinating polyradiculoneuropathy [2, 8].

The goal of this study was to establish the clinical and electrophysiological peculiarities of PNS involvement in cases of MS.

Material and methods

There were 50 patients examined, diagnosed with definite MS according to the McDonald criteria. The age of the patients varied between 15 and 49 years (mean age 33, 4 years). Each case was documented by means of MRI examination. Patients with diseases that can develop neuropathy, such as diabetes mellitus, thyroid pathology, renal and hepatic failure, and alcohol abuse were excluded from the study. Excluded as well, were patients with a possible mechanical nerve compression.

Recurrent remissive evolution of MS was established in 33 patients (66% of cases). In the other 17 patients (34% of cases), primary progressive form was revealed. The EDSS/Kurtzke score varied between 2, 0 and 6, 5 (mean value – 4, 42).

Nerve conduction studies were performed in the fibers of medianus, ulnaris, radialis, peroneus communis, tibialis and suralis nerves. Studied were the distal latencies, nerve conduction velocities in the motor and sensory fibers, amplitude of the compound muscle action potential, and amplitude of the sensory potentials and latency of the F-waves.

Results

The clinical manifestations and electrophysiological pattern of the peripheral neuropathy was studied in MS pa-

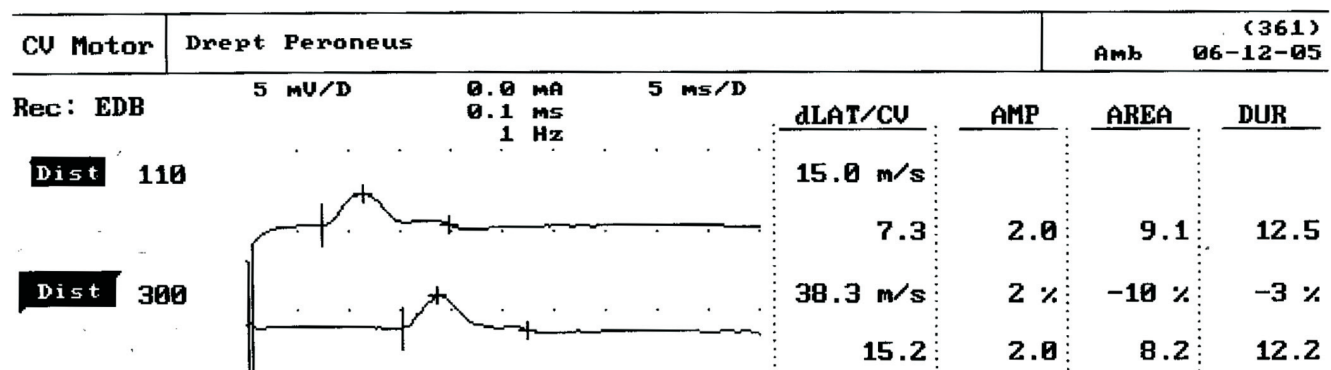


Fig.1. Nerve conduction studies in the motor fibers of the peroneus communis nerve. Specific signs for demyelinating neuropathy – significant increase of the distal latency (7,3 ms), and decrease of the motor conduction velocity – 38,3 m/s.

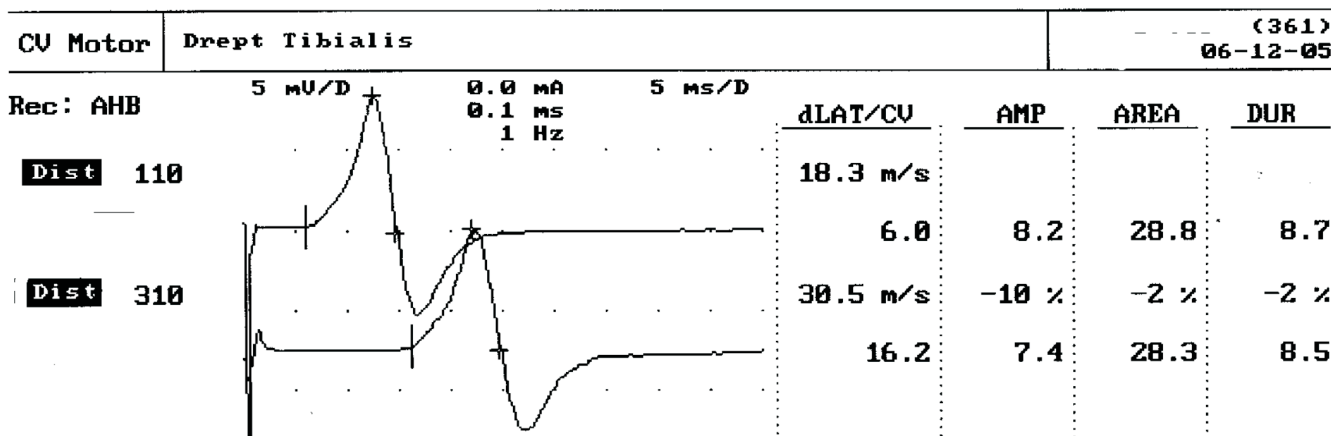


Fig. 2. Nerve conduction studies in the motor fibers of the tibialis nerve. Specific signs for demyelinating neuropathy – increase of the distal latency (6,0 ms), and significant decrease of the motor conduction velocity – 30,5 m/s.

tients by evaluation of neuropathic symptoms and signs, and electrophysiological studies. The patients with sensory and motor complaints had mild symptoms and signs suggestive of neuropathy.

Clinical signs of PNS impairment were established in 6 patients (12% of cases). They consisted in the diminishing of ankle reflexes, sensory disturbances in „socks” and „gloves” distribution, and signs of sensory ataxia.

There was no significant correlation between any of the clinical variables of MS with the occurrence of neuropathy.

Electrophysiological signs of subclinical damage of the peripheral nerves were detected rather more often. Modifications justifying the polyneuropathy were established in 14 patients (28% of cases). They consisted in a statistically significant prolongation of the distal latencies, reduction of the motor and sensory nerve conduction velocities, and prolongation of the latencies of the F waves in at least 3-6 of nerves examined.

A typical finding of nerve conduction in a patient with PNS involvement in MS is presented in figs. 1 and 2.

Discussions

Peripheral neuropathy in combination with MS was documented by several authors and it remains unclear if they are part of the same entity or coincidental findings. Pollock et al. [5] performed sural nerve biopsy on 10 MS

patients without any clinical evidence of peripheral neuropathy. Surprisingly, normal conduction studies in the fibers of the sural nerve find a high frequency of abnormal teased fibers and significant reduction of the myelin thickness, suggesting that peripheral myelin may be also involved in MS. Lassman et al. [3] showed abnormal autopsy findings consisting in widespread demyelination and inflammatory cells in the nerve roots of a patient with MS without discovering any clinical and neurophysiological evidence of peripheral nerve involvement. Hasson et al. observed slight to severe demyelination of the peripheral nerves in 12 out of 20 autopsied MS patients, but considered that they were related to malnutrition and avitaminosis. Conrad and Bechinger reported mild slowing with prolonged distal latencies in a portion of patients with MS upon performing nerve conduction studies. Sarova-Pinhas et al. [7] registered electrophysiological abnormalities in 10 out of 22 mildly disabled MS patients. In a study performed by Marchioni et al. [4] of 60 adults with postinfectious central nervous system demyelinating disease, 44% of the patients exhibited simultaneous PNS involvement in the form of polyradiculoneuropathy (clinically obvious in 38% of them).

In our study, we revealed clinical signs of neuropathy in 6 patients (12% of cases) out of 50 studied, with electrophysiological abnormalities of nerve conduction suggesting a demyelinating neuropathy in 14 patients (28% of cases).

It has been postulated that peripheral nerve involvement in MS may be associated with advanced disease and immobilization [5]. But other researchers did not find such an association, despite their ability to review the clinical course longitudinally. Furthermore, in 2 patients peripheral neuropathy was the initial manifestation. The occurrence of radiculopathy has been explained on the basis of junctional (root entry zone) lesions or plaques. This mechanism, however, could not explain the occurrence of peripheral neuropathy. In the CNS demyelinating animal model, chronic relapsing of experimental allergic encephalomyelitis and peripheral nerve demyelination is also known to occur. Recent studies suggest that common antigens are shared by both peripheral and central myelin. One such antigen that has recently been identified is myelin-associated glycoprotein. Antigenic cross-reactivity between CNS and PNS myelin proteins or multiple antigens (some not yet identified) may elicit similar immune responses, producing demyelination. Alternatively, MS patients with PNS involvement may represent a clinical subset sharing a common alteration of the immune response to peripheral and central myelin antigens.

On the other hand, Thomas et al. [9] examined 6 patients with CIDP associated with multifocal CNS demyelination. Recently, Sharma et al. [8] described 5 patients with CIDP associated with MS.

We consider that the inflammatory diseases that affect myelin of the PNS and CNS could be considered within a spectrum in relation with the pole of the spectrum which is predominantly affected. In the majority of cases, the pathological process is localized at one of the poles of the spectrum, but there also exist cases in which the myelin of both CNS and PNS suffers. One of the poles of the spectrum is occupied by MS, in which demyelination occurs mainly at the level of the CNS. Rarely in cases of MS are there clinical signs of PNS damage, but the subclinical signs of such a process are established rather more frequently.

There were studies published about combined central and peripheral nervous system demyelination. Adamovic et al. [1] observed over a 13-year period, 13 patients of the pediatric population with severe acute combined central and peripheral nervous system demyelination. They found this to account for 14% of children with acute acquired demyelination. Most presented itself during the winter, with both constitutional and neurologic signs present at admission. The onset of neurologic disturbance was preceded by an infectious prodrome in 84.6% of cases. However, the suspected infectious agent could only be identified in 38.5% of patients. Similarly to patients with classic acute disseminated encephalomyelitis, the patients with combined central and peripheral nervous system demyelization manifested a wide variability of multifocal neurologic deficits, mostly exhibiting signs of encephalopathy or spinal cord dysfunction. The authors found poor neurologic evolution and a final outcome of 7 (54%) patients with acute combined central and peripheral nervous system demyelization. Classic acute disseminated encephalomyelitis is typically a disease characterized by a good evolution and excellent neurologic outcome. Cases with residual neurologic and cognitive deficit, or even death, are

rarely observed. The same applies to Guillain-Barré syndrome. A pediatric study on transverse myelitis demonstrated an overall poor outcome, with 40% of children permanently wheelchair-dependent as a result of the disease. The authors concluded that the optimal therapeutic options for acute combined central and peripheral nervous system demyelization are still uncertain, and the question of which treatment to use first (corticosteroids, intravenous gammaglobulins) remains unanswered.

The prevalence of acute combined central and peripheral nervous system demyelization was probably underestimated, because most of the patients with acute isolated CNS and acute isolated PNS demyelization were not systematically evaluated for possible associated involvement (magnetic resonance imaging and/or nerve conduction studies). Some patients with mild involvement were possibly overlooked because these investigations were not undertaken.

Acute combined central and peripheral nervous system demyelization is not as rare as previously thought. Although isolated CNS or PNS demyelization usually portends a good prognosis, the combination of these two diseases may have, in some patients, a poorer prognosis. Systematic assessment of this entity, using MRI and EMG/NCS is important. Further studies are necessary to clarify its incidence, risk factors, potential etiologies, optimal management, and prognosis.

The occurrence of both CNS and PNS demyelization raises the question of common pathogenetic mechanisms and may represent a unique disorder with a distinct pathogenesis. Peripheral myelin P1 protein is shared by both peripheral and central myelin. Based on animal studies and studies in humans [10] there are clear parallels, both clinical and histopathological, between the events in experimental allergic neuritis and experimental allergic encephalomyelitis where combined PNS and CNS demyelization may occur. Therefore it is possible that the initial autoimmune response to myelin basic protein or myelin P1 might have increased the damage to the primary antigens site in peripheral or CNS by exposing other antigenic epitopes in myelin antigens. Probably during an autoimmune process directed against such epitopes in central or peripheral myelin, the autoimmune-mediated demyelization could extend from the CNS to PNS and present itself as demyelinating disease of the CNS (MS) and PNS (CIDP).

Conclusions

PNS involvement in MS may be more frequent than is generally assumed. Often only subclinical (electrophysiological) signs can be established. Nerve conduction studies estimate the degree of PNS involvement in MS patients. Patients with both peripheral and central demyelization may represent a subpopulation in which further studies might identify specific antigens of pathophysiological significance.

References

1. Adamovic T, Riou E.M., Bernard G., Acute Combined Central and Peripheral Nervous System Demyelination in Children. *Pediatr. Neurol.*, 2008; 39: 307 – 316.
2. Comi G., Locatelli T., Leocani L. et al. Can Evoked Potentials be Useful in monitoring Multiple Sclerosis Evolution? *Electroencephalogr. Clin. Neurophysiol. Suppl.*, 1999; 50: 349–57.

3. Lassman H., Budka H., Schnaberth G. Inflammatory Demyelinating Polyradiculitis in a Patient with MS. Arch. Neurol., 1981; 38: 99-102.
4. Marchioni E., Ravaglia S., Piccolo G., et al. Postinfectious Inflammatory Disorders: Subgroups Based on Prospective Follow-Up. Neurology, 2005; 65: 1057 – 1065.
5. Pollock M., Calder C., Allpress S. Peripheral Nerve Abnormality in Multiple Sclerosis. Ann. Neurol., 1977; 2: 41-48.
6. Pogorzelski R., Baniukiewicz E., Drozdowski W. Subclinical Lesions of the Peripheral nervous System in Multiple Sclerosis Patients. Neurol. Neurochir. Pol., 2004; 38(4): 257-64.
7. Sarova-Pinhas I., Achiron A., Gilad R., et al. Peripheral Neuropathy in Multiple Sclerosis: A Clinical and Electrophysiological study. Acta Neurol. Scand., 1995; 91(4): 234-8.
8. Sharma K.R., Saadia D., Facca A.G., Chronic inflammatory demyelinating polyradiculoneuropathy associated with multiple sclerosis. J. Clin. Neuromusc. Dis., 2008; 9: 385-396.
9. Thomas P.K., Walker R.W.H., Rudge P., et al. Chronic Demyelinating Peripheral Neuropathy Associated with Multifocal Central Nervous System. Demyelination. Brain., 1987; 110: 53-76.
10. Zephir H., Stojkovic T., Latour P. et al. Relapsing Demyelinating Disease Affecting both the Central and Peripheral Nervous System. J. Neurol. Neurosurg. Psychiatry, 2008; 79: 1032-1039.

Vitalie Lisnic, M.D., Ph. D., Associate Professor
 Department of Neurology
 Nicolae Testemitanu State Medical and Pharmaceutical University
 2, Korolenko str, Chisinau MD-2028
 Republic of Moldova
 Tel.: 205102
 E-mail: vlisnic@yahoo.com

Receptionat 13.04.2009

Asigurarea hemostazei locale în chirurgia orală prin utilizarea trombinei umane la persoanele cu sindrom hemoragipar de diversă etiologie

O. Zănoagă

Catedra Chirurgie Oro-Maxilo-Facială, Stomatologie Ortopedică și Implantologie Orală
 Facultatea Perfecționarea Medicilor, USMF „Nicolae Testemițanu”

Maintenance of Local Haemostasis in Oral Surgery using Human Thrombin in Patients with Bleeding Disorders of Different Etiology

The author analysed the results at 67 patients hospitalized in the OMF Surgery Department of CNSPMU, Chisinau, between April, 2007 and February, 2009 who required treatment for oral bleeding. 53 patients suffered bleeding after tooth extraction, 9 gingival bleeding, and 5 bleeding after periostotomy. The study showed that human thrombin used as a haemostatic remedy is physiologically effective, inoffensive in treating bleeding of different etiologies, and that it avoids the deficiencies of classical methods of haemostasis.

Key words: bleeding, haemostasis, thrombin.

Обеспечение локального гемостаза в оральной хирургии с использованием человеческого тромбина у пациентов с геморрагическим синдромом разной этиологии

Исследование было основано на анализе результатов полученных в группе из 67 пациентов, госпитализированных в отделение ЧЛХ ННПЦУМ г. Кишинэу, в период апрель 2007 – февраль 2009. Эти пациенты обратились за медицинской помощью с жалобами на наличие кровотечения из ротовой полости. Из них у 53-х – кровотечение после зубного удаления, у 9-х – десневое кровотечение и у 5-х – кровотечение после периостомии. Было доказано, что использование человеческого тромбина с гемостатической целью является физиологическим, эффективным и безопасным методом остановки кровотечений разной этиологии, к тому же не обладает недостатками классического метода гемостаза.

Ключевые слова: геморрагия, гемостаз, тромбин.

Actualitatea temei

În cavitatea bucală se deosebesc hemoragii idiopatice și iatrogene [1]. Hemoragiile idiopatice apar spontan în cazul exulcerării tumorilor, a bolilor hemoragipare și în cadrul unor forme a parodontopatiilor, iar cele iatrogene – în urma intervențiilor chirurgicale.

De cele mai dese ori, în vederea acordării asistenței medicale specializate, se recurge la utilizarea măsurilor locale

de hemostază prin aplicarea suturilor, a tamponamentului compresiv supra- sau intraalveolar, electro- sau diatermo-coagularea țesuturilor sângerânde, aplicarea cristalelor de permanganat de caliu sau a preparatelor hemostatice [2]. Este demonstrat că, injectarea adrenalinei oferă doar un efect hemostatic temporar, iar utilizarea metodelor termice de hemostază provoacă o necroză tisulară și încetinesc considerabil procesele de vindecare [2]. Aplicarea suturilor provoacă