

Evaluation of Kidney Functioning among Patients with Vesicoureteral Reflux by Ultrasound Doppler Sonography

L. A. Zhanteliya, B. A. Kubeseitov

Research Center of Urology „B. U. Jarbussynov”
Department of Urology and Operative Nephrology
Kazakh National Medical University „S. D. Asfendiyarov”, Almaty, Kazakhstan

Abstract

The kidney, by virtue of its functional and anatomic peculiarities, serves as a good model for research of haemodynamics, which allows using ultrasound Doppler sonography (USDS) for defining the degree of damage of kidney parenchyma and control in dynamics. The extent of kidney damage among patients with vesicoureteral reflux (VCR) is in direct dependence from the degree of reflux, age of the patient, often recrudescence of pyelonephritis. One of the serious recrudescences of VCR among children is chronic pyelonephritis. That is why cicatrization of the kidney parenchyma, decreasing sizes of organs and decreasing function of kidneys under VCR is proportional to the duration and intensity of bacterial and inflammatory process. In this connection, the functional state of the kidney parenchyma is in the state of direct dependence from the state of urodynamics of the lower genital tracts (LGT), and it is possible that intravesical hypertension directly influences on kidneys' circulatory dynamics. There were 125 children examined with VCR between the ages of 5 to 15. Out of those 5 to 15 years old, there were 77 (61.6%), and there were 48 (38.4%) between the ages of 11 to 15. Ultrasound Doppler sonography of kidney haemodynamics vessels was performed step by step with empty, filled and void urinary bladder, which allowed finding out the influence of functional defects of LGT on the state of the kidney parenchyma among patients with VCR. Wide application of USDS in clinical practice with analysis of qualitative and quantitative parameters of the Doppler spectrum of the kidney haemodynamics among patients with VCR against a background of different hydrodynamic situations of the urinary bladder, indicate a deep damages of the kidney parenchyma and assist in adequate choice of terms for conservative treatment and justify timely application of surgical correction in order to eliminate progress of cicatricial-sclerotic damages of the kidney parenchyma.

Key words: kidney, renal haemodynamics, doppler sonography, vesicoureteral reflux.

Оценка функции почек у больных пузырно-мочеточниковым рефлюксом ультразвуковой доплерографией

Почка, в силу своих функциональных и анатомических особенностей, является прекрасной моделью для исследования гемодинамики, что позволяет использовать ультразвуковую доплерографию (УЗДГ) для определения степени поражения почечной паренхимы и контроль в динамике. Степень поражения почки у больных с пузырно-мочеточниковым рефлюксом (ПМР) находится в прямой зависимости от степени рефлюкса, возраста больного и частоты обострения пиелонефрита. Одним из серьезных осложнений ПМР у детей является хронический пиелонефрит. По изменению параметров УЗДГ можно судить о наличии патологических изменений в области изучаемого сосуда. В этой связи функциональное состояние почечной паренхимы зависит, прежде всего, от состояния уродинамики нижних мочевых путей (НМП) и вполне вероятным является тот факт, что внутрипузырная гипертензия оказывает непосредственное влияние на гемодинамику почки. Обследовано 125 детей с ПМР в возрасте от 5 до 15 лет. Из них в возрасте от 5 до 15 лет – 77 (61,6%), и в возрасте от 11 до 15 лет – 48 (38,4%). Ультразвуковую доплерографию почечной гемодинамики у больных с ПМР проводили поэтапно: при пустом, наполненном и опорожненном мочевом пузыре, что позволило нам выяснить влияние функциональных нарушений НМП на состояние почечной паренхимы. Широкое применение УЗДГ в клинической практике, с анализом качественных и количественных параметров доплеровского спектра гемодинамики почки у больных с ПМР, свидетельствует о глубоких поражениях почечной паренхимы и способствует адекватному выбору сроков консервативного лечения и позволяет обосновать своевременное проведение хирургической коррекции во избежание прогрессирования пузырно-склеротического поражения почечной паренхимы.

Ключевые слова: почки, почечная гемодинамика, доплерография, пузырно-мочеточниковый рефлюкс.

Introduction

The function of the kidney is mostly defined by the effectiveness of blood circulation in its vascular bed [5]. Disturbance of renal haemodynamics is possible as under complication of outflow of blood from organs as well as defects of its inflow [2, 9]. The kidney, by virtue of its functional and anatomic peculiarities, serves as a good model for research of haemodynamics, which allows using ultrasound Doppler sonography (USDS) for defining the degree of damage of kidney parenchyma and control in dynamics [10].

For the first time in 1965, Brouder described the roentgenologic picture of intrarenal reflux, which is developed as a result of intra-pelvis hypertension [9, 10, 11]. The extent of kidney damage among patients with vesicoureteral reflux

(VCR) is directly dependent on the degree of reflux, the age of the patient, and how often recrudescence of pyelonephritis occurred. One of the serious recrudescences of VCR among children is chronic pyelonephritis because cicatrization of the kidney parenchyma, decreasing sizes of organs and decreasing function of kidneys under VCR is proportional to the duration and intensity of the bacterial and inflammatory process [3, 4]. Using parameters of VCR it is possible to judge the presence of pathologic changes in area of the investigated vessels. Screening diagnostics of VCR allowed in 50% - 95% cases to precisely diagnose retrograde reflux of urine under II – IV degrees of reflux with appearance of ultrasound devices of high resolution, which are working in “real time” [1, 2, 5, 6, 7, 8].

In this connection, the functional state of the kidney parenchyma is in the state of direct dependence on the state of

Table 1

Distribution of patients with vesicoureteral reflux by the form of dysfunction of the urinary bladder and extend of damage

Form of urinary bladder dysfunction	Degree of vesicoureteral reflux							
	I (n = 25)		II (n = 37)		III (n = 58)		IV (n = 35)	
	abs.	%	abs.	%	abs.	%	abs.	%
Hyper-reflective unadapted	11	44	19	51.4	37	63.8	3	60
Hyper-reflective adapted	9	36	14	37.8	16	27.6	1	20
Hyper-reflective	5	20	4	10.8	5	8.6	1	20

urodynamics of the lower genital tracts (LGT) and it is possible that intravesical hypertension directly influences kidneys circulatory dynamics.

Material and Methods

In order to evaluate functional state of kidney parenchyma of reflux kidney depending on the age of the patient and the extent of VCR, we examined 125 children with VCR between the ages of 5 to 15 years. 77 (61.6%) of them were between the ages of 5 to 15, and 48 (38.4%) between the ages of 11 to 15. Distribution of patients by extent of VCR and the form of the dysfunction of the urinary bladder is presented in table 1.

During the investigation of urodynamics LGT, 56% patients had neurogenic dysfunction of the urinary bladder of the

of urinary bladder. The functional state of a urinary bladder was registered on a graphic curve. USDS of kidney vessels was performed step by step with empty, filled and void urinary bladder, which allowed finding out the influence of functional defects of LGT on the state of the kidney parenchyma among patients with VCR (fig. 1).

The state of the kidney haemodynamics was evaluated using the following criteria: maximum systolic speed of arterial bloodstream - V max, end-diastolic - V min and index of peripheral RI.

Results and discussion

Analysis of USDS data among 20% of patients with VCR of the 1st degree showed that with empty urinal bladder Doppler

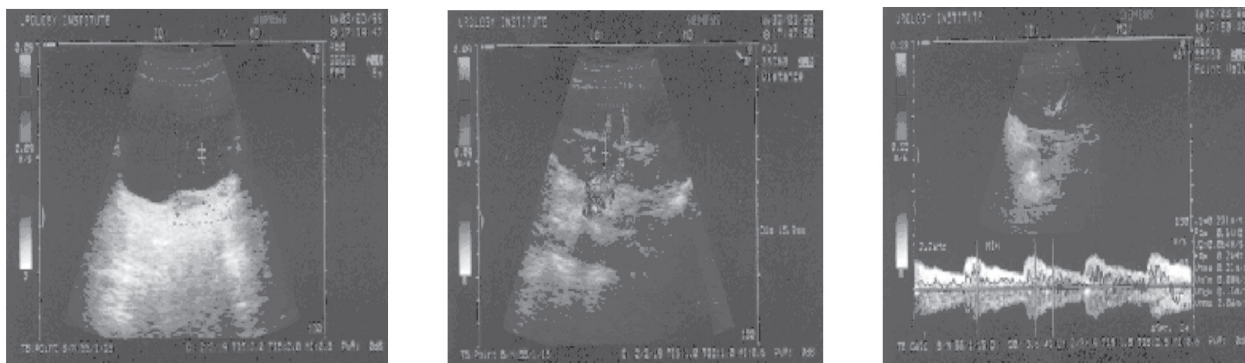


Fig. 1. Ultrasound of urinary bladder, vascular pedicle of the kidney and dopplerography curve.

hyper-reflective type, unadapted form, 32% had hyper-reflective adapted and 12% had hyporeflexive. In order to define influence of urodynamics defects of LGT on circulatory dynamics of kidney, we offered Method with a help of retrograde cystotometry and haemodynamics of kidney on USDS.

Method was completed the following way

Ultrasound Doppler sonography of kidney haemodynamics among patients with VCR was performed on the device SONOLINE "Versa Pro" "Seimans". In our investigations in a group of matching uro- and haemodynamic investigation children older than 5 years old were included. Taking into account constitutional peculiarities of the children organism USDS is possible from anterolateral as well as posterolateral approach. After preliminary urinary bladder emptying, the patient is put on a couch and two-way catheter is set, one of them was connected to a urodynamic device, the other one to a container with liquid for slow filling

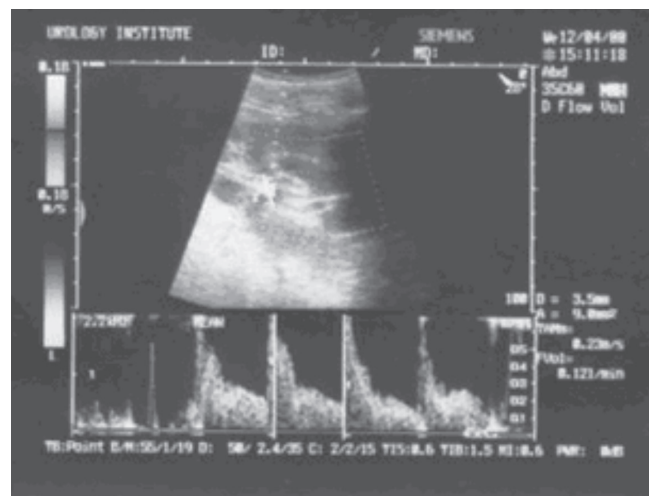


Fig. 2. Doppler curve under vesicoureteral reflux of the 1st degree.

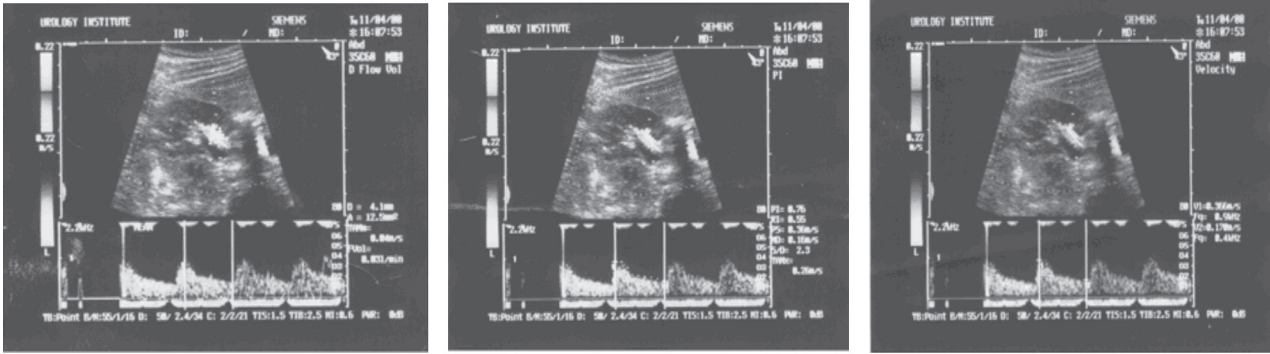


Fig. 3. Dopplerographic curve under vesicoureteral reflux of the 2nd degree.

curve has peaks of systolic and diastolic phase; however there is some flatness of diastolic component (fig. 2).

Doppler investigation performed among patients with VCR of the 1st degree indicates that on the level of unimpeded contraction of detrusor after slow filling of the urinal bladder the form of Doppler curve is rather flattened, though we observed a clear differentiation between systolic and diastolic phase, parameters of Vmax and Vmin are lowered, after urinary bladder emptying, linear parameters did not return to the initial condition. Indicators of RI among patients with 1st degree of VCR in a normal condition.

In this group of patients, during the time of the complex, stage by stage, symptomatic treatment directed on recovery of functional defects of the urinary bladder and chronic pyelonephritis taking into account evaluation of the functional state of the kidney parenchyma of the refluxing kidney, disappearance of the VCR degree among 7 patients was noted, and in 4 cases of observations the degree of reflux did not progress.

The combination of investigation of uro- and haemodynamics among 67 (21.27%) patients with VCR of the 2nd degree performed step by step under empty, filled and void urinary bladder showed, that in all three positions there is flattening of all peaks, and there is also the appearance of implicit additional peaks in phases of systole and diastole.

Acquired data indicates about deeper defects of the functional state of the kidney parenchyma appeared as a result of retrograde reflux of the urine aggravated by intravesical hypertension (fig. 3).

The combined investigation identified 46.4% of patients with VCR of the 3rd degree, that with an empty, filled and

void urinary bladder there are marked changes of forms in a Doppler curve, the systolic peak is sharply flattened, additional peaks appear before the diastolic phase. The diastolic component does not occur. The parameters of the Doppler spectrum, as systolic as well as diastolic component, are lowered, which sharply worsens on the height on the uninhibited involution of detrusor, and after voiding of the urinary bladder it does not return to the initial condition. Indicators of RI among patients in three levels indicate insignificant increase (fig. 4).

Acquired data of the combined investigation performed under different hydrodynamic situations among patients with VCR of the 3rd degree indicate significant damages of the kidney parenchyma due to long existence pyelonephritic process in reflux kidney, as inflammatory process assists in increasing impedance in kidney vessels and decreasing the bloodstream speed. Indicators of peripheral resistance among patients with VCR of the 3rd degree is increased. Acquired data of the Doppler investigation is on the same level with other methods allowed to provide rationale for performing surgical correction, among 8 patients with VCR of the 3rd degree observed during 1.5 years.

Doppler investigation of haemodynamics of the kidney among 4 % of the patients with 5th degree of VCR performed stage by stage in three positions show that the Doppler curve is flattened and compressed, decreased differentiation between systolic and diastolic phases is absent, and parameters V max and V min are sharply decreased. Sharp suppression of indicators arises on the height of unimpeded contraction of detrusor and does not return to the initial position after voiding of the urinary bladder. Acquired data indicates about

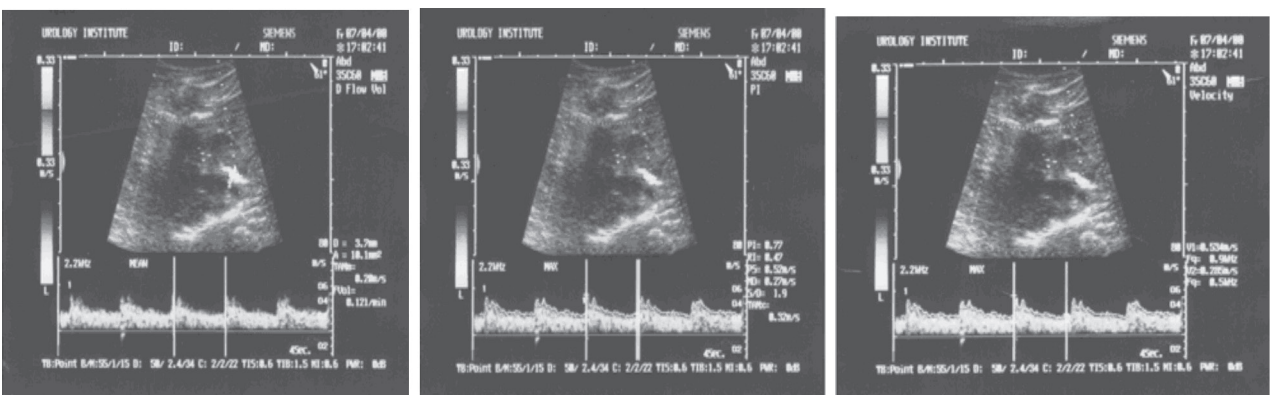

Fig. 4. Dopplerography curve under vesicoureteral reflux of the 3rd degree.

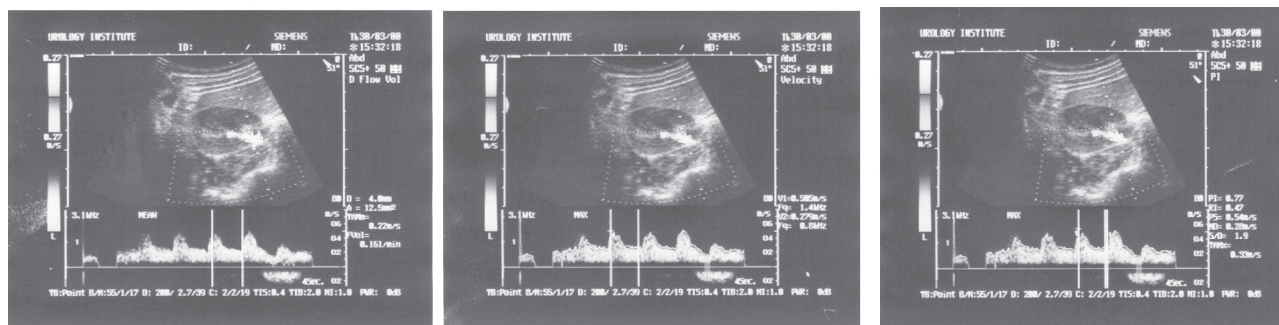


Fig. 5. Dopplerography curve under vesicoureteral reflux of the 4th degree.

deterioration of reserve abilities of the kidney parenchyma as a result of frank cicatricial-sclerotic process. Indicators of peripheral resistance among patients with IV degree of VCR is increased. Acquired data of the combined investigation of haemo- and urodynamics allowed analysis of the evidence for the organ removal operation (fig. 5).

Characteristic of Doppler investigation of the kidney haemodynamics by systolic and diastolic component is present among 125 patients with I – IV degree of VCR is presented in tab. 2 and 3.

Table 2

Characteristics of Doppler spectrum among patients with vesicoureteral reflux

Degree of vesicoureteral reflux		
I (n = 25)	0.505–0.376	0.276–0.177
II (n = 37)	0.459–0.366	0.221–0.170
III (n = 58)	0.376–0.208	0.265–0.170
IV (n = 35)	0.229–0.175	0.078–0.098

Table 3

Indicators of RI with different degrees of vesicoureteral reflux (n = 125)

Localization of kidney vessels	Degree of vesicoureteral reflux			
	I (n = 25)	II (n = 37)	III (n = 58)	IV (n = 35)
Renal artery	0.65	0.70	0.75	0.75
Segmental arteries	0.65	0.75	0.75	0.75
Sub-segmental arteries	0.60	0.70	0.69	0.65

Conclusion

Wide application of USDS in clinical practice with analysis of qualitative and quantitative parameters of the Doppler spectrum of the kidney haemodynamics among patients with VCR against a background of different hydrodynamic situations of the urinary bladder, indicate a deep damages of the kidney parenchyma especially among patients with 2nd – 4th degree of disease and assist in adequate choice of terms for conservative

treatment and justify timely application of surgical correction in order to eliminate progress of cicatricial-sclerotic damages of the kidney parenchyma.

References

1. Bosin VU, Vatolin KV, Nechvolodova OL, et al. Radiologic diagnosis in pediatry. M.: Medicine. 1988;81–84.
2. Vladimirova NN, Yanenko EK, Komarova VA, et al. Central and renal haemodynamics among urological patients. *Urology*. 1999;5:40–44.
3. Dzhavad-Zade MD, Derzhavin VM. Neurogenic dysfunction of the urinary bladder. Moscow: Medicine. 1989;357.
4. Zorkin SN. Vesicoureteral reflux among children. *Medical scientific and educational-methodic magazine*. 2002;3:29–44.
5. Zorkin SN. Risk factors of nephrosclerosis development among children with vesicoureteral reflux. *Medical scientific and educational-methodic magazine*. 2002;7:3–12.
6. Lopatkin NA, Morozov AB, Zhitnikova LN. Stenosis of renal vein. M.: Medicine. 1984.
7. Materials of the 2nd congress of Association of specialists on ultrasonic diagnostics in a medicine, 27 – 30 June, Moscow. 1995;108.
8. Erman MV, Marculevich OI. Ultrasonic investigation of the urinary system among children. SPb.: Piter. 2000;160.
9. Hodson CJ, Mating T, McManmon T. The pathogenesis of reflux nephropathy (Chronic atrophic pyelonephritis). *Brit. J. Radiology*. 1975;48(Suppl 3):13–32.
10. Halpern EJ, Deane CR, Needleman L, et al. Normal renal artery spectral. Doppler waveform: a closer look. *Radiol*. 1995;196(3):667–673.
11. Hibbert J, Howlett DC, Greenwood KL, et al. The ultrasound appearances of neonatal renal vein thrombosis. *Br. J. Radiol*. 1997;70(839):1191–1194.
12. Olbig H, Claesson I, Ebel K, et al. Renal scars and parenchyma thinning in children with vesicoureteral reflux: a 5 years report of the International Reflux Study in Children (European branch). *J. of Urology*. 1992;148(5):1653–1656.
13. Ransley P, Risdon R. Reflux and renal scarring. *Brit. J. Radiology*. 1978;14(3):11–16.

Corresponding author

Liazat Asanovna Zhantelieva, Ph.D., M.D., Assistant Professor
 Research Center of Urology „B. U. Jarbusynov”
 Department of Urology and Operative Nephrology
 Kazakh National Medical University „S. D. Asfendiyarov”
 88, Tole-Bi Street, Almaty 050012
 Kazakhstan
 Tel.: 2783311
 E-mail: zhantelieva@gmail.com

Manuscript received March 31, 2010; revised manuscript June 05, 2010