

Duplex ultrasonography in evaluation of complications of portal hypertension in liver cirrhosis

*C. Tambala¹, L. Spinei²

¹Department of Radiology and Imaging, ²School of Public Health
Nicolae Testemitsanu State University of Medicine and Pharmacy, Chisinau, the Republic of Moldova

* Corresponding author: caroli@bk.ru. Manuscript received July 01, 2015; accepted September 03, 2015

Abstract

Background: Portal hypertension is a serious complication in liver cirrhosis and it is responsible for most of the deaths at patients with the respective disease. Determination of the pressure gradient by the catheterisation of hepatic veins is a laborious method and often associated with complications. There are necessary accessible methods to evaluate portal hypertension with an acceptable degree of confidence. This study aims to determine Doppler hemodynamic indicators with important predictable goal in case of complications of the portal hypertension associated with liver cirrhosis.

Material and methods: The study group included 111 patients diagnosed clinically, biologically and imagining with liver cirrhosis. The cytolytic, cholestatic, hepatoprive syndromes and the gravity of hypersplenism were evaluated. Esophageal varices were identified by upper endoscopy. The hepatic morphology, including the personalisation of the vascular tree, was evaluated by conventional and duplex ultrasonography.

Results: The increase of the vascular resistance at the level of lienal artery ($r = 0.454$), and the Splenoportal Index had an important correlation with the severity of the Splenomegalic Syndrome ($r = 0.516$). The prediction of the esophageal varices with high risk for haemorrhage was set at the value of 7-10 cm/sec of the time-weighted average velocity measured in the hepatic portal vein (RP+3.13). Ascites and portal thrombosis were more frequent at an index of the portal hypertension of (IHTP) >2.1 (RP+3.5).

Conclusions: Evaluation of the hemodynamic indicators by duplex ultrasonography allowed to highlight the predictive parameters in case of complications of the portal hypertension associated with liver cirrhosis.

Key words: liver cirrhosis, hemodynamic indicators, esophageal varices, duplex ultrasonography.

Introduction

The portal hypertension associated with liver cirrhosis is a clinical hemodynamic syndrome, defined by increased gradient of portal venous pressure above 5 mm/Hg [1,2,4]. The clinical description of this syndrome includes the presence of esophageal varices and bleedings from them, ascites, spontaneous bacterial peritonitis and hepatorenal syndrome, which also are the main causes of death or indications for a liver transplantation at patients with liver cirrhosis [6,11]. The development of the liver cirrhosis gradually leads to increase of the portal pressure and to depression of the hepatic function, which often are associated with major complications in stages of decompensation [8,9,17].

Variceal haemorrhage significantly reduces the survival rate in cirrhotic patients both by consequences of the haemorrhagic shock and by hepatic impairment, thus resulting in polyorganic insufficiency [6,7,10,14,15]. Severe circulatory deficiencies in hepatic circulation, caused by advanced morphological changes, as a result create premises for thrombosis at different levels on the splenoportal axis which alter even more the hepatic function [11,12,16].

At present, ascites continues to be another important problem in the behaviour of patient with liver cirrhosis. The prospect of a successful treatment is when the ascetic syndrome occurred reduces. Complicated hemodynamic changes, which inevitably occur, lead to the irreversible challenged hepatic function [3,4,9,11].

The splenomegaly associated with severe hypersplenism continues to be subject for controversial discussions in aim to correct the haematological disorders, which occur within this syndrome present in the cirrhenous portal hypertension.

Duplex ultrasonography is an accessible, non-radiating imaging method, with an acceptable accuracy as to morphologically evaluate the liver and provides important data regarding the disorders of vascular flow in the hepatolienal system [3,5,13].

The study's goal is to estimate the importance of hemodynamic parameters assessed through the duplex ultrasonography, as well as the connection with the complications associated with the cirrhenous portal hypertension and the determination of vecilometry indicators with predictable importance in order to earlier discover the respective complications.

Material and methods

In 2012-2014, the Hepatology Department of the Clinical Republican University Hospital studied 111 patients diagnosed with cirrhosis of the liver with various aetiologies (mainly of viral origin 97.8%). The average age of selected patients was of 48.4±1.66 years old. From the viewpoint of sex distribution, men 46 (41.0%), women - 65 (59.0%).

The patients had an enhanced clinical and biological evaluation. The cytolytic, cholestatic, hepatoprive syndromes were assessed. Depending on the severity of cytopenia, the hypersplenism was divided into 3 degrees (mild, moderate, and severe). The esophageal varices were diagnosed by upper

endoscopy. According to Shertsinger, they were classified as absent or present, and the severity of varices described in degrees. The evaluation of severity of hemodynamic disorders was studied by duplex ultrasonography, which included the features of the arterial and venous flows in the hepatolienal basin, by assessing the indices of impedance, congestion (CI), spleno-portal (SPI), vascular portal (PVI), portal hypertension index (IPH). According to N. Anghelescu the quantification of the severity of portal hypertension (PH) was assessed in correlation to the PH hemodynamic classification into: stage I- splenomegaly (SPL) with or without hypersplenism (HPL), stage IIA- SPL+HPL+VE (esophageal varices), stage IIB- SPL+HPL+VE+gastrointestinal bleeding (HD) - 1 episode, stage IIIA- SPL+HPL+VE+ HD+reducible ascites, stage IIIB- - SPL+HPL+VE+ HD+irreducible ascites, precoma, hepatic encephalopathy .

The data analysis was carried out by using Excel Microsoft Office 2003 and EpiInfo 7.1. programme, based on their functions and modules. When statistically processing, a set of operations was used, by making specific procedures and techniques: estimation of parameters and hypothesis testing was performed by calculating errors using Student t-test of significance and the materiality threshold "p", to highlight the connection between two characteristics correlation coefficient was calculated. In the analysis of applied diagnostic tests there were used Se (sensitivity), Sp (specificity), positive and negative predictive values.

Results and discussions

After a complex examination based on laboratory and endoscopic investigations of patients included in the study, we found that the hypersplenism syndrome was recorded in most cases with the following distribution: mild 10 (9.0%) cases, moderate 25 (22.5%), severe 35 (31.5%) cases, no syndrome noted in 25 (22.5%) cases. The degree of esophageal varices, set by upper endoscopy, was distributed as follows: grade I - 35 cases (31.5%), grade II - 24 (21.6%), grade III - 13 (11.7%); no one in 32 cases (28.8%). No esophageal varices were found in 3 patients (2.7%) due to previously made endoscopic endoligature. Pursuant to PH hemodynamic classification, the patients were divided by stages: I- 25 (22.5%), IIA- 39 (35.1%), IIB- 11 (9.9%), IIIA- 16 (14.4%), IIIB- 4 cases (3.6%).

The duplex ultrasonography showed the morphological aspect of the liver, severity of splenomegaly, presence of portosystemic collaterals. The hepatolienal circuit was assessed both on venous side: hepatic portal vein, splenic vein, as well as on the arterial one: hepatic artery, lienal artery. The study included velocimetry indicators, blood flow rate, pulsatility and resistance indicators. The indicators used to estimate the portal hypertension were: congestion indicator, splenoportal indicator, vascular portal indicator, portal hypertension indicator. The ascetic syndrome was noted in 25 cases (22.5%), no syndrome in 86 cases (77.5%), with distribution per grade: grade 1-11 (9.9%), grade 2- 10 (9%), grade 3 - respectively 4 cases (3.6%). Within the study, thrombotic complications were also observed in 11 cases (11.8%). Out of these, full thrombosis

was found in a single case (0.9%), partial thrombosis in 8 cases (7.2%), post-thrombotic changes 2 (1.8%). By assessing more quantitative indicators used by duplex ultrasonography, we have set those with more important correlation depending on the size of esophageal varices. Thus, the resistance indicator (RI) at the level of lienal artery had a correlation coefficient of $r=0.412$ ($p<0.01$), whereas the relevance of spleen dimensions increased once the degree of variceal severity increased $r=0.399$ ($p<0.05$). The relevance of time-weighted average velocity (TWAV) in the hepatic portal vein ($r = -0.377$, $p<0.05$) diminished once the varices grew in diameter.

Within the study, we noted a significant statistical correlation of the timely-weighted average speed in the hepatic portal vein, congestion indicator ($r=0.316$, $p<0.05$), splenoportal indicator ($r=0.409$, $p<0.01$), and vascular portal one ($r=-0.293$, $p<0.05$), portal hypertension indicator ($r=0.397$, $p<0.05$) depending on the variceal dimensions (tab. 1).

Thus, we found a significant difference in indicators used once, the level of esophageal varices advanced. It is well known that the varices' dimensions represent a major risk factor for

upper gastrointestinal haemorrhage. During the research, we have analysed the forecast of variceal levels depending on TWAV in the hepatic portal vein. Thus, we have set the important predictable indicators in order to forecast esophageal varices of grade III, the relevance of which increases once the speed in the hepatic portal vein gradually diminishes (tab. 2).

By analysing the correlation between the Doppler indicators and presence of the ascetic syndrome, we have set that a value under 2.1 of IPH ascites is more rarely noted compared to patients with ascites of different degrees with an IPH over 2.1 ($r=0.468$, $p<0.01$) (tab.3). The vascular portal indicator decreased proportionally with the increase of the volume of ascetic fluid ($r=-0.472$, $p<0.01$).

Thrombosis in the portal system is one of the vascular complications which progressively disturb the hemodynamic already compromised within the cirrhosis of the liver. Analysing in whole a string of vascular parameters, there was found a significant statistical difference of PVI and IPH depending on the presence of thrombotic modifications in the venous system ($p<0.001$). Thus, the respective indicators represent an acceptable forecast for thrombotic complications (tab. 4).

Table 1

Hemodynamic indicators depending on staging of esophageal varices

Indicators	Absent	Grade I	Grade II	Grade III	P Abs-II P Abs-III P I-III
TWAV (cm/sec)	14.2±0.30	13.8±0.41	12.5±0.54	11.7±0.44	<0.01 <0.001 <0.001
CI	0.09±0.001	0.11±0.001	0.14±0.01	0.12±0.01	<0.001 <0.01 >0.05
SPI (%)	0.47±0.02	0.49±0.02	0.57±0.03	0.62±0.02	<0.01 <.001 <0.001
PVI	10.0±0.35	10.6±0.50	8.4±0.53	8.2±0.48	<0.05 <0.01 <0.001
IPH	1.9±0.07	2.0±0.12	2.4±0.15	2.5±0.15	<0.01 <0.001 <0.01

Table 2

Forecasts of big esophageal varices depending on the TWAV variations in hepatic portal vein

TWAV (cm/sec)	Se(%)	Sp(%)	PPV(%)	NPV(%)	LR+	LR-
7-10	75	76	80	96	3.13	0.33
11-14	44	82	70	61	2.44	0.68
15-18	0	50	0	43	0	2.0

Legend: Se – sensitivity, Sp – specificity, PPV - positive predictive value , NPV - negative.

Table 3

Indicator of portal hypertension in forecasting ascites

Parameters	Se%	Sp%	PPV%	NPV%	LR+	LR-
Coefficient IPH>2.1	88	80	58	96	4.4	0.15

Table 4

Forecasts for thrombosis by assessing hemodynamic parameters (PVI, IPH)

Parameters	Se%	Sp%	PPV%	NPV%	LR+	LR-
PVI <9.6	91	60	22	98	2.2	0.15
IPH >2.1	91	74	30	98	3.5	0.12

Table 5

Hypersplenism depending on the flow in the lienal artery

Parameter	Se%	Sp%	PPV%	NPV%	LR+	LR-
Pathological flow in lienal artery	79	69	87	54	2.5	0.3

During the study, we were set to also establish the predictable values in order to forecast the hypersplenism syndrome based on assessed hemodynamic parameters. Thus, it was observed a significant correlation of the splenoportal index with degrees of severity of hypersplenism ($r=0.516, p<0.01$). Also, the impedance index increased at the level of lienal artery positively correlates with the presence of hypersplenism ($r=0.454, p<0.01$). This allowed us to calculate the forecasts indexes for this syndrome too (tab. 5).

The cirrhosis of the liver represents the final stage of most congestive hepatopathies, including in evolution of liver fibrosis, and is described by chronic cellular destruction. The irreversible structural changes lead to deterioration of the hepatic function and progressive changes of blood flow. The portal hypertension is a precocious consequence and a more important one in evolution of complications of liver cirrhosis. The gradual blood flow disorders lead to the opening of other draining pathways, one of them being the gastroesophageal reflux [10]. Advanced varices are important predictors of bleedings. The gotten results allow us to forecast the occurrence of big-sized varices, once the average speed in the hepatic portal vein gradually diminished (RP+3.13). The venous congestion in the portal splenopathy was observed by the increase of the splenoportal index simultaneously with the advancing of the hypersplenism syndrome ($r = 0.516, p<0.01$). The increase of vascular resistance at the level of lienal artery is directly

related to the advance of severity of hypersplenism Se 79%, and Sp 69%, which represent acceptable values for forecasting this complication. In order to highlight more complexly the blood flow disturbances in cirrhosis of the liver, which include the affection at venous level, as well as at arterial level, we were set to make an evaluation of the vascular portal index and portal hypertension index when forecasting ascites and venous thrombosis. Thus, we found that at a value of over 2.1 of IPH, RP+ in order to forecast ascites is of 4.4 higher than value below 2,1. The thrombotic complications were mainly noted in patients who had an PVI<9.6 (RP+ 2.2), and IPH>2.1 (RP+3.5), which allowed us to make a satisfactory forecast for these complications too. During this study was obtained ROC curves for IPH > 2.1 for predicting ascites and thrombotic complications, this way the area under the curve (AUC) for predicting ascites is 0.823, and for predicting thrombosis, this index had AUC of 0.808. The pathological flow on lien artery has the area under the curve of 0.678, which shows acceptable accuracy in the prognosis of this syndrome (fig.1).

Conclusions

1. Duplex ultrasonography is a modern and accessible imaging method, which allows complex assessment of severity of circulatory disorders in the portal hypertension associated with cirrhosis of the liver.

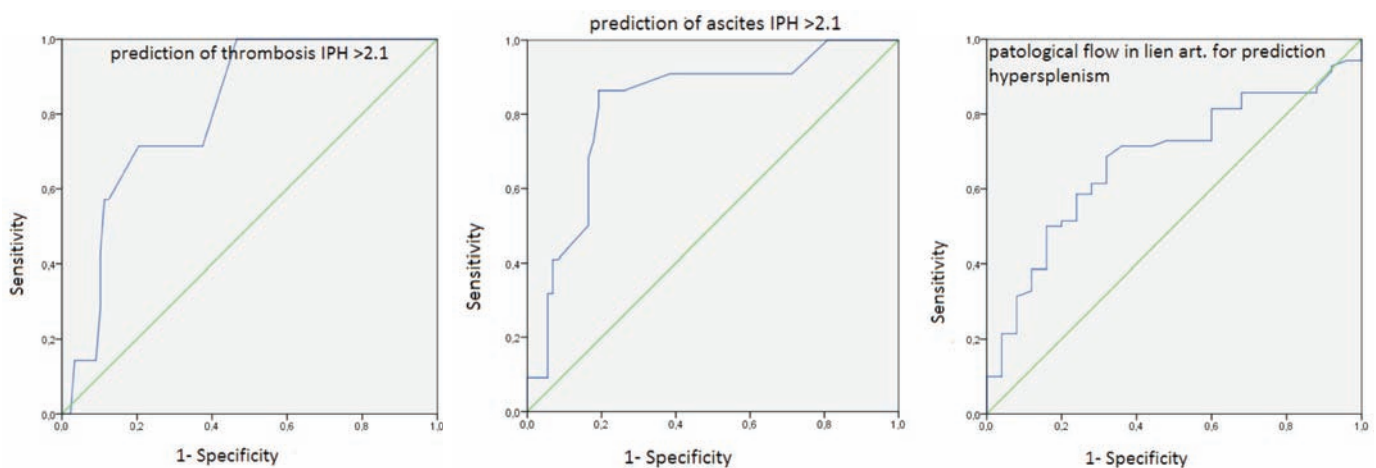


Fig. 1. ROC curves for predicting cirrhotic complications.

- Average speed in the hepatic portal vein is an important predictable indicator for big-sized variceal swellings with high risk of bleedings.
- Complex examination of hepatolienal circulation and estimation of vascular portal index, portal hypertension index provides an accurate forecast of important complications in cirrhosis of the liver, which allows an appropriate curative management.

References

- Berzigotti A, Piscaglia F. Ultrasound in Portal Hypertension. *Ultraschal In Med.* 2011;32:548-571.
- Berzigotti A, Piscaglia F. EFSUMB Education and Professional Standards Committee Ultrasound in Portal Hypertension. *Ultraschal In Med.* 2012;33:8-32.
- Berzigotti A, Reverter E, García-Criado A, et al. Reliability of the estimation of total hepatic blood flow by Doppler ultrasound in patients with cirrhotic portal hypertension. *J Hepatol.* 2013;59(4):717-222.
- Berzigotti A, Seijo S, Reverter E, et al. Assessing portal hypertension in liver diseases. *Expert Rev Gastroenterol Hepatol.* 2013;7(2):141-155.
- Berzigotti A, Ashkenazi E, Reverter E, et al. Non-invasive diagnostic and prognostic evaluation of liver cirrhosis and portal hypertension. *Dis Markers.* 2011;31(3):129-138.
- Biecker E. Portal hypertension and gastrointestinal bleeding: diagnosis, prevention and management. *World J Gastroenterol.* 2013;19(31):5035-5050.
- Feng-Hua Li, Jing Hao, Jian-Guo Xia, et al. Hemodynamic analysis of esophageal varices in patients with liver cirrhosis using color Doppler ultrasound. *J Gastroenter.* 2005;11(29):4560-4565.
- Hotineanu V, Cazacov V, Țămbală C, et al. Importanța metodelor imagistice moderne în diagnosticul hipertensiunii portale și splenopatiei portale hipertensive cirogene. *Arta Medica.* 2010;42(3):37-39.
- Mittal P, Gupta R, Mittal G, et al. Association between portal vein color Doppler findings and the severity of disease in cirrhotic patients with portal hypertension. *Iran J Radio.* 2011;8(4):211-217.
- Mohammad K Tarzamni, Mohammad H Somi, Sara Farhang, et al. Portal hemodynamics as predictors of high risk esophageal varices in cirrhotic patients. *World J Gastroenterol.* 2008;14(12):1898-1902
- Nusrat S, Khan MS, Fazili J, et al. Cirrhosis and its complications: evidence based treatment. *World J Gastroenterol.* 2014;20(18):5442-5460.
- Parikh S, Shah R, Kapoor P. Portal vein thrombosis. *Am J Med.* 2010;123(2):111-119.
- Procopeț B, Tantau M, Bureau C. Are there any alternative methods to hepatic venous pressure gradient in portal hypertension assessment? *J Gastrointestin Liver.* 2013;22(1):73-78.
- Subathra Adithan. Color Doppler evaluation of left gastric vein hemodynamics in cirrhosis with portal hypertension and its correlation with esophageal varices and variceal bleeding. *Indian J Radiol Imaging.* 2010;20(4):289-293.